



Intracolonic Migration of an Abdominal Drain through an Appendiceal Fistula: A Rare Post-Appendectomy Complication Managed Conservatively

**Cristina Davó Pérez ^{a*}, Virginia Pellicer Sánchez ^a,
Edelmira Soliveres ^a, Julio Sánchez Corral ^a,
Carolina Curtis Martínez ^a
and Miguel Ángel Morcillo Rodenas ^a**

^a *General and Digestive Surgery Department, Hospital Vega Baja, Orihuela (Alicante), Spain.*

Authors' contributions

This work was carried out in collaboration among all authors. All authors read and approved the final manuscript.

Article Information

Open Peer Review History:

This journal follows the Advanced Open Peer Review policy. Identity of the Reviewers, Editor(s) and additional Reviewers, peer review comments, different versions of the manuscript, comments of the editors, etc are available here: <https://www.sdiarticle5.com/review-history/118310>

Case Report

Received: 09/04/2024

Accepted: 13/06/2024

Published: 17/06/2024

ABSTRACT

In patients with appendiceal fistula undergoing conservative management, the main complication is inadequate or incomplete drainage of the fistula, which often leads to the consideration of more aggressive measures. We describe an extremely rare complication with an abdominal drain: intracolonic migration through appendiceal fistula. No such cases have been described in the literature. Our aim is to describe our experience and the therapeutic approach adopted to offer a less invasive treatment alternative, avoiding major surgeries, with good results.

*Corresponding author: E-mail: cristinadavoperez@gmail.com;

Cite as: Pérez, Cristina Davó, Virginia Pellicer Sánchez, Edelmira Soliveres, Julio Sánchez Corral, Carolina Curtis Martínez, and Miguel Ángel Morcillo Rodenas. 2024. "Intracolonic Migration of an Abdominal Drain through an Appendiceal Fistula: A Rare Post-Appendectomy Complication Managed Conservatively". *Asian Journal of Research in Surgery* 7 (2):150-53. <https://journalajrs.com/index.php/AJRS/article/view/205>.

Keywords: Fecal fistula; appendectomy; vacuum-assisted closure; Blumberg sign.

1. INTRODUCTION

A fecal fistula is a rare complication following an appendectomy. It occurs more frequently in patients with compromised base of the appendix due to advanced inflammatory processes such as an appendiceal mass or gangrenous appendicitis, with an incidence of less than 1% [1,2].

Therapeutic options may vary depending on the cause of the appendectomy: benign or malignant [3]. Conservative management with drainage and antibiotics has been described with high success rate in the absence of conditions that perpetuate the fistula (not high fistula output (<500 cc/day), absence of tumors, foreign bodies, distal obstruction, or infectious environment) [4,5,6]. The optimal drainage ensures epithelialization of the tract, which allows the closure of the fistula [6] and avoid more aggressive reinterventions. [7,8,9,10] The rarity of the complication and the successful non surgical management offers insights for similar situations.

Other techniques such as VAC (Vacuum-Assisted Closure), fibrin glue injection, or clip placement via colonoscopy have shown satisfactory results for other type of fistulae [7,11]. Also, prevention could be possible through the placement of a cecostomy in patients with severe periappendicitis.

Presentation of a case and a literature search on PubMed with the terms: post-appendectomy fecal fistula.

2. CASE PRESENTATION

A 48-year-old male diabetic patient presented with a 3-day history of right iliac fossa abdominal pain associated with fever. Physical examination revealed a mass in the right iliac fossa with localized pain and a positive Blumberg sign.

Blood tests showed a CRP of 23.65 mg/dL and leukocytosis of $18.22 \cdot 10^9/L$. The diagnosis was confirmed by ultrasound, which showed a tubular structure with thickened walls and increased diameter associated with inflammatory changes, without free abdominal fluid, compatible with

acute appendicitis. Laparoscopic appendectomy was performed, revealing a gangrenous appendix with an appendiceal inflammatory mass. There were no immediate postoperative incidents, and the patient was discharged on the 2nd day with outpatient antibiotic therapy. A week later, he returned with predominant right iliac fossa abdominal pain associated with a low-grade fever. CRP was 8.70 mg/dL and leukocytosis was $16.10 \cdot 10^9/L$. A CT scan showed multiple postoperative collections. Antibiotic therapy was initiated, and laparoscopic drainage was performed without obtaining fecal material. A drain was left in the right iliac fossa. The patient completed a prolonged antibiotic regimen and was discharged with the drain and follow-up every 2-3 days. A week later, he reported fecal output through the drain without associated symptoms, no CRP elevation, or leukocytosis. Imaging tests showed the drain was well-positioned, without intra-abdominal collections.

3. DISCUSSION

Given the appendiceal stump fistula, a conservative approach was decided until closure, but fecal output increased. A CT scan showed the drain in the colon (Fig. 1). Since the patient was asymptomatic, tolerating a diet, and had normal transit and lab parameters, a conservative approach was proposed.

The drain was clamped for 72 hours to monitor clinical evolution. Due to adequate tolerance, the drain was cut almost at skin level and sealed with a silk transfixing suture. The patient remained hospitalized under clinical observation, with analytical follow-up and radiological control. In the following days, the patient maintained oral tolerance and intestinal transit. Abdominal X-rays showed progressive advancement of the drain (Fig. 2). Finally, he expelled the entire drain via the anus during defecation. No case reports of managing fecal fistulas involving invaginated abdominal drains were found in the literature. The patient was informed about the diagnosis and the procedure to evacuate the drainage tube, as well as the potential risks. Furthermore, he was informed about the interest of the management of the case for the scientific community, consenting to its sharing and publication.

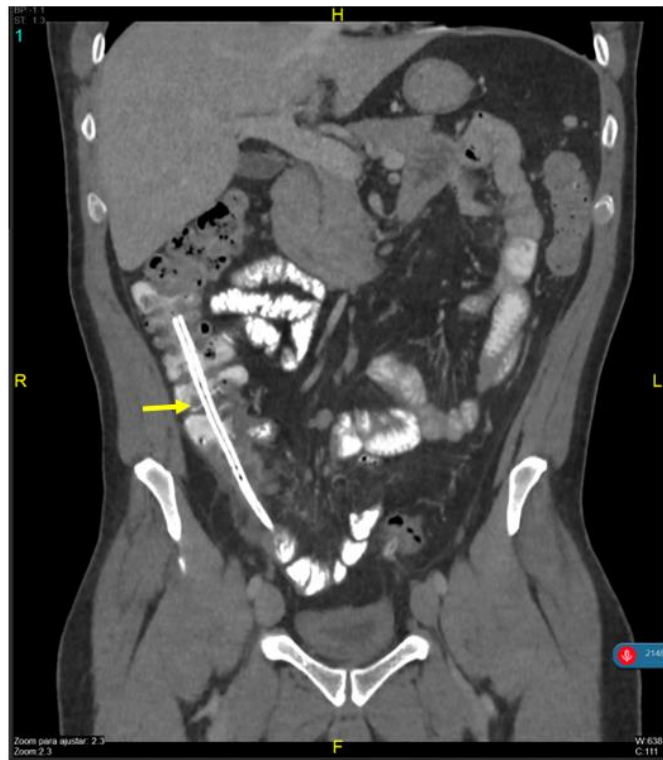


Fig. 1. CT report 1

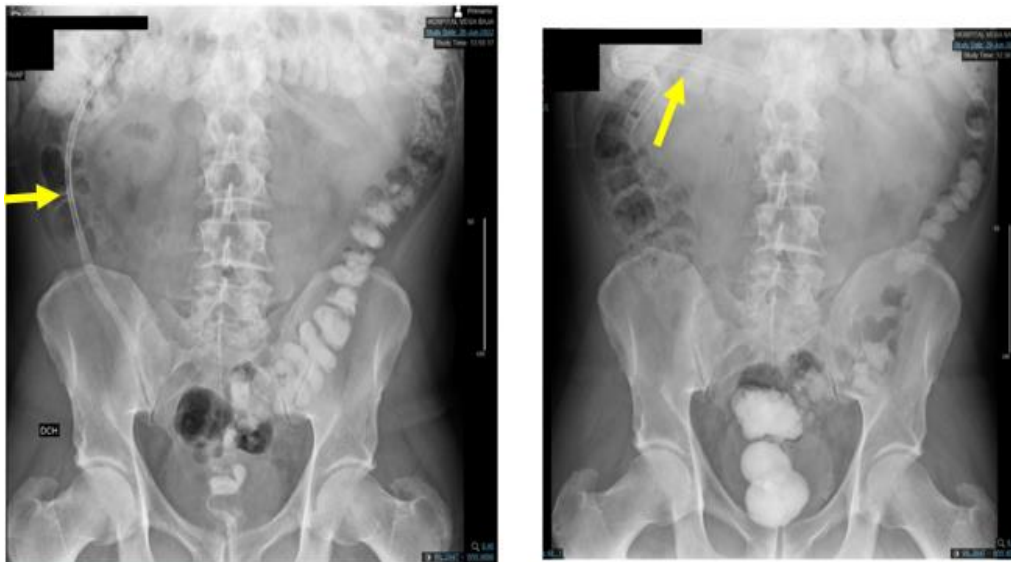


Fig. 2 Xray report 2

4. CONCLUSION

Post-appendectomy fecal fistula is a rare condition with significant morbidity. Conservative management has been described, although not involving the migration of a drain tube. In clinically stable patients with intracolonic

migration of the drain and adequately collected fistulous output, major surgery can be avoided.

DISCLAIMER (ARTIFICIAL INTELLIGENCE)

Author(s) hereby declare that NO generative AI technologies such as Large Language Models

(ChatGPT, COPILOT, etc) and text-to-image generators have been used during writing or editing of manuscripts.

CONSENT

As per international standards or university standards, patient(s) written consent has been collected and preserved by the author(s).

ETHICAL APPROVAL

It is not applicable.

COMPETING INTERESTS

Authors have declared that no competing interests exist.

REFERENCES

1. Mohamed AA, Mahran KM. Laparoscopic appendectomy in complicated appendicitis: Is it safe?. *Journal of minimal access surgery*. 2013;9(2):55–58. Available: <https://doi.org/10.4103/0972-9941.110963>
2. Flores-Marín K, Rodríguez-Parra A, Trejo-Ávila M, et al. Laparoscopic appendectomy in complicated appendicitis with compromised appendix base: a retrospective cohort study. *Cirugía y cirujanos*. 2021;89(5):651–656. Available: <https://doi.org/10.24875/CIRU.200009051>
3. Nakamoto H, Yokota R, Namba H, Ishikawa T, Yamada K, Hosoda M, Taguchi K. A Benign Appendiceal-Colonic Fistula, Diagnosed and Managed Laparoscopically: A Case Report. *The American journal of case reports*. 2020; 21:e925946. Available: <https://doi.org/10.12659/AJCR.925946>
4. Deaver JB. Appendiceal fecal fistula. *Annals of surgery*. 1924;80(1):56–57. Available: <https://doi.org/10.1097/00000658-192407000-00007>
5. Genier F, Plattner V, Letessier E, Armstrong O, Heloury Y, Le Neel JC. Fistules caecales post-appendectomies. A propos de vingt-deux cas [Post-appendectomy fistulas of the cecum. Apropos of 22 cases]. *Journal de chirurgie*. 1995;132(10):393–398.
6. Blackbourne LH. *Surgical Recall, Recall series editor and senior editor*. San Antonio, Texas. Lippincott Williams & Wilkins, a Wolters Kluwer business. 6th edition; 2012.
7. Mohamed A. Faecal fistula, the most unfortunate sequelae of appendectomy. *Case report. The Internet Journal of Surgery*. 2011;27(2):1–4. DOI: 10.5580/2418.
8. McCrystal S, Kong J, Gourlas P, Morris B, Lutton N. Appendicorectal fistula with a novel solution: First case report and review of the literature. *Clinical case reports*. 2019;7(10):1885–1889. Available: <https://doi.org/10.1002/ccr3.2380>
9. Shehu H, Shehu M. Acquired Rectovaginal Fistula and Faecal Incontinence Following Sexual Assault in a 4-Year-Old Girl". *International Journal of Medical and Pharmaceutical Case Reports*. 2022;15(2):12-15. Available: <https://doi.org/10.9734/ijmpcr/2022/v15i230153>.
10. Mueller MH, Geis M, Glatzle J, Kasperek M, Meile T, Jehle EC, Kreis ME, Zittel TT. Risk of fecal diversion in complicated perianal Crohn's disease. *Journal of Gastrointestinal Surgery*. 2007;11(4):529-37.
11. Olayode, Adegboyega MBBS; Kizer, Robert MD. Fibrin Glue Treatment of Enterocutaneous Fistula in Crohn's Disease: 1290. *American Journal of Gastroenterology*. 2012;107(): S512.

© Copyright (2024): Author(s). The licensee is the journal publisher. This is an Open Access article distributed under the terms of the Creative Commons Attribution License (<http://creativecommons.org/licenses/by/4.0>), which permits unrestricted use, distribution, and reproduction in any medium, provided the original work is properly cited.

Peer-review history:
The peer review history for this paper can be accessed here:
<https://www.sdiarticle5.com/review-history/118310>