



A Rare Case Presentation of Chondromyxoid Fibroma Involving the Sphenoid Sinus

F. El Mourabit ^{a*}, C. Rsaissi ^a, M. Loudghiri ^a, W. Bijou ^a,
Y. Oukessou ^a, S. Rouadi ^a, R. Abada ^a, M. Roubal ^a
and M. Mahtar ^a

^a *Department of Otolaryngology, Head and Neck Surgery, University Hospital Ibn Rochd, Casablanca, Morocco.*

Authors' contributions

This work was carried out in collaboration among all authors. All authors read and approved the final manuscript.

Article Information

Open Peer Review History:

This journal follows the Advanced Open Peer Review policy. Identity of the Reviewers, Editor(s) and additional Reviewers, peer review comments, different versions of the manuscript, comments of the editors, etc are available here: <https://www.sdiarticle5.com/review-history/113847>

Case Study

Received: 19/12/2023

Accepted: 28/02/2024

Published: 29/02/2024

ABSTRACT

Chondromyxoid fibroma (CMF) is an uncommon benign tumor of chondroid, myxoid and fibrous tissues. It is a rare bone tumor found mainly in long bones, so its presence at the base of the skull is particularly rare. The presence of monoclonal gammopathy of minor significance (MGUS) prompted the consideration and investigation of a plasma cell disorder. We describe the diagnosis and treatment of a 47-year-old female patient with a large CMF originating from the sphenoid sinus. However, chondromyxoid fibroma was correctly diagnosed based on CT and MRI results and a biopsy.

Keywords: *Chondromyxoid fibroma; sphenoid sinus; CT; magnetic resonance imaging; monoclonal gammopathy of undetermined significance.*

*Corresponding author: E-mail: fadouaelmourabit1993@gmail.com;

1. INTRODUCTION

The chondromyxoid fibroma (CMF), first identified in 1948 by Jaffe and Lichtenstein, is a cartilaginous origin tumor that makes up less than 0.5 percent of all bone cancers [1-2] and is somewhat more common in men [3]. "Between 1 and 5% of CMF instances are documented to occur in the head and neck, despite the condition being more frequently detected in the metaphysis of long bones" [3-4].

In a review of 278 cases, 15 were in the skull or facial bones [5], and 1 of 189 cases in a study of 76 cases of chondromyxoid fibroma, which included additional cases from the literature, were in the skull [6]. A chondroid, fibrous, and myxoid material intermingled in lobulated patches is a chondroid fibroma [7]. This benign tumor can be seen in several anatomic regions, such as the long bones, flat bones, and cranio-facial bones [8]. It is particularly common in young individuals. We report the case of a 47-year-old female patient who had chondromyxoid fibroma in the sphenoid sinus.

2. CASE REPORT

A 47-year-old woman, with no particular pathological antecedents, presented to the otorhinolaryngology - head and neck surgery department with chronic bilateral nasal obstruction for 1 year with anosmia and no other

associated rhinological signs, in particular no epistaxis and no facial pain. Physical examination, including nasal endoscopy, revealed a large mass in the right and left nasal cavity pushing the turbinates towards the septum. There were no associated symptoms such as visual complaints, paresthesia, facial pain or cephalgia. A biopsy was taken in the operating theatre, and histopathological evaluation revealed a lobular growth pattern with stellate or spindle cells on a chondroid background (Fig 1). There was no well-developed hyaline cartilage. The pathology report indicated that the morphological features were consistent with CMF.

Prior to definitive resection, preoperative computed tomography (CT) and magnetic resonance imaging (MRI) imaging were completed for anatomic mapping and surgical planning the CT scan revealed the presence of an osteolytic tissue lesion process centered on the body of the isodense sphenoid, the seat of popcorn calcification measuring approximately 48*37 mm and extending over 49 mm, which invades the nasal septum, turbinates and posterior ethmoidal cells at the front, laterally, it invades the cavernous sinus and comes into contact with the intracavernous portion of the internal carotid arteries; posteriorly, it invades and lyses the left carotid duct and the clivus; superiorly, it is responsible for lysis of the sella turcica; and battermally, it invades the soft palate.

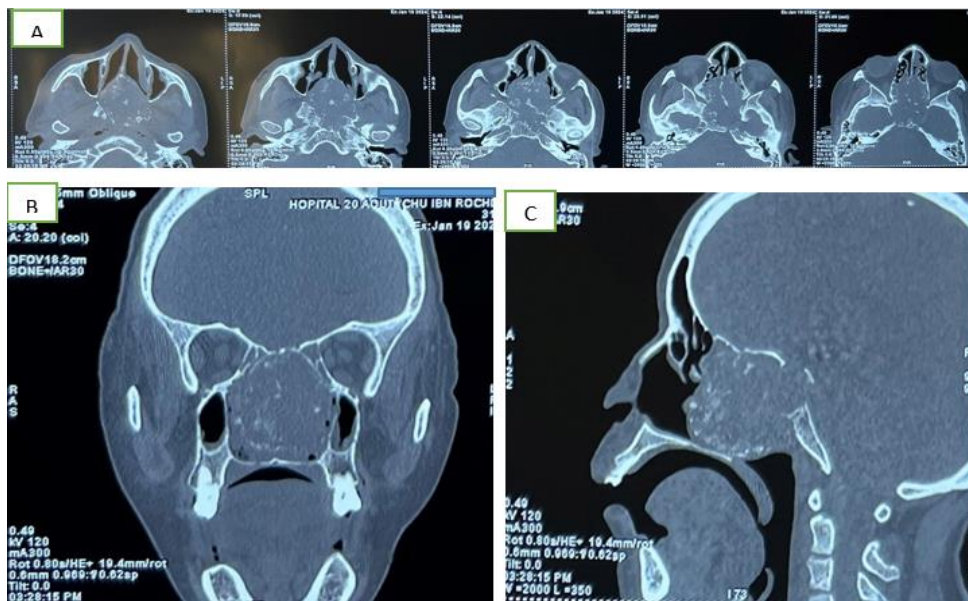


Fig. 1. 47-year-old woman with chondromyxoid fibroma involving the sphenoid sinus Axial (A), coronal (B) and sagittal (C) CT images demonstrate a locally advanced sphenoid tumor process with posterior invasion of the left carotid duct and clivus

MRI with and without contrast supported the CT findings and demonstrated cystic components (Fig 2B) with relative T2 hypointensity concerning for high cellularity or a high nuclear-to-cytoplasmic ratio.

Because the patient in our case did not exhibit any symptoms and because total resection was expected to be complicated, and according to the wishes of the patient who has refused surgery to curettage the tumor mass, follow-up was decided upon instead of excision. This case was discussed at the multidisciplinary consultation meeting.

3. DISCUSSION

“Chondromyxoid fibroma (CMF) is a rare benign primary tumor accounting for 1.6% of the benign tumors in the series that Unni and Inwards investigated” [7]. “A lytic lesion that is round or oval in shape and less than 5 cm in diameter, chondromyxoid fibromas are typically found in the metaphysis of long tubular bones, however they can also occasionally affect the nasal bone, mandible, base of the skull, or frontal bone. Early adulthood is when chondromyxoid fibroma typically manifests” [7].

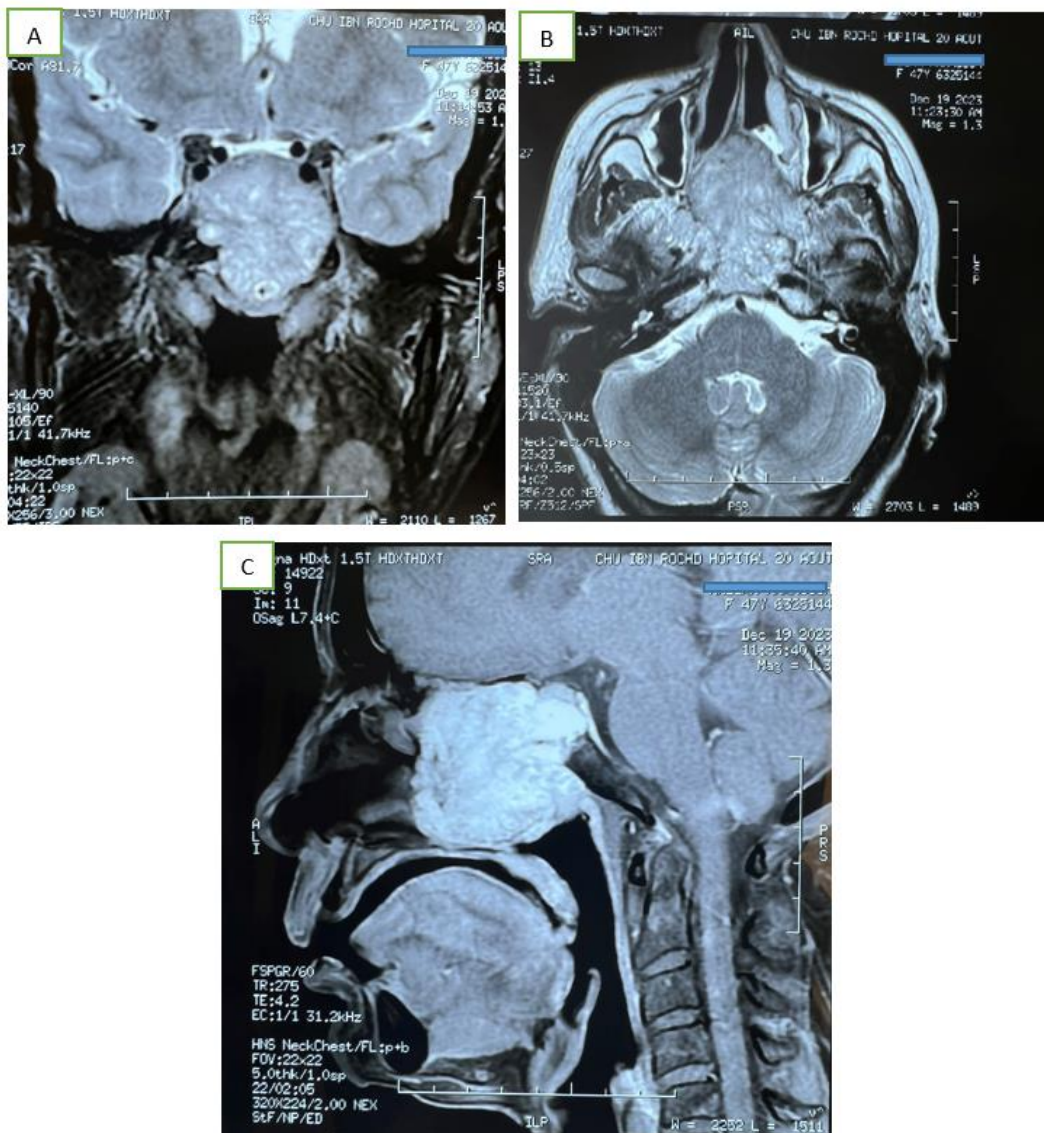


Fig. 2. MR imaging from (a) coronal Plane, (b) Axial plane and (c) sagittal plane, demonstrating locally advanced sphenoid sinus tumor process, with scattered calcifications, with heterogeneous uptake

“Due to its uncommon incidence rate, CMF is a difficult disease to directly examine, and the current study's related drawback is the presentation of only one case. A review of the literature finds several studies that describe involvement of large portions of the skeleton. Cases have been found in the sella turcica, clivus, mastoid process, and paranasal sinuses of the head and neck” [9]. Table 1 contains additional information about all reported instances of paranasal CMF, including patient demographics, location, therapy, and follow-up.

Table 1 indicates that clinical sequelae arise secondary to the mass effect rather than specific to the acute pathology of CMF. The literature review indicates inconsistent presenting symptoms. The lack of specificity of symptoms highlights the significance of a thorough evaluation and workup in obtaining an accurate diagnosis.

“On radiography, CT, and MRI, chondromyxoid fibroma resembles these other cartilage tumors. Everybody shows a diverse rise in signal on T2-weighted imaging and a decrease in signal on T1-weighted images. They frequently show calcification of the chondroid matrix on radiography and CT” [130, 31]. T2-weighted scans show heterogeneity because the tumor's chondroid, myxoid, and fibrous components differ. All of these lesions will often brighten when exposed to gadolinium [30, 31]. The margins of chondromyxoid fibromas are typically well-defined [7].

“Both chordomas and chondrosarcomas frequently show obvious bone loss [30, 31]. Chordomas are generally regarded to arise in the midline, while chondrosarcomas are thought to arise off the midline, along the petro-occipital fissure” [31]. “However, this orthodoxy was not supported by a recent study that examined 38 chordomas and 4 low-grade chondrosarcomas that were located in the base of the skull” [30].

“Because the imaging results from different lesions overlap, a thorough histopathologic assessment is essential to determining the correct diagnosis. Zilmer and Dorfman noted a 22% first misdiagnosis rate in their cohort of 36 CMF patients and the possibility of more harsh therapy being administered than is necessary, such as amputating the affected limb for a benign lesion” [32,33]. According to the World Health Organization, CMF is “a benign tumor

characterized by zones of more cellular tissue rich in spindle-shaped or round cells with a varying number of multinucleated giant cells of different sizes” and “lobules of spindle-shaped or stellate cells with abundant myxoid or chondroid intercellular material.” [34] The central nuclei of stellate or spindle-shaped cells have eosinophilic cytoplasm and black chromatin that is either homogenous or coarsely distributed. Atypia and nuclear pleomorphism are less prevalent in CMF and more indicative of chondrosarcoma [35-37]. Moreover, chondrosarcoma lacks the myxochondroid tissue's crossing bands. In addition to a “bubbly appearance to the stroma along with degenerative and liquefactive changes,” Castle et al. list this as one of the diagnostic features of chondrosarcomas [36]. “On the other hand, chordomas have the almost pathognomonic physaliferous cells (those with copious, bubbly, or vacuolated eosinophilic cytoplasm) associated with the lesion” [38].

Excision is a common treatment for chondromyxoid fibromatosis [39]. However, the recurrence following excision is common since tumors may not fully disappear and may resurface [40-42]. This reaction is often limited, and a harmful conversion is unlikely [39]. However, radiation therapy is typically avoided due to cases of malignant transformation [43].

While surgical excision is the usual course of treatment for craniofacial lesions (CMF), some authors propose curettage specifically for facial CMF with strict monitoring due to the functional and esthetic repercussions of extensive resection. By citing the high recurrence rate following curettage, Baujat et al. claimed that broad surgical resection is the most effective method for achieving long-term control [44]. Certain situations, like the one mentioned above, might be candidates for endoscopic resection.

The possibility of malignant transformation of remaining tissue is another factor in favor of surgery. Despite a low transformation incidence [45], instances of malignant transformation have been documented, and radiation therapy has been associated with an increased risk of transformation [6, 46, 47]. However, getting total excision is more challenging in a position at or near the base of the skull [30]. In an effort to lessen recurrence, several writers have proposed postoperative irradiation [48].

Table 1. Location-based outcome statistics for all documented instances of CMF in the paranasal sinuses

Author	Age y, mo, or d/ Sex	Location	Treatment	Follow-up	Clinical presentation	Duration of symptoms
Keel et al. [10]	65 y/F	Clivus with extension to sphenoid and ethmoid sinuses	Curettage and radiation	Local recurrence after 6 mo; after radiation, 20 mo DF	2/3 patients in this series presented with headache while other	NA
Keel et al. [10]	66 y/F	Clivus with extension to sphenoid and ethmoid sinuses	Curettage	26 mo DF	2/3 patients in this series presented with headache while other	NA
Iseberg et al. [11]	34 y/F	Ethmoid sinus	Endoscopic excision, ethmoidectomy	8 mo DF	Difficulty breathing	3 y
Mendoza et al. [12]	1 mo/M	Ethmoid sinus	Block resection	2 y DF	Respiratory difficulty	1 mo
Nazeer et al. [13]	20 d/M	Ethmoid sinus	Surgical resection	12 mo DF	Respiratory difficulty since birth	20 d
Szmeja et al. [14]	8 y/F	Ethmoid sinus	Total enucleation	NA	NA	NA
Won et al. [15]	28 y/M	Ethmoid sinus	Partial curettage	NA	Intermittent, pulsatile pain of right temporal area	Long-standing
Cruz et al. [16]	10 y/F	Ethmoid sinus invading orbit	Coronal approach with en bloc resection	NA	Progressive exophthalmos of left eye	7 mo
Hashimoto et al. [17]	32 y/M	Ethmoid sinus, extending to frontal sinus and orbit	Surgical resection	2 y DF	Painless left frontal swelling and progressive exophthalmos	1 y
Azarin et al. [18]	46 y/M	Frontal sinus	Subfrontal approach, superior orbitotomy, and block resection, including pericranium and surrounding frontal bone	22 mo DF	Right supraciliary frontal mass	18 mo
Wolf et al. [19]	35 y/F	Frontal-sphenoid junction with orbital infiltration	Left craniotomy with piecemeal removal	NA	Frontal headache	4 mo
Perez-Fernandez et al. [20]	60 y/M	Maxillary sinus with extension into ethmoid sinus	Endoscopic resection and post-ethmoidectomy, Caldwell-Luc	5 y DF	Left nasal obstruction with recurrent ipsilateral epistaxis	"several months"
Koay et al. [40]	57 y/F	Nasal bone with extension to frontal and ethmoid sinuses	Incomplete surgical excision	NA	Slowly expanding, painless swelling over bridge of nose	2 y
Baujat et al. [21]	50 y/F	Nasal bone, extension into frontal and	Frontal bone window with dura removal	18 mo DF	Frontal headache, pain, nasal obstruction and tearing	3 mo

		ethmoidal sinuses with dural involvement				
Wang et al. [22]	60 y/F	Nasal septum	Complete surgical removal	6 mo DF	No clinical discomfort (MH: congenital right aural atresia)	60 y
Veras et al. [24]	60 y/F	Nasal septum	Surgical excision	12 mo DF	Incidental (asymptomatic)	NA
McClurg et al. [25]	49 y/F	Nasal septum extending into the maxilla	Midface degloving with resection of nasal septum, left ethmoid, and left partial maxilla	16 mo DF	Sinonasal congestion	6 mo
Januszek et al. [26]	51 y/F	Nasal septum, extension into maxillary and sphenoid sinuses	Surgical resection	Recurrence after 12 mo, reoperated	NA	NA
Frank et al. [27]	26 y/M	Petrous/sphenoid bones extending into posterior clinoid, sella, and cavernous sinus	Complete surgical removal	NA	Diplopia	1 mo
Vernon et al. [28]	44 y/M	Sphenoid sinus	Endoscopic sphenoid sinusotomy and posterior ethmoidectomy	NA	Left retroorbital pain	3 mo
Morris et al. [29]	52 y/F	Sphenoid sinus, eroding floor of sphenoid sinus	Endoscopic resection with rim of normal bone	2 y DF	No sinonasal signs or symptoms	NA
Nazeer et al. [13]	66 y/F	Sphenoid sinus, extension into nasopharynx and sella	Surgical curettage	Local recurrence after 1 y, curetted, 6 mo DF	Nasal obstruction	Several years

Abbreviations: NA, Not Available or not covered in the article; DF, Disease-Free; M, Male; F, Female; y, Year; mo, Month; d, Day; CMF: Chondromyxoid Fibroma

4. CONCLUSION

A review of the literature shows that CMF has been recorded to arise in the sinonasal cavity, despite being an extremely rare tumor that accounts for less than 0.5 percent of all bone tumors. histopathologic distinction is necessary for appropriate treatment. Stellate cells are abundantly found within a myxoid or chondroid matrix, as revealed by a biopsy. Inaccessible tumors may require curettage, but total surgical resection is the ideal treatment to reduce the chance of recurrence.

CONSENT

As per international standards or university standards, patient(s) written consent has been collected and preserved by the author(s).

ETHICAL APPROVAL

As per international standards or university standards written ethical approval has been collected and preserved by the author(s).

COMPETING INTERESTS

Authors have declared that no competing interests exist.

REFERENCES

1. Chondromyxoid fibroma. Dahlin's Bone Tumors. Unni KK, Inwards CY (ed): Wolters Kluwer, Philadelphia, US; 2010;6:50-59.
2. Rahimi A, Beabout JW, Ivins JC, Dahlin DC: Chondromyxoid fibroma: A clinicopathologic study of 76 cases. *Cancer*. 1972;30:726-736. DOI:10.1002/1097-0142(197209)30:3<726::aid-cnrc2820300321>3.0.co;2-t
3. Wu CT, Inwards CY, O'Laughlin S, Rock MG, Beabout JW, Unni KK: Chondromyxoid fibroma of bone: a clinicopathologic review of 278 cases. *Hum Pathol*. 1998;29:438-446. DOI: 10.1016/s0046-8177(98)90058-2
4. Isenberg SF: Endoscopic removal of chondromyxoid fibroma of the ethmoid sinus. *Am J Otolaryngol*. 1995;16:205-208. DOI: 10.1016/0196-0709(95)90105-1
5. Wu CT, Inwards CY, O'Laughlin S, Rock MG, Beabout JW, Unni KK: Chondromyxoid fibroma of bone: a clinicopathologic review of 278 cases. *Hum Pathol*. 1998;29(5):438-446
6. Rahimi A, Beabout JW, Ivins JC, Dahlin DC. Chondromyxoid fibroma: A clinicopathologic study of 76 cases. *Cancer*. 1972;30:726-736.
7. Unni K, Inwards C. Dahlin's bone tumors. Lippincott Williams & Wilkins; 2010.
8. Wang C, Morrow T, Friedman P, Lara JF: Chondromyxoid fibroma of the nasal septum: a case report emphasizing clinical correlation. *Am J Rhinol*. 2000 ;14:45-49. DOI: 10.2500/105065800781602885
9. Lingen MW, Solt DB, Polverini PJ: Unusual presentation of a chondromyxoid fibroma of the mandible. Report of a case and review of the literature. *Oral Surg Oral Med Oral Pathol*. 75, 615-621. DOI: 10.1016/0030-4220(93)90236-w
10. Keel SB, Bhan AK, Liebsch NJ, Rosenberg AE: Chondromyxoid fibroma of the skull base: a tumor which may be confused with chordoma and chondrosarcoma: a report of three cases and review of the literature. *Am J Surg Pathol*. 1997, 21:577-582.
11. Isenberg SF: Endoscopic removal of chondromyxoid fibroma of the ethmoid sinus. *Am J Otolaryngol*. 1995 ;16:205-208. DOI: 10.1016/0196-0709(95)90105-1
12. Mendoza M, Gonzalez I, Aperribay M, Hermosa JR, Nogues A: Congenital chondromyxoid fibroma of the ethmoid: case report. *Pediatr Radiol*. 1998;28:339-341. DOI:10.1007/s002470050369
13. Nazeer T, Ro JY, Varma DG, de la Hermosa JR, Ayala AG: Chondromyxoid fibroma of paranasal sinuses: report of two cases presenting with nasal obstruction. *Skeletal Radiol*. 1996 ; 25:779-782. DOI: 10.1007/s002560050179
14. Szmeja Z, Obrebowski A, Strzykowski M, Lukaszewski B: Chondromyxofibroma ossificans of the ethmoidal labyrinth in a child. *Int J Pediatr Otorhinolaryngol*. 1981;3:151-156. DOI:10.1016/0165-5876(81)90031-8
15. Won KY, Lee J, Kim YW, Kim EJ, Kim SW, Park YK: Chondromyxoid fibroma of the ethmoid sinus complicated by a brain abscess: a case report and literature review. *Korean J Pathol*. 2010;44:547-550. DOI:10.4132/KoreanJPathol.

16. Cruz AA, Mesquita IM, Becker AN, Chahud F: Orbital invasion by chondromyxoid fibroma of the ethmoid sinus. *Ophthal Plast Reconstr Surg.* 2007;23:427-428. DOI: 10.1097/IOP.0b013e318146986c
17. Hashimoto M, Izumi J, Sakuma I, Iwama T, Watarai J: Chondromyxoid fibroma of the ethmoid sinus. *Neuroradiology.* 1998;40:577-579. DOI: 10.1007/s002340050647
18. Azorin D, Gil A, Sanchez-Aniceto G, Ballestin C, Martinez-Tello FJ: Chondromyxoid fibroma of the frontal sinus. *Br J Oral Maxillofac Surg.* 2003;41:418-420. DOI:10.1016/S0266-4356(03)00168-2
19. Wolf DA, Chaljub G, Maggio W, Gelman BB: Intracranial chondromyxoid fibroma. Report of a case and review of the literature. *Arch Pathol Lab Med.* 1997, 121:626-630.
20. Perez-Fernandez CA, Armengot-Carceller M, Lozano de Arnilla CG, Valles AP, Basterra-Alegria J: Chondromyxoid fibroma of left maxillary and ethmoid sinuses. *Acta Otorrinolaringol Esp.* 2009 ;60:70-72. DOI: 10.1016/S2173-5735(09)70102-4
21. Koay CB, Freeland AP, Athanasou NA: Chondromyxoid fibroma of the nasal bone with extension in the frontal and ethmoid sinuses. *J Laryngol Otol.* 1995; 109:258-261. DOI: 10.1017/S002221510012986X
22. Baujat B, Attal P, Racy E, Quillard J, Parker F, Evannou A, Bobin S: Chondromyxoid fibroma of the nasal bone with extension into the frontal and ethmoidal sinuses: report of one case and a review of the literature. *Am J*
23. Wang C, Morrow T, Friedman P, Lara JF: Chondromyxoid fibroma of the nasal septum: a case report emphasizing clinical correlation. *Am J Rhinol.* 2000;14:45-49. DOI: 10.2500/105065800781602885
24. Veras EFT, Santamaria IB, Luna MA: Sinonasal chondromyxoid fibroma. *Ann Diagn Pathol.* 2009, 13:41-46. DOI: 10.1016/j.anndiagpath.2007.05.006
25. McClurg SW, Leon M, Teknos TN, Iwenofu OH: Chondromyxoid fibroma of the nasal septum: case report and review of literature. *Head Neck.* 2013;35:1-5. DOI: 10.1002/hed.21760
26. Januszek G, Niemczyk K, Gornicka B, Gotlib T: Chondromyxoid fibroma of the nasal septum. *Otolaryngol Pol.* 2010;64:88-92. DOI: 10.1016/S0030-6657(10)70041-X
27. Frank E, Deruaz JP, de Tribolet N: Chondromyxoid fibroma of the petrous-sphenoid junction. *Surg Neurol.* 1987, 27:182-186. DOI: 10.1016/0090-3019(87)90293-X
28. Vernon SE, Casiano RR: Sphenoid sinus chondromyxoid fibroma mimicking a mucocele. *Am J Otolaryngol.* 2006;27:406-408. DOI: 10.1016/j.amjoto.2006.01.004
29. Morris LGT, Rihani J, Lebowitz RA, Wang BY: Chondromyxoid fibroma of sphenoid sinus with unusual calcifications: case report with literature review. *Head Neck Pathol.* 2009 ;3:169-173. DOI:10.1007/s12105-009-0121-6
30. Pamir MN, Özduman K. Analysis of radiological features relative to histopathology in 42 skull-base chordomas and chondrosarcomas. *Eur J Radiol.* 2006;58(3):461–470. Epub 2006 May 2.
31. Otto BA, Jacob A, Klein MJ, Welling DB. Chondromyxoid fibroma of the temporal bone: Case report and review of the literature. *Ann Otol Rhinol Laryngol.* 2007;116(12):922–927.
32. Zillmer DA, Dorfman HD: Chondromyxoid fibroma of bone: Thirty six cases with clinicopathologic correlation. *Hum Pathol.* 1989;20:952-964. DOI: 10.1016/0046-8177(89)90267-0
33. Castle JT, Kernig ML: Chondromyxoid fibroma of the ethmoid sinus. *Head Neck Pathol.* 2011;5:261-264. DOI: 10.1007/s12105-011-0275-x
34. Pathology and Genetics of Tumors of Soft Tissue and Bone. Fletcher CD, Unni KK, Mertens F (ed): IARC Press, Lyon; 2002.
35. Cruz AA, Mesquita IM, Becker AN, Chahud F: Orbital invasion by chondromyxoid fibroma of the ethmoid sinus. *Ophthal Plast Reconstr Surg.* 2007;23:427-428. DOI: 10.1097/IOP.0b013e318146986c
36. Castle JT, Kernig ML: Chondromyxoid fibroma of the ethmoid sinus. *Head Neck Pathol.* 2011, 5:261-264. DOI: 10.1007/s12105-011-0275-x
37. Ghanem N, Uhl M, Althoefer C, Adler CP: Chondromyxoid fibroma of the sinonasal cavity. *Eur J Radiol Extra.* 2003;46:21-25. DOI: 10.1016/S1571-4675(03)00037-3

38. Morris LGT, Rihani J, Lebowitz RA, Wang BY: Chondromyxoid fibroma of sphenoid sinus with unusual calcifications: case report with literature review. *Head Neck Pathol.* 2009;3:169-173.
DOI: 10.1007/s12105-009-0121-6
39. Patino-Cordoba JI, Turner J, McCarthy SW, Fagan P. Chondromyxoid fibroma of the skull base. *Otolaryngol Head Neck Surg.* 1998;118(3 Pt 1):415–418.
40. Mirra JM. Bone tumors: clinical, radiologic, and pathologic correlations. Lea and Febiger; Philadelphia: 1989;648–658.
41. Zillmer DA, Dorfman HD. Chondromyxoid fibroma of bone: Thirty-six cases with clinicopathologic correlation. *Hum Pathol.* 1989;20(10):952–964.
42. Shek TW, Peh WC, Leung G. Chondromyxoid fibroma of skull base: a tumour prone to local recurrence. *J Laryngol Otol.* 1999;113(4):380–385.
43. Oruckapten H, Karli Oğuz K, Isikay I, Ruacan S. Amyloidoma of the temporal bone and upper cervical spine; presentation of a rare clinical entity with a brief literature review. *Turkish Neurosurgery.* 2009;19(2):159–162.
44. Baujat B, Attal P, Racy E, Quillard J, Parker F, Evannou A, Bobin S: Chondromyxoid fibroma of the nasal bone with extension into the frontal and ethmoidal sinuses: Report of one case and a review of the literature. *Am J Otolaryngol.* 2001, 22:150-153.
DOI: 10.1053/ajot.2001.22582
45. Patino-Cordoba JI, Turner J, McCarthy SW, Fagan P: Chondromyxoid fibroma of the skull base. *Otolaryngol Head Neck Surg.* 1998 ;118:415-418.
DOI: 10.1016/S0194-59989870329-8
46. Zillmer DA, Dorfman HD: Chondromyxoid fibroma of bone: thirty six cases with clinicopathologic correlation. *Hum Pathol.* 1989 ;20:952-964.
DOI: 10.1016/0046-8177(89)90267-0
47. Otto BA, Jacob A, Klein MJ, Welling DB: Chondromyxoid fibroma of the temporal bone: case report and review of the literature. *Ann Otol Rhinol Laryngol.* 2007;116:922-927.
DOI: 10.1177/000348940711601209
48. Feuvret L, Noel G, Calugaru V, Terrier P, Habrand JL. Chondromyxoid fibroma of the skull base: Differential diagnosis and radiotherapy: two case reports and a review of the literature. *Acta Oncol.* 2005;44:545-553.
DOI: 10.1080/00365590500237846

© Copyright (2024): Author(s). The licensee is the journal publisher. This is an Open Access article distributed under the terms of the Creative Commons Attribution License (<http://creativecommons.org/licenses/by/4.0>), which permits unrestricted use, distribution, and reproduction in any medium, provided the original work is properly cited.

Peer-review history:

The peer review history for this paper can be accessed here:
<https://www.sdiarticle5.com/review-history/113847>