

Extra Pulmonary Tuberculosis in Pregnancy: A Case Report

ANNAREDDY LAKSHMI PRIYA¹, PATIL N RAVI²

(CC) BY-NC-ND

Tuberculosis (TB) in pregnancy is a major health problem which possess a sustainable risk of morbidity to mother and fetus if not diagnosed and treated at correct time. The diagnosis in pregnancy is challenging, especially in the absence of lung involvement. It usually mimics other diseases as most of the patients with extra pulmonary TB present usually with nonspecific symptoms which misleads the diagnosis. Hence, it is very important to address even nonspecific symptoms in pregnancy as a neglected diagnosis and delayed treatment may lead to severe perinatal morbidity and mortality like fetal distress, preterm delivery, fetal growth retardation, seizures due to intra cranial space occupying lesion, perforation of intestinal lesions, pneumoperitonitis, high chances of intensive care unit admission for mother and neonate. Hereby, authors report two cases, one about a 29-year-old primigravida with numbness and paresthesia of unilateral limbs. She was diagnosed of intracranial tuberculoma and treated with Antitubercular Drugs (ATT) for nine months. She underwent a cesarean section in view of an intracranial space-occupying lesion. Another patient was a prima gravida who presented with persistent gastroenteritis symptoms like vomiting and diarrhea. She was diagnosed to have ileocecal mass with suspicion of malignancy or infectious aetiology. In view of deteriorating maternal condition, emergency cesarean section was done along with resection of ileocecal mass. On histopathological examination it was found to be ileocecal TB and she was started on ATT.

Keywords: Antitubercular treatment, Extra pulmonary tuberculosis, ileocecal mass, Tuberculoma

CASE REPORTS

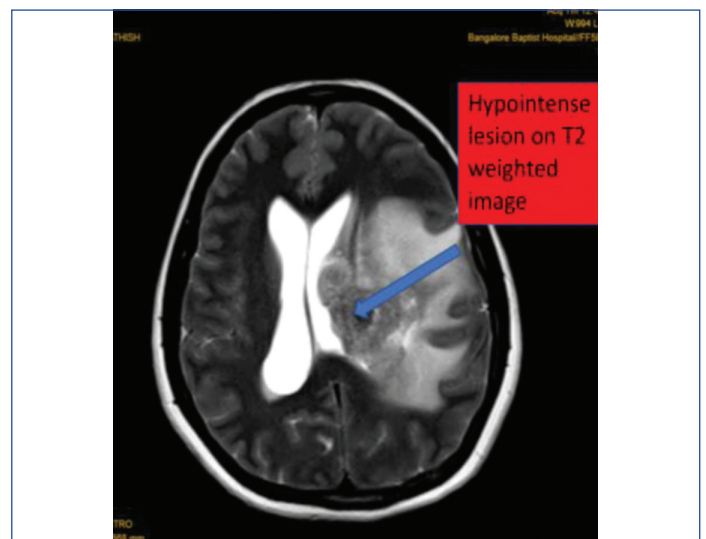
Case-1

A 29-year-old, booked primigravida at 32+6 weeks of gestation, presented with complaints of numbness and paresthesia in distal right upper and lower limb, associated with on/off headache from 24 weeks of gestation. The patient felt relief on taking paracetamol. She was on iron and calcium supplements from first trimester.

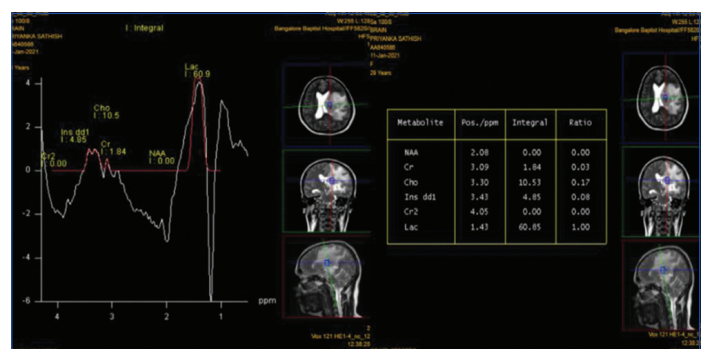
On examination, the patient was conscious, coherent, and well-oriented. On general examination, cervical lymphadenopathy was noted. On neurological examination, right-sided hypertonia was noted with exaggerated deep tendon reflexes, with positive Hoffman's sign, impaired proprioception on distal upper and lower limbs on right-side. Cervical myelopathy was suspected and Magnetic Resonance Imaging (MRI) was done which showed an intracranial hypodense space-occupying lesion of 5.5x3.8 cm in the left periventricular region, with a 10 mm midline shift [Table/Fig-1]. On Magnetic Resonance Spectroscopy (MRS), there was high lactate and lipid peak, suggesting TB [Table/Fig-2]. Hence, cervical lymph node biopsy was done which revealed a non caseating granuloma. TB gene Xpert showed positivity for *Mycobacterium tuberculosis*, with rifampicin-sensitivity.

She was started on ATT according to Revised National TB Control Programme (RNTCP) (2HRZE+7HR) (H-Isoniazid 5-10 mg/kg, R-Rifampicin 10-15 mg/kg, Z-Pyrazinamide 25 mg/kg, E-Ethambutol 15 mg/kg), two months intensive phase followed by seven months of continuation phase.

The patient was called after one month for follow-up, patient was symptomatically better. A repeat MRI showed reduction in size of the lesion from 5.5x3.8 cm to 5x3.8 cm with 8 mm midline shift. In view of the intracranial lesion, elective Lower Segment Cesarean Section (LSCS) was planned at term, but the patient had preterm premature rupture of membranes at 36+5 weeks of gestation. She underwent emergency LSCS, and gave birth to a male, weighing 2.52 kg. The neonate was started on isoniazid 10 mg/kg for three months. Post operative period was uneventful, and the patient

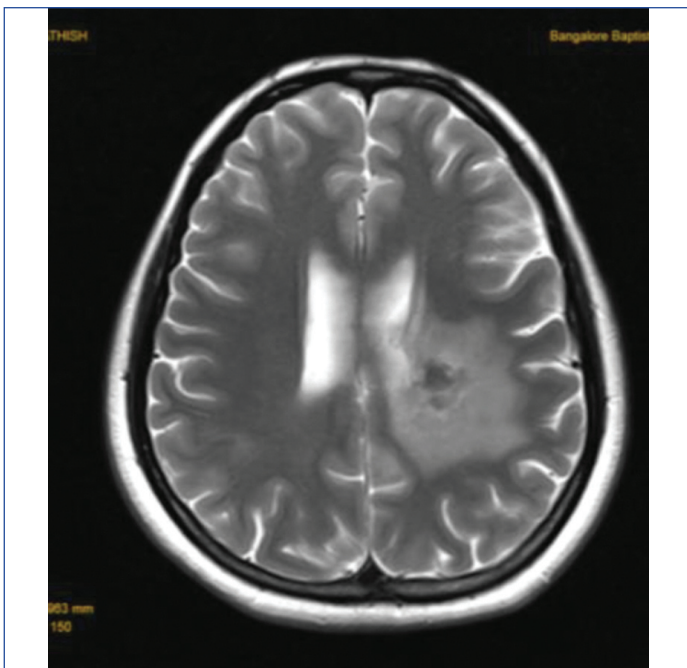


[Table/Fig-1]: MRI pre treatment intracranial hypodense space-occupying lesion of 5.5x3.8 cm in the left periventricular region, with a 10 mm with mid line shift.



[Table/Fig-2]: MR spectroscopy showing a high lactate and lipid peak, suggesting tuberculosis.

continued the same dose of ATT for a total of nine months and repeat MRI after six months show reduce in lesion of 5.6x3.6 cm with 1.5 mm shift [Table/Fig-3].



[Table/Fig-3]: MRI post treatment showing a 5.6x3.6 cm lesion in the periventricular region with midline shift of 1.5 mm towards right.

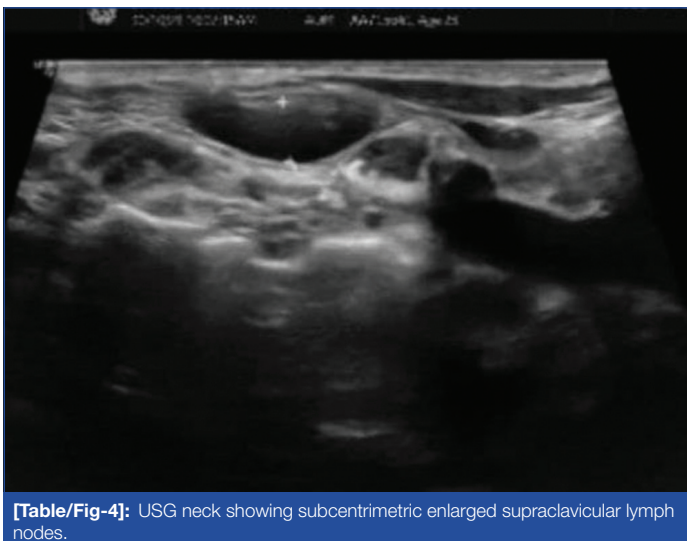
Case 2

A 23-year-old primigravida, at 33+6 weeks gestation, was referred from elsewhere with a suspicion of ileocecal cancer of infectious aetiology. She had complaints of right iliac fossa pain, associated with vomiting, and 5-6 episodes of loose watery non foul-smelling stools per day, associated with loss of appetite, since one month. There was no history of fever. The ultrasound report (performed elsewhere) showed hepatomegaly with long segment colonic thickening. The radiographic diagnosis was colitis or ileocecal cancer with pericaecal fat stranding, along with enlarged ileocolic lymph nodes.

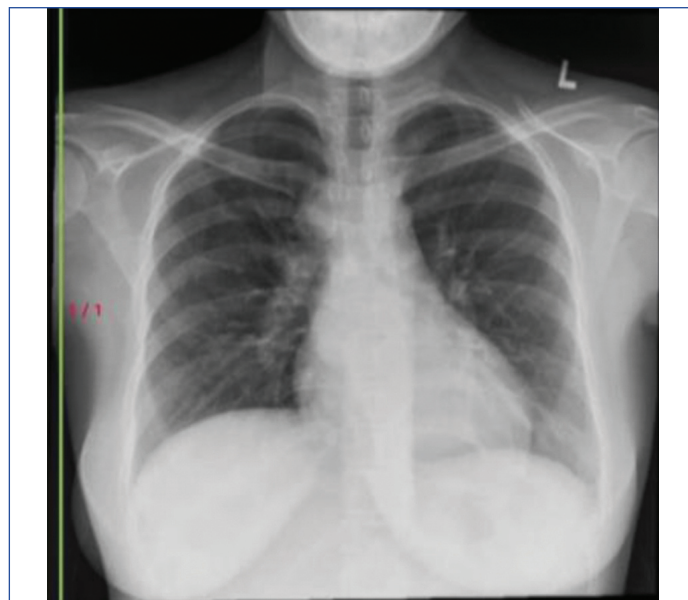
On examination, the patient was well-oriented, vitals were stable, and there were no signs of dehydration. Bilateral non tender supraclavicular lymph nodes were palpable. On per abdominal examination, the uterus corresponded to period of gestation, relaxed with tenderness over right ileac fossa. On auscultation, the fetal heart rate was good.

The patient was started on parenteral Ceftriaxone 1 gm twice a day, and Metronidazole 500 mg thrice a day. The C-Reactive Protein (CRP) was 4mg/dl, hence, antibiotics were changed to Inj. Piptaz (Piperacillin and Tazobactam) 4.5 gm six hourly (intravenous).

Ultrasonography (USG) neck was done for supraclavicular lymph node, which showed bilateral subcentrimetric enlarged lymph nodes

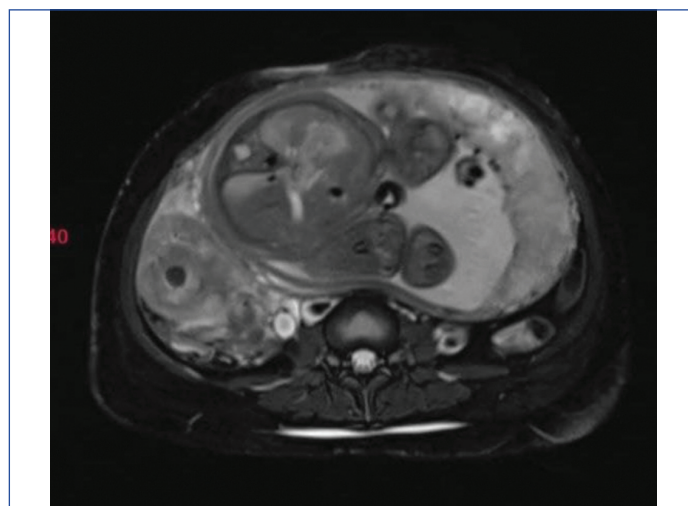


[Table/Fig-4]: USG neck showing subcentrimetric enlarged supraclavicular lymph nodes.



[Table/Fig-5]: Chest radiograph showing minimal pleural effusion.

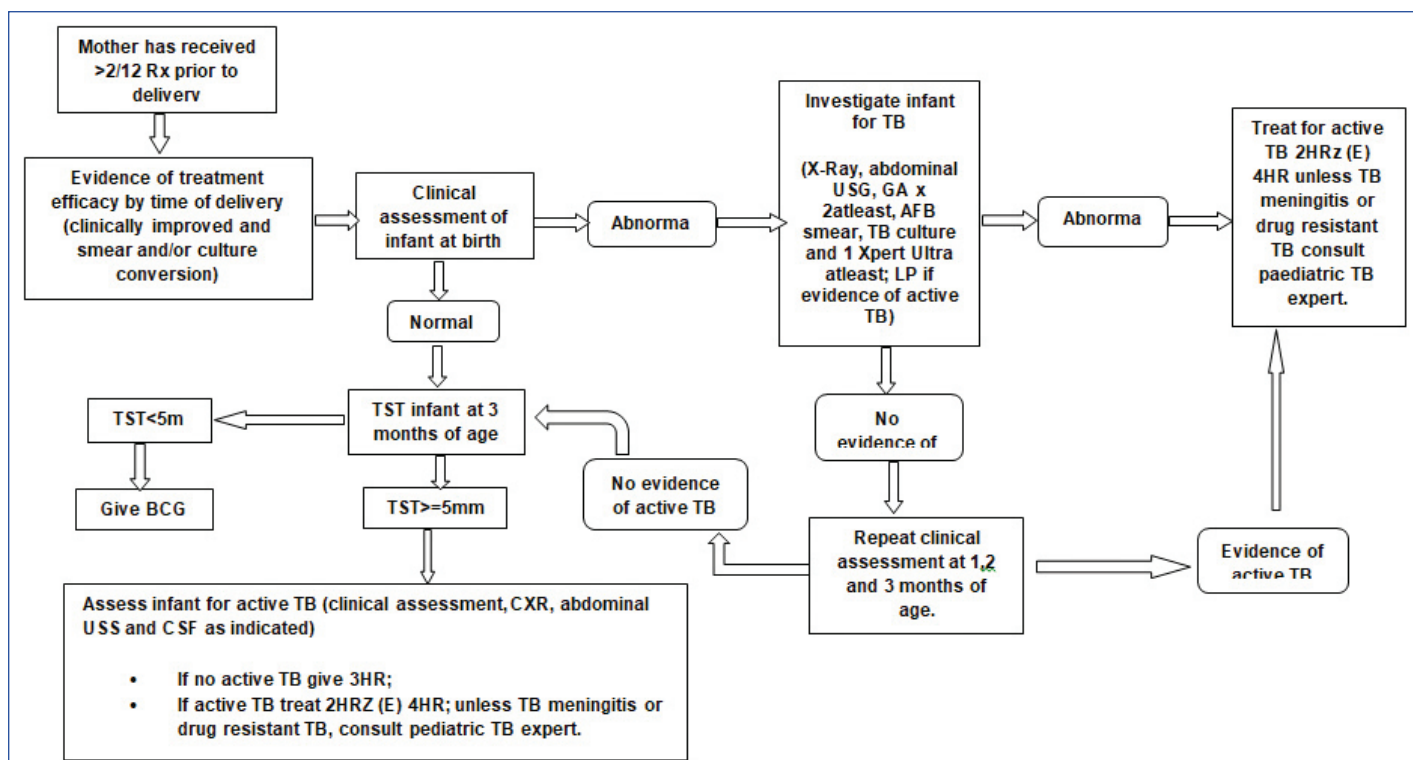
[Table/Fig-4]. Considering TB, Fine Needle Aspiration Cytology (FNAC) was done which revealed reactive lymphadenitis. Chest radiograph showed bilateral mild pleural effusion [Table/Fig-5]. MRI abdomen pelvis was planned suspecting TB or metastasis. It showed a 9.2x3 cm mass with circumferential wall thickening of ascending colon, with 7 mm lymph nodes, suggestive of colonic neoplasia with suspicious nodal metastasis [Table/Fig-6].



[Table/Fig-6]: MRI showing- circumferential wall thickening of ascending colon for 9.2 cm length and 3 cm thickness.

Hence, the patient was planned for colonoscopy and colonoscopy-guided biopsy, but because of the gravid uterus, the scope could not be negotiated beyond sigmoid flexure, and the biopsy was postponed. The patient's condition deteriorated, in spite of the broad-spectrum antibiotics. So, she was posted for emergency LSCS with laparotomy. Intraoperatively, minimal ascites was noted. There was an ileocecal mass of 10x8 cm size, which was resected, sent for histopathological examination and gene Xpert assessment. Multiple lymph nodes were noted along the mesentery, resected.

Postoperatively, the patient received units of packed red blood cells. TB gene Xpert reported positivity for *Mycobacterium tuberculosis*. Hence, ATT started according to RNTCP (2HRZE+4HRE) from postoperative day three for six months, two months intensive phase followed by four months continuation phase. Neonate was started on isoniazid prophylaxis 10 mg/kg for three months. The patient was reviewed after two weeks and she was symptomatically better. ATT was continued for six months.



[Table/Fig-7]: Pulmonary TB in pregnancy- mother unlikely to be infection.

DISCUSSION

TB causes about 2,20,000 deaths every year, out of which reproductive age women face a sustainable burden contributing approximately to 26% of total cases [1]. The incidence and prevalence of TB is largely unknown [2]. Pregnancy is a significant risk factor with sustainable risk of morbidity to both the pregnant women and fetus if not diagnosed and treated. India is among the endemic countries for TB, with a 20.6% global burden of active TB among pregnant women, out of which 10-27% contribute to extra pulmonary TB [1]. Risk factors and progression to active disease are the same as in the general population [Table/Fig-7].

The acid-fast bacilli causing TB undergo air-borne transmission via infectious droplets from contagious individuals. These bacilli are ingested by alveolar macrophages, which are attacked by the active and non compromised immune system. But in a few patients, because of an impaired immune system, the infection spreads into other organs beyond the lungs (extrapulmonary tuberculosis). The most common extrapulmonary system that is involved is the central nervous [3].

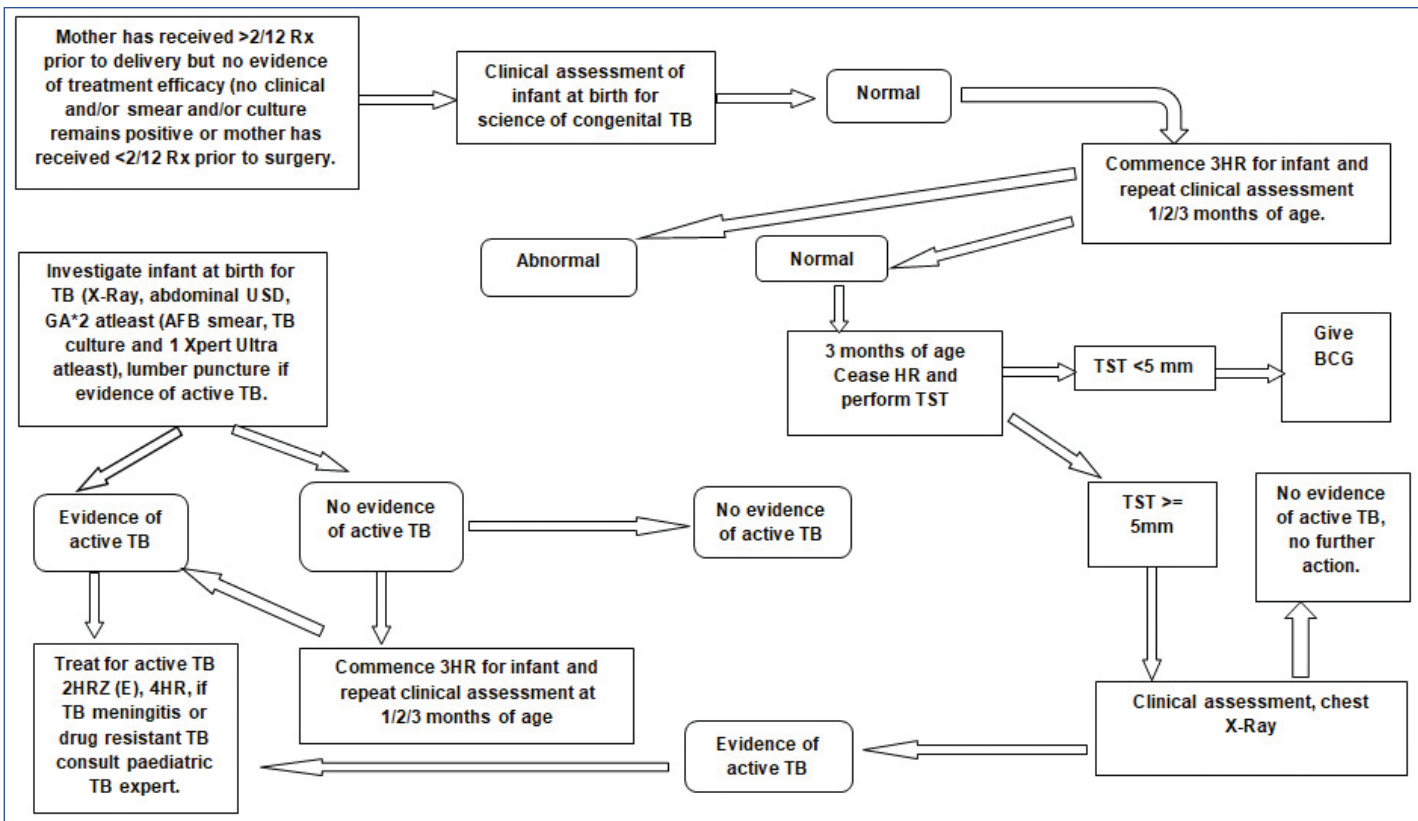
Within 2-8 weeks, the tubercle bacilli are surrounded by macrophages and form granuloma. The patient does not have any signs and symptoms and remains in the latent phase. But in an immunocompromised status, this latent TB progresses into an active form and presents as pulmonary or extrapulmonary tuberculosis [4]. Most of these people present with non specific symptoms, like, loss of weight, loss of appetite, fever, chills, and weakness which delays diagnosis and treatment [5].

Pregnancy, as such, does not increase the susceptibility to TB or its progression to active form if diagnosed and treated early. Intracranial tuberculomas can manifest either in subacute or chronic stages, usually lasting from weeks to months. If the disease is isolated or the lesions are small, the patients usually remain asymptomatic. But if the lesions are multiple or large in size, patients present with fever, vomiting, headache, focal neurological deficits, seizures, meningeal irritation signs, and intracranial hypertension with papilledema and mimic intracranial haemorrhage (delta hypertension or pregnancy-induced hypertension, glioma, abscess, tuberculoma) [6].

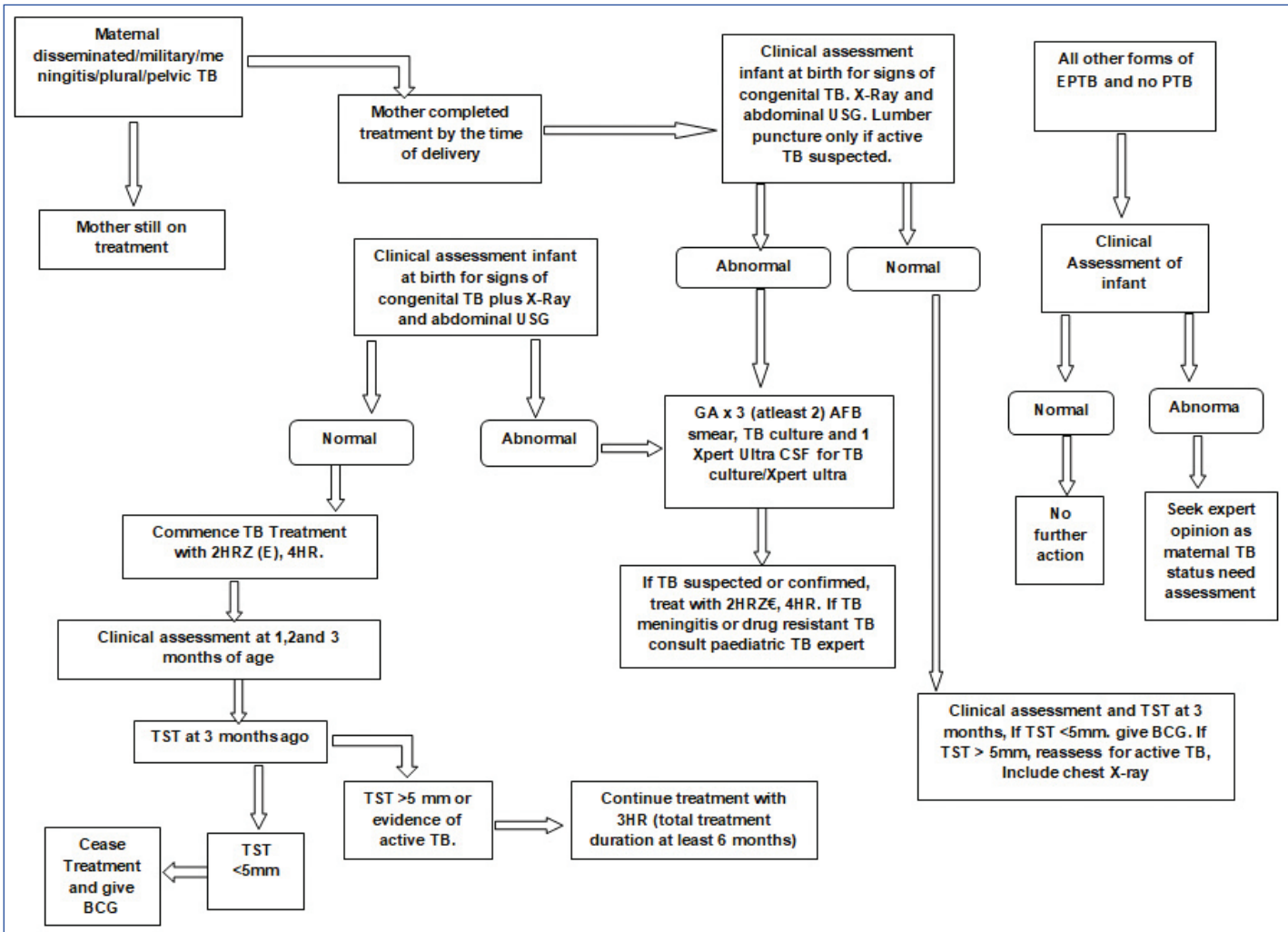
Abdominal TB in pregnancy contributes to 11% of the TB cases in pregnancy [7]. Usually, patients presents with acute gastroenteritis like vomiting, diarrhea, abdominal pain. But if not diagnosed and treated, it leads to an increased chance of perforation, pneumoperitonitis, and an increased risk of maternal mortality [7]. The risk increases if the treatment is not initiated [5,8]. Congenital TB occurs due to transplacental transmission or aspiration or ingestion of infected amniotic fluid. Most of these babies present in an early neonatal period with sepsis or bronchopneumonia or hepatosplenomegaly [9]. If any suspicion of congenital TB exists, the placenta should be sent for histopathological and mycobacterial culture. The current criteria for diagnosis of congenital TB are having at least one of the following: 1) lesions in the first week of life, a primary hepatic TB complex or caseating hepatic granulomas; 2) TB of placenta or maternal genital tract; 3) Exclusion of postnatal transmission with proven tuberculous lesion in the neonate [9].

General physical examination should also be performed with an emphasis on the pulmonary examination and also evaluating for any possible evidence of extrapulmonary TB in high endemic or high burden areas. Additionally, pregnant women with high risk of progressing to active TB disease (HIV infection, intravenous drug users, immunocompromised) should be evaluated for TB, and if screen-positive for a possible TB-related sign or symptom, or a risk factor for TB infection or progression to active TB disease, a Mantoux test should be performed as soon as possible. The Mantoux tuberculin skin test response becomes positive 2-12 weeks after exposure. An interferon gamma release assay measures ESAT-6 and CFP-10 antigens which are specific to MTB complex in BCG vaccinated individuals. A positive Mantoux tuberculin test or interferon-gamma release assay indicates TB exposure and infection, but cannot distinguish latent TB and active TB disease. If tuberculin or interferon gamma assay is positive, it is important to do chest radiography to look for active disease before initiating treatment for latent TB. A negative test does not mean complete exclusion of disease. The diagnosis of active TB disease is based on a combination of clinical presentation and symptoms, chest radiograph, and acid-fast bacilli smear, culture, or pathologic data and it is very important to look for any resistance for first-line drugs [10].

Management [11]: [Table/Fig-8,9]



[Table/Fig-8]: Pulmonary TB in pregnancy-mother likely to be infectious due to inadequate treatment duration or response.



[Table/Fig-9]: Management of Extra pulmonary TB in pregnancy.

CONCLUSION(S)

TB during pregnancy misleads the diagnosis and a late diagnosis would bring harmful maternal and fetal outcomes. Hence, any

suspicion of TB should be further evaluated, prompt diagnosis and early treatment should be initiated.

REFERENCES

- [1] Miele K, Morris SB, Tepper NK. Tuberculosis in pregnancy. *Obstetrics and Gynecology*. 2020;135(6):1444.
- [2] Sharma P, Marimuthu Y, Basu S, Sharma N, Mala YM, Nagappan B. Intensified case finding for screening tuberculosis among antenatal women in Delhi, India; A facility-based prospective observational study. *Clinical Epidemiology and Global Health*. 2021;12:100816.
- [3] Centers for Disease Control and Prevention. Core curriculum on tuberculosis: what the clinician should know. Available at: https://www.cdc.gov/tb/education/corecurr/pdf/corecurr_all.pdf. Retrieved February 17, 2020.
- [4] Lewinsohn DM, Leonard MK, LoBue PA, Cohn DL, Daley CL, Desmond E, et al. Official American Thoracic Society/Infectious Diseases Society of America/Centers for Disease Control and Prevention clinical practice guidelines: diagnosis of tuberculosis in adults and children. *Clinical Infectious Diseases*. 2017;64(2):e1-33.
- [5] Gould JM, Aronoff SC. Tuberculosis and pregnancy-maternal, fetal, and neonatal considerations. *Microbiology spectrum*. 2016;4(6):04-06.
- [6] Perez-Malagon CD, Barrera-Rodriguez R, Lopez-Gonzalez MA, Alva-Lopez LF. Diagnostic and neurological overview of brain tuberculomas: a review of literature. *Cureus*. 2021;13(12):e20133.
- [7] Konala VM, Adapa S, Agrawal N, Naramala S, Dhingra H, Aronow WS. Misdiagnosis of ileocecal tuberculosis-diagnostic dilemma with Crohn's disease. *AME Medical Journal*. 2019;4:15.
- [8] Centers for Disease Control and Prevention. TB treatment and pregnancy. Available at: <https://www.cdc.gov/tb/topic/treatment/pregnancy.htm>. Retrieved February 17, 2020.
- [9] American Academy of Pediatrics Committee on Infectious Diseases. Red book 2018-2021: report of the committee on infectious diseases. 31st ed. Elk Grove Village, IL: American Academy of Pediatrics; 2018.
- [10] Guidelines for diagnostic imaging during pregnancy and lactation. Committee Opinion No. 723. American College of Obstetricians and Gynecologists. *Obstet Gynecol* 2017;130:e210-16. [PubMed: 28937575]
- [11] <https://www.health.qld.gov.au/clinical-practice/guidelines-procedures/diseases-infection/diseases/tuberculosis/guidance/guidelines>.

PARTICULARS OF CONTRIBUTORS:

1. Postgraduate, Department of Obstetrics and Gynaecology, Bangalore Baptist Hospital, Bangalore, Karnataka, India.
2. Senior Consultant, Department of Obstetrics and Gynaecology, Bangalore Baptist Hospital, Bangalore, Karnataka, India.

NAME, ADDRESS, E-MAIL ID OF THE CORRESPONDING AUTHOR:

Annareddy Lakshmi Priya,
1/3/187/5/1, Chennareddy Colony, Pulivendula, Kadapa-516390,
Andhra Pradesh, India.
E-mail: annareddyakshmiPriyaReddy@gmail.com

PLAGIARISM CHECKING METHODS: [Jain H et al.]

- Plagiarism X-checker: Apr 13, 2022
- Manual Googling: Nov 18, 2022
- iThenticate Software: Dec 12, 2022 (8%)

ETYMOLOGY: Author Origin

AUTHOR DECLARATION:

- Financial or Other Competing Interests: None
- Was informed consent obtained from the subjects involved in the study? Yes
- For any images presented appropriate consent has been obtained from the subjects. Yes

Date of Submission: **Apr 03, 2022**
Date of Peer Review: **May 25, 2022**
Date of Acceptance: **Dec 21, 2022**
Date of Publishing: **May 01, 2023**