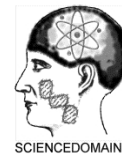

**International Journal of TROPICAL DISEASE  
& Health**  
4(2): 244-249, 2014



SCIENCEDOMAIN international  
[www.sciencedomain.org](http://www.sciencedomain.org)

---

## **Strongyloides Hyperinfection in Renal Transplant - diagnosis by Endoscopic Intestinal Biopsy**

**Desai Madhav<sup>1\*</sup>, K. Praveen Kumar<sup>1</sup>, N. Mohan Rao<sup>2</sup>  
and Y. Pavan Kumar<sup>3</sup>**

<sup>1</sup>Department of Nephrology, Narayana Medical College, Nellore, India.

<sup>2</sup>Department of Pathology, Narayana Medical College, Nellore, India.

<sup>3</sup>Department of Medical Gastro-enterology, Narayana Medical College, Nellore, India.

### **Authors' contributions**

Author DM is the main author and corresponding author, he is nephrologist, who transplanted the kidney to the patient and he is the main treating doctor/consultant. Author KPM is also nephrologist who helped in treating the patient. Author NMR is pathologist who diagnosed the strongyloides in biopsy. Author YPK is medical gastro-enterologist who performed endoscopy to the patient.

**Case Study**

**Received 26<sup>th</sup> August 2013**  
**Accepted 18<sup>th</sup> October 2013**  
**Published 13<sup>th</sup> December 2013**

---

### **ABSTRACT**

**Introduction:** Intestinal parasites continue to be a significant health problem in renal transplantation patients. Strongyloides infection is unique that it excretes larvae and can continue life cycle by auto infective cycle also.

**Presentation of the case:** We present a 26 years old man presented with acute cellular rejection after three months of kidney transplantation. Before transplantation stool of both recipient and donor was negative for parasites. He received three doses of intravenous methylprednisolone. After one month he presented with severe epigastric pain and vomiting. On examination he was malnourished, dehydrated and lost two kilograms of weight over one month. His serum albumin was 2.9 mg/dL. Pain did not subside with proton pump inhibitors. Stool examination was negative for parasites. As index of suspicion for parasites was high, upper GI endoscopy was done; it showed multiple ulcers in duodenum. Biopsy of the ulcer showed strongyloides infection He was treated with

---

\*Corresponding author: Email: [drdesaimadhav.neph@gmail.com](mailto:drdesaimadhav.neph@gmail.com);

ivermectin. Abdomen Pain was subsided soon. He gained weight of 1.5 kilograms over next month.

**Conclusion:** When transplant patients from developing country with recent increase of immunosuppression presents with severe abdomen pain, the intestinal parasitic infection should be entertained. If stool examination is negative and serology is unavailable, early evaluation by endoscopic biopsy is helpful to diagnose strongyloides. Prolonged treatment with ivermectin and follow-up stool examinations are important for complete cure of strongyloides infection.

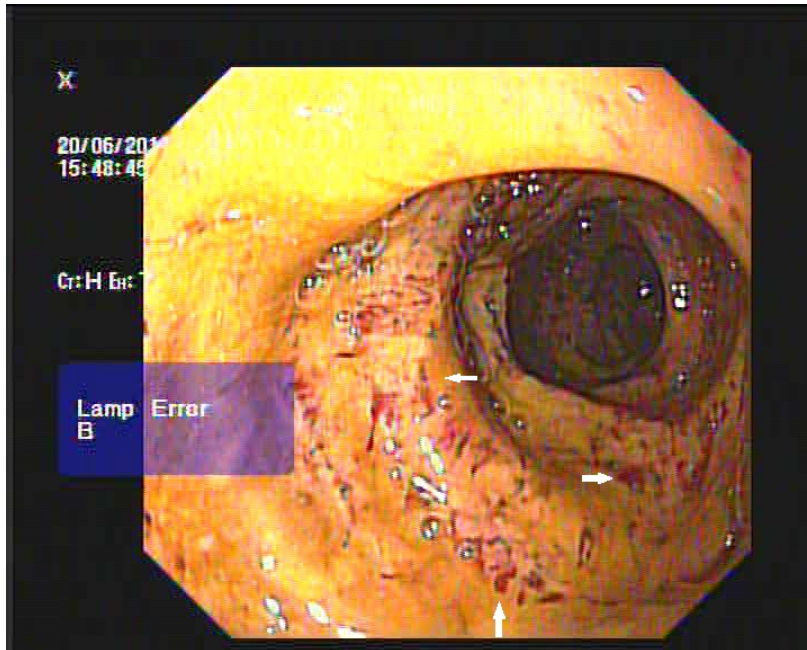
**Keywords:** *Strongyloides; intestinal ulcers; renal transplantation; stool examination; endoscopic biopsy.*

## 1. INTRODUCTION

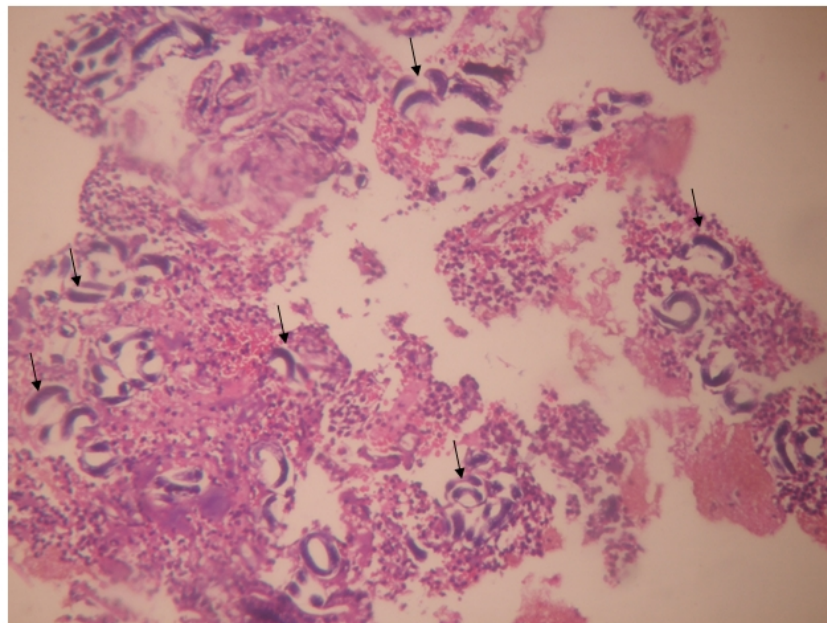
*Strongyloides stercoralis* was first identified by Normand in 1876. *Strongyloides* is an intestinal nematode, produces minimal symptoms in immunocompetent individuals, but when occur in persons with impaired T lymphocyte function, leads to life-threatening infection with 60-85% mortality rate [1]. The *Strongyloides stercoralis* excretes larvae in feces and has autoinfective cycle [2]. Only female adults are detectable in humans, and subsequent reproduction occurs asexually [3]. No direct person-to-person transmission occurs. The prevalence of strongyloides ranges from 12 to 76%. The disease is estimated to affect 100-200 million people worldwide. Gram-negative sepsis (*Escherichia coli* and *Klebsiella*) is a common consequence of hyperinfection and carries a 50% mortality rate.

### 1.1 Presentation of Case

A 26 year old man hawker with solitary kidney, end stage renal disease underwent live related renal transplantation in March, 2011. His mother was kidney donor. He was given steroids, mycophenolate sodium and tacrolimus. He had good immediate graft function. Pre-transplant routine examination of stool of both recipient and donor was negative for parasites. In May, 2011 he suffered one episode of biopsy proven acute rejection, reversed completely with three daily doses of intravenous methylprednisolone. In June, 2011 he presented with severe epigastric pain and vomiting. Pain was crampy, not radiating to back. It did not subside with injectable pantoprazole (proton pump inhibitors) and injectable antispasmodics (dicyclomine). On examination he was malnourished, dehydrated and lost two kilograms of weight over one month. His serum albumin was 2.9 mg/dL with absence of protein in urine. Stool examination was negative for strongyloides larvae. As pain persisted upper gastrointestinal scopy (Olympus- CV150 series) was done, it revealed multiple ulcers with slough seen in duodenum (Fig 1). Lesions were biopsied and sent for histopathological examination. It showed dysplastic glands with larvae of strongyloides stercoralis (Fig 2). He was treated with ivermectin 200 µg/day for 5 days and repeated after 2 weeks. Abdomen Pain was subsided soon. He gained weight of 1.5 kilograms over next month. His stool examination was negative for next 2 months.



**Fig. 1. Upper GI endoscopy – multiple ulcers seen in duodenum (arrows)**



**Fig. 2. Intestinal Biopsy showing strongyloides larvae (Arrows)**

## 2. DISCUSSION

When patient presented with severe abdomen pain after treatment of acute rejection, stool examination by wet mount test (with concentration technique) for three consecutive days was done, it was negative for parasites. He did not respond to proton pump inhibitors.

When patient presented with severe epigastric pain with vomiting the following differential diagnosis were considered and excluded by appropriate investigations - acid peptic disease, pancreatitis, biliary colic and left lobe liver abscess. As pain persisted upper GI endoscopy was done, it showed multiple duodeno-jejunal ulcers. The Differential diagnosis of ulcers include stress of surgery, steroids, mycophenolate mofetil, crohn's disease, ischemia, Zollinger-Ellison syndrome, infections (Mycobacterium, Syphilis, Typhoid, Histoplasmosis, and Cytomegalovirus), medications such as potassium, nonsteroidal anti-inflammatory drugs (NSAIDs) and rarely vasculitis. Biopsy of the ulcer showed strongyloides.

Strongyloides infection may presents as acute, chronic and hyperinfection. Strongyloides hyperinfection represents accelerated autoinfection due to alteration in immune status. The glucocorticoids can transform chronic strongyloidiasis to hyperinfection. Hyperinfection can occur with any dose of steroid and any preparation of steroid. After steroid therapy, strongyloides may present from 20 days to after many years. Cyclosporine does not associate with hyperinfection and may actually have an antihelminthic effect [4]. Exacerbation of gastrointestinal and pulmonary symptoms is seen, and the detection of increased numbers of larvae in stool and/or sputum is the hallmark of hyperinfection.

The gastro-intestinal symptoms in strongyloides infection are common but are non-specific. The gastro-intestinal symptoms includes abdominal pain [5], chronic diarrhea, constipation [5], anorexia, weight loss [5], difficulty swallowing [6], sore throat, nausea [5], vomiting, gastrointestinal bleeding and pruritus ani.

A minimum of three samples of stool is necessary to make a diagnosis of intestinal infection. As excretion of parasite can be intermittent, it is preferable that specimens be sent on different days [7]. Various stool concentration techniques and use of the Baermann method (by which motile larvae are extracted from stool specimens) may increase the diagnostic yield of fecal examination [7]. Several immunodiagnostic assays have been developed, but not readily available.

If the stool examination is negative and serology is not available endoscopy or colonoscopy is appropriate depending on the symptoms. Hussain Issa et al [8] showed that strongyloides infection was diagnosed by colonoscopic biopsy (later confirmed by stool examination) in a renal transplant patient presented with nausea, vomiting and significant loss of weight. Bobby Kakati et al [9] reported a case of strongyloides duodenitis in a patient with AIDS, presenting as abdominal pain, intractable nausea and emesis (stool examination without concentration methods were negative). Findings from upper gastrointestinal endoscopy may range from normal-appearing mucosa to severe duodenitis.

Duodenal biopsy histopathological examination identified larvae in 71.4% of immunosuppressed patients [10]. Thus, in addition to stool analysis, endoscopic observation and biopsies are very important [11]. Histopathology of the lesions may shows *Strongyloides stercoralis* larvae embedded in the mucosal lamina propria, where they produce mild to moderate degrees of edema, cellular infiltration, partial villous atrophy, and, ulcerations and fibrosis.

The goal of treatment is total eradication of the parasite, not just symptomatic improvement, as even one viable worm can initiate hyperinfection. Ivermectin is better than thiabendazole [12] and albendazole [13] in treatment of strongyloides. Ivermectin dose is 200 µg/kg/day, continue till symptoms resolve and stool tests have been negative for at least 2 weeks (one autoinfection cycle), or longer if patient remains immunosuppressed.

### **3. CONCLUSION**

When transplant patients from developing country with recent increase of immunosuppression presents with severe abdomen pain, the intestinal parasitic infection should be entertained. If stool examination is negative and serology is unavailable, early evaluation by endoscopic biopsy is helpful to diagnose strongyloides. Prolonged treatment with ivermectin and follow-up stool examinations are important for complete cure of strongyloides infection.

### **CONSENT**

All authors declare that 'written informed consent was obtained from the patient (or other approved parties) for publication of this case report and accompanying images.

### **ETHICAL APPROVAL**

Not applicable.

### **COMPETING INTERESTS**

Authors have declared that no competing interests exist.

### **REFERENCES**

1. Asdamongkol N, Pornsuriyasak P, Sungkanuparph S. Risk factors for strongyloidiasis hyperinfection and clinical outcomes. *Southeast Asian J Trop Med Public Health.* 2006;37(5):875-84.
2. Keiser PB, Nutman TB. Strongyloides stercoralis in the Immunocompromised Population. *Clinical Microbiology reviews.* 2004;17:208-17.
3. Neva FA. Intestinal nematodes of human beings; in F.A. Neva (ed): *Basic clinical parasitology.* Norwalk, Appleton & Lange. 1994;123-28.
4. Schad GA. Cyclosporine may eliminate the threat of overwhelming Strongyloides in Immunosuppressed patients. *J. Infect. Dis.* 1986;153(1):178.
5. Liepman M. Disseminated Strongyloides stercoralis. A complication of immunosuppression. *JAMA.* 1975;231:387-88.
6. Yee A, Boylen CT, Noguchi T, Klatt EC, Sharma OP. Fatal Strongyloides stercoralis infection in a patient receiving corticosteroids. *West J Med.* 1987;146:363-64.
7. Cox FEG, Derek Wakelin, Stephan H, et al. *Topley & Wilson's Microbiology & microbial infection, Parasitology, 10<sup>th</sup> edition.* Edward Arnold publishers; 2005.
8. Hussain Issa, Mohamad A Aljama, Ahmed H Al-Salem. Strongyloides stercoralis hyperinfection in a post-renal transplant patient. *Clinical and Experimental Gastroenterology.* 2011;4:269–71.
9. Bobby Kakati, Shyam Dang, Muhannad Heif, et al. Strongyloides Duodenitis: Case Report and Review of Literature. *Journal of The National Medical Association.* 2011;103(1):60-3.

10. Kishimoto K, Hokama A, Hirata T, Ihama Y, Nakamoto M, Kinjo N, Kinjo F, Fujita J. Endoscopic and histopathological study on the duodenum of *Strongyloides stercoralis* hyperinfection. *World J Gastroenterol*. 2008;14(11):1768-73.
11. Mittal S, Sagi SV, Hawari R. Strongyloidiasis: endoscopic diagnosis. *Clin Gastroenterol Hepatol*. 2009;7(2):e8.
12. Gann PH, Neva FA, Gam AA. A randomized trial of single and two-dose ivermectin versus thiabendazole for treatment of strongyloidiasis. *J Infect Dis*. 1994;169:1076-79.
13. Datry A, Hilmarsdottir A, Mayorga-Sagastume R, Lyagoubi M, Gaxotte P, Biligui S, et al. Treatment of strongyloides stercoralis infection with ivermectin compared with albendazole: results of an open study of 60 cases. *Trans R Soc Trop Med Hyg*. 1994;88(3):344-5.

---

© 2014 Madhav et al.; This is an Open Access article distributed under the terms of the Creative Commons Attribution License (<http://creativecommons.org/licenses/by/3.0>), which permits unrestricted use, distribution, and reproduction in any medium, provided the original work is properly cited.

*Peer-review history:*

*The peer review history for this paper can be accessed here:*  
<http://www.sciencedomain.org/review-history.php?iid=321&id=19&aid=2743>