

Retinoschisis in Congenital Hypopituitarism with Short Stature: A New Clinic Entity?

Sami Toyran¹, Sinan Bilgin^{1*} and Fahrettin Akay²

¹Department of Ophthalmology, Sifa University, Turkey.

²Department of Ophthalmology, Izmir Military Hospital, Turkey.

Authors' contributions

This work was carried out in collaboration between all authors. Authors ST and SB designed the study and wrote the first draft of the manuscript. Author FA managed the literature searches. All authors read and approved the final manuscript.

Article Information

DOI: 10.9734/BJMMR/2016/27379

Editor(s):

(1) Barbara Giambene, Eye Clinic, Department of Translational Surgery and Medicine, University of Firenze, Italy.

Reviewers:

(1) Gabor Nemeth, University Teaching Hospital, Miskolc, Hungary.
(2) Sagili Chandrasekhara Reddy, National Defence University of Malaysia, Malaysia.
Complete Peer review History: <http://www.sciencedomain.org/review-history/15529>

Case Study

Received 30th May 2016
Accepted 1st July 2016
Published 26th July 2016

ABSTRACT

Herein we report a short stature man with unilateral retinoschisis associated with optic disc anomaly. The patient presented to our clinic after 5 years of gradually decreased vision in his right eye. He had flat retinoschisis with large round-shape break of the inner retinal layer in the right eye. There was also perifoveal retinoschisis. Fundus examination revealed peripapillary chorioretinal atrophy, tilted and hypoplastic optic disc, 'frosted branch' or 'dragged' appearance of temporal retinal vessels. SD-OCT revealed an unusual entity of retinoschisis likely connected to the optic disc anomaly. Our case does not show previously reported characteristics of the eye involvement with syndromic short stature, and may represent a new clinical entity.

Keywords: Growth hormone deficiency; retinoschisis; short stature; optic disc anomaly.

*Corresponding author: E-mail: drsinanbilgin@yahoo.com;

1. INTRODUCTION

Retinoschisis is a retinal dystrophy and the leading cause of retinal degeneration in young males. Peripapillary and macular retinoschisis are usually associated with optic disc anomalies [1-4]. Congenital retinoschisis is characterized by bilateral macular involvement in the first decade of life. The clinical diagnosis of congenital retinoschisis is based on fundus findings and electrophysiologic examination. Spectral domain optical coherence tomography (SD-OCT) shows cystic-appearing spaces in the perifoveal area in younger patients [4].

Herein we report an unusual case of unilateral peripapillary and peripheral retinoschisis with optic disc anomaly in short stature boy. To the best of our knowledge, this is the first case of unilateral retinoschisis in a patient associated with isolated growth hormone (GH) deficiency.

2. PRESENTATION OF CASE

Twenty years old patient with short stature referred to our clinic for progressive decrease of vision in right eye since five years ago. The patient was on GH therapy for 10 years intermittently because of GH deficiency.

At birth, it was noted that the case had brachycephaly, hypertelorism, syndactyly (hands and feet bilaterally) and cryptorchidism. There was no history of seizures, vomiting, or psychomotor regression. Hearing evaluated by audiometry was normal. He had no abnormal mental function or any focal neurological deficit including eye movements. No abnormal findings were noted in the electrocardiogram. Chromosomal studies of the peripherally

mphocyte cultures revealed a 46,XY normal male karyotype.

Biochemical and endocrinological (FSH, LH, TSH, ACTH) examinations did not reveal any abnormalities. GH stimulation tests were performed and showed a reduced response. Bone age was assessed according to the Greulich and Pyle method [5] and it was delayed. His bone age was 19 versus a chronological age of 20 years at now.

The best-corrected visual acuity was 3/10 (Snellen equivalent, 20/63) in the right eye and 10/10 (Snellen equivalent, 20/20) in the left eye with no change on manifest refraction. Anterior segment examination was unremarkable. Stereoscopic slit-lamp examination of fundus revealed peripapillary chorioretinal atrophy, tilted and hypoplastic optic disc, 'frosted branch' or 'dragged' appearance of temporal retinal vessels and retinoschisis in temporal region of the macular area in the right eye (Fig. 1a). A large round-shaped defect was also noted in the nerve fibre layer in the right eye temporally (Fig. 1b). The left eye was normal (Fig. 1c).

SD-OCT (retina scan, RS 3000, Nidek, Gamagori, Japan) confirmed the diagnosis. Splitting of the retina at the level of outer plexiform layer (OPL) in the peripapillary, perifoveal and temporal area was demonstrated in the right eye. Also a large hyporeflective detached cystic cavity bridged by inner retina layer was detected. Perifoveal schisis in OPL extended up to optic disc. Inner segment–outer segment junction was disrupted (Fig. 2a). The left eye was normal (Fig. 2b). The inner layer of the peripapillary inferior temporal retina across retinal vessels was thick, elevated and disrupted (Fig. 2c). However, retinal pigment epithelium and choroid seemed intact along whole retina.

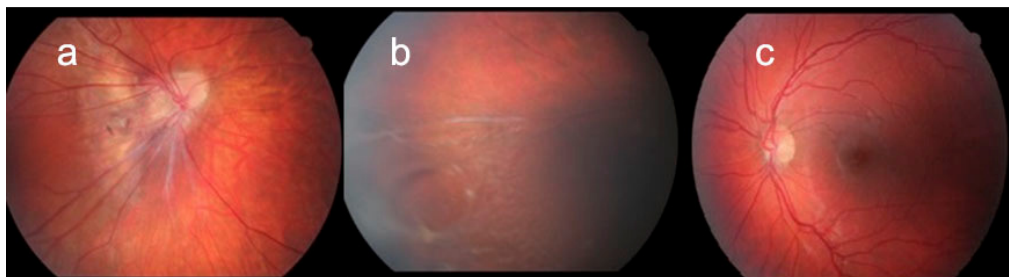


Fig. 1. Colour fundus photographs of the eyes. The case shows peripapillary chorioretinal atrophy, tilted and hypoplastic optic disc, 'frosted branch' or 'dragged' appearance of temporal retinal vessels in the right eye (Fig. 1a). Retinoschisis, a large round-shaped defect in temporal region of the macular area in the right eye (Fig.1b). The left fundus is normal. (Fig. 1c)

Brain MRI of the hypophyseal region showed the presence of a pituitary hypoplasia (height 2.5 mm and width 3.1 mm). Suprasellar cistern protruded into the cella cavity. Another abnormality was not observed.

3. DISCUSSION

We observed novel findings of the eye that congenital hypopituitarism with isolated GH deficiency has not been defined up to date. GH deficiency may be either alone or in conjunction with other pituitary hormone deficiencies. Male patients may have a small penis (microphallus), cryptorchidism and hypoglycemia. So patients should be evaluated for hypopituitarism if there is evidence of growth failure. These findings are consistent with our male case with genital anomaly, like cryptorchidism. Many syndromes including hypopituitarism and eye (optic disc, retina, choroid) involvement have been described (Table 1) [6-12].

But retinoschisis and optic disc anomaly with GH deficiency have not been described so far.

Regarding management of such conditions, Schulman et al. [13] reported two patients with congenital retinoschisis developed rhegmatogenous retinal detachments with either a tractional component or associated vitreous haemorrhage. They emphasized that vitrectomy may be indicated for some patients with retinoschisis. Additionally, in a study conducted by Yu et al. [14] in the nonsurgical group, progressively extension of retinal schisis area, retinal detachment, vitreous hemorrhage, and also deterioration in visual acuity were observed. Yu and colleagues reported that vitrectomy may be an effective and essential treatment for patients with progressive retinoschisis to prevent a deterioration of vision before severe complications developed in their eyes.

Our patient had history of gradually decreasing poor vision, so we referred to retina clinic for possible medical or surgical procedure. During the six month follow up period, visual acuity and concomitant clinical findings did not change in both eyes. Any surgical intervention was not performed.

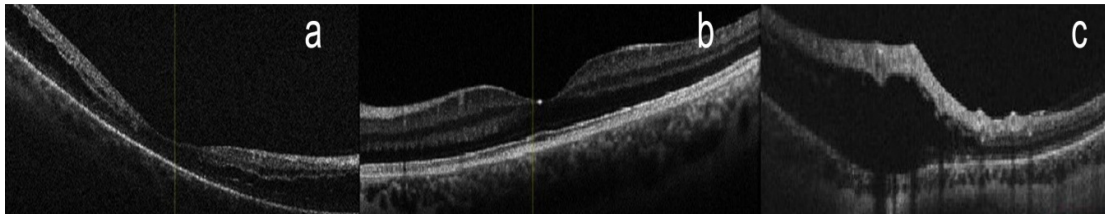


Fig. 2. SD-OCT shows splitting of the retina at the level of outer plexiform layer in the peripapillary, perifoveal and temporal area in the right eye (Fig. 2a) compared to left eye (Fig. 2b). The inner layer of the peripapillary inferior temporal retina across retinal vessels is thick, elevated and disrupted (Fig. 2c)

Table 1. Reported syndromes including hypopituitarism and eye (optic disc, retina, choroid) involvement

Hashimoto et al. [6]	Moebius syndrome with pituitary dwarfism, GH deficiency and unilateral hypoplastic optic disc
Guerra-Junior G et al. [7]	Morning glory syndrome and short stature due to growth hormone deficiency associated with hypopituitarism
Declerc A et al. [8]	Subtle central nervous system abnormalities with the advent of MRI in septo-optic dysplasia or 'de Morsier' syndrome
Menon RK et al. [9]	Choroideremia with hypopituitarism and neurological abnormalities
Tuft SJ et al. [10]	A basal encephalocele, endocrine dysfunction with dysplastic optic disc and hypopituitary dwarfism
Pozsonyi J et al. [11]	Absent or impaired pituitary hormone secretion associated with intrauterine growth retardation, and degeneration of the retina
Ishihara M [12]	Bilateral optic hypoplasia and pituitary dwarfism. (deficiency in GH, ACTH, TSH, PRL, LH and FSH)

4. CONCLUSION

This case suggests the necessity to screen all patients with pituitary dysfunction associated with eye involvement at regular intervals. Early recognition of the syndromic entities is important in view of the possibility of treating low vision in all children with growth retardation.

CONSENT

All authors declare that written informed consent was obtained from the patient for publication of this case report and accompanying images.

ETHICAL APPROVAL

It is not applicable.

COMPETING INTERESTS

Authors have declared that no competing interests exist.

REFERENCES

1. Yoshikawa T, Nishimura T, Minamino K, Takahashi K. A long-term follow-up of peripapillary retinoschisis with optic disc hypoplasia. *Int Ophthalmol*. 2013;33(4):425-8.
2. Song IS, Shin JW, Shin YW, Uhm KB. Optic disc pit with peripapillary retinoschisis presenting as a localized retinal nerve fiber layer defect. *Korean J Ophthalmol*. 2011;25(6):455-8.
3. Hsu CL, Layton CJ. Familial disorders of the optic disc: Presentation of a mother and daughter and review of the literature. *Case Rep Ophthalmol*. 2015;6(2):251-9.
4. Gregori NZ, Lam BL, Gregori G, Ranganathan S, Stone EM, Morante A, Abukhalil F, Aroucha PR. Wide-field spectral-domain optical coherence tomography in patients and carriers of X-linked retinoschisis. *Ophthalmology*. 2013;120(1):169-74.
5. Greulich WW, Pyle SI. Radiographic atlas of skeletal development of the hand and wrist, 2nd ed. Stanford, CA: Stanford University Press; 1959.
6. Hashimoto N, Sakakihara Y, Miki Y, Kagawa J, Egi S, Kamoshita S. Moebius syndrome associated with pituitary dwarfism and hypoplastic optic disc. *Acta Paediatr Jpn*. 1993;35(2):144-7.
7. Guerra-Junior G, Spinola-Castro AM, Siviero-Miachon AA, et al. Absence of mutations in Pax6 gene in three cases of morning glory syndrome associated with isolated growth hormone deficiency. *Arq Bras Endocrinol Metabol*. 2008;52:1221-7.
8. Declerck A, Casteels I, Demaerel P, Dralands L. Septo-optic dysplasia. *Bull Soc Belge Ophtalmol*. 1994;254:157-61.
9. Menon RK, Ball WS, Sperling MA. Choroideremia and hypopituitarism: An association. *Am J Med Genet*. 1989;34(4):511-3.
10. Tuft SJ, Clemett RS. Dysplastic optic discs in association with transsphenoidal encephalocele and hypopituitary dwarfism: A case report. *Aust J Ophthalmol*. 1983;11(4):309-13.
11. Pozsonyi J, Friesen H. Growth hormone investigation in patients with mental dysfunction. *Can Med Assoc J*. 1971;104(1):26-9.
12. Ishihara M. Optic hypoplasia with pituitary dwarfism (Kaplan-Grumbach-Hoyt syndrome, or DeMorsier syndrome). *Endocrinol Jpn*. 1983;30(1):7-14.
13. Schulman J, Peyman GA, Jednock N, Larson B. Indications for vitrectomy in congenital retinoschisis. *Br J Ophthalmol*. 1985;69(7):482-6.
14. Yu H, Li T, Luo Y, Yu S, Li S, Lei L, Li J, Ding X, Yuan L, Tang S. Long-term outcomes of vitrectomy for progressive X-linked retinoschisis. *Am J Ophthalmol*. 2012;154(2):394-402.

© 2016 Toyran et al.; This is an Open Access article distributed under the terms of the Creative Commons Attribution License (<http://creativecommons.org/licenses/by/4.0>), which permits unrestricted use, distribution, and reproduction in any medium, provided the original work is properly cited.

Peer-review history:

The peer review history for this paper can be accessed here:

<http://sciedomain.org/review-history/15529>