



My Experience with Levator Resection Surgery in Congenital Ptosis

Shubha Ghonsikar/Jhavar^{1*}, Ranjana Bindu¹ and Vilas Wangikar¹

¹Department of Ophthalmology, Government Medical College, Aurangabad, India.

Authors' contributions

This work was carried out in collaboration between all authors. Author SGJ designed the study, wrote the protocol and wrote the first draft of the manuscript. Authors RB and VW managed the literature searches. All authors read and approved the final manuscript.

Article Information

DOI: 10.9734/OR/2016/24972

Editor(s):

(1) Li Wang, Department of Ophthalmology, Cullen Eye Institute, Baylor College of Medicine, USA.

Reviewers:

- (1) Tsung-Jen Wang, Taipei Medical University Hospital, Taiwan.
- (2) Sagili Chandrasekhara Reddy, National Defence University of Malaysia, Malaysia.
- (3) Seydi Okumus, Gaziantep University Medical School, Turkey.
- (4) Ernesto Moretti, Universidad Abierta Interamericana, Argentina.

Complete Peer review History: <http://sciencedomain.org/review-history/13891>

Original Research Article

Received 10th February 2016
Accepted 15th March 2016
Published 28th March 2016

ABSTRACT

Aims: To assess the effectiveness of Levator resection surgery in patients with moderate to severe congenital ptosis with poor Levator function.

Materials and Methods: Settings and Design: A prospective, observational, single institutional study done in 2003-2010 at a referral Government College draining poor patients.

52 eyes of 49 pts with moderate to severe ptosis were selected. All had poor Levator Palpebrae Superioris (LPS) action. Marcus Gunn ptosis and Acquired Ptosis were excluded. These underwent Levator resection surgery through skin approach. LPS was resected according to severity of ptosis. Postoperative ptosis correction, lid position, contour, lid lag and any other complications were noted. Results of ptosis correction were grouped as:

1. Good if postop. Lid height was within 1 mm of the desired height or with respect to the opposite lid.
2. Satisfactory if 1-2 mm undercorrection was seen.
3. Poor if > 2 mm undercorrection occurred or any other cosmetic blemish like lagophthalmos, notching of lid border or abnormal lid fold.

Follow up was done at 1 wk, 6 wks, 6 mths, then yearly till 5 years.

*Corresponding author: E-mail: shubhajhavar@gmail.com;

Results: 43 eyes (82.69%) showed good correction, with good primary eye lid position and no corneal complications.
7 eyes (13.46%) showed satisfactory correction.
2 eyes (3.84%) showed poor correction. 1- overcorrection, 1- undercorrection
Conclusions: Levator resection surgery is an effective procedure of choice even for congenital ptosis with poor LPS action.

Keywords: Congenital ptosis; Levator Palpebrae Superioris; levator resection.

1. INTRODUCTION

Congenital Ptosis is the abnormal drooping of the upper eyelid since birth. This cosmetic blemish poses a challenge to ophthalmic surgeons. Management of severe congenital ptosis with minimum to poor levator action is controversial. Brow suspension – Unilateral/Bilateral, and Levator Palpebrae Superioris (LPS) resection are various options.

Our objective was to study the results of LPS resection surgery in congenital simple ptosis with poor LPS action.

2. SUBJECTS AND METHODS

Patients having moderate to severe congenital simple Ptosis, a total 49 patients were selected for the study. It was a prospective observational study. The Institutional Ethics committee permitted for the study. Marcus Gunn Ptosis and Acquired Ptosis were not included. A thorough history was recorded from the patient or the parent.

History included-Time of onset of ptosis, any h/o birth/injury/illness, any h/o improvement or worsening, h/o any previous eye/other surgery.

Examination included inspecting whether ptosis was unilateral or bilateral. Function of orbicularis muscle was assessed by having the patient open and close his eyes. Presence or absence of upper lid crease and fold were noted, even a faint lid crease when the patient looks upward, indicated some degree of levator action. The height of lid crease on the normal side was measured and compared to that of ptotic eyelid.

The degree of ptosis was noted by noting the position of the ptotic lid margin with respect to the limbus and the pupil. This was noted when the eye was in upgaze, downgaze and primary gaze.

Normal palpebral aperture =9-10 mm in primary gaze.

Amount of ptosis = difference in palpebral apertures in unilateral ptosis.

OR difference from normal in bilateral ptosis.

MRD1= margin reflex distance, normal 4-5 mm.

Ptosis was moderate if lid drooped 3 mm and severe if it drooped 4 mm or more.

Levator function was measured by Berke's method. Lid excursion from extreme downgaze to extreme upgaze after frontalis action was eliminated by pressing the thumb tightly over the upper brow in mm.

Poor levator function was 0-5 mm, Fair levator function was 5-8 mm, Good levator function was 8 mm or more, and 13 – 17 mm lid excursion was considered normal.

Extraocular muscle function, particularly of Superior Rectus (SR) was noted. Bell's phenomenon, Corneal sensations were noted. Vision uncorrected and best corrected was recorded. Conjunctiva and Fundi were examined. Blood investigations and Anaesthesia fitness was done. Proper consent taken, after realistic goals and expectations were set with the patients and the parents.

3. PROCEDURE

Under standby/general anaesthesia, Levator resection was carried out with skin approach. Lid crease was marked. Lid guard was inserted – upper lid made taut and eyeball protected. Incision was made at the crease, Orbicularis was split. Lower skin incision was undermined, Tarsus cleaned. Upper skin was undermined. Orbital septum was identified, separated, and prolapsed fat retracted. The underneath Levator fibres (LPS aponeurosis) was identified. Local anaesthetic was injected between conjunctiva and LPS. LPS cut from insertion on anterior surface of tarsus. LPS belly dissected from conjunctiva, marked, measured with Vernier's

callipers and cut depending on severity of ptosis. Three vicryl 6-0 sutures were passed and sutured to tarsus, care being taken to maintain a good lid contour. Excess skin was excised if required. Lid crease forming sutures applied to skin and LPS. Frost suture applied to lift the lower lid. Antibiotic eye ointment and patch applied. First dressing was done in 24 hrs. Artificial tear drops were instilled hourly by day and ointment at night.

On the fifth day, traction suture in lower lid was removed after lid action was resumed. Follow up was done at 1 wk, 6 wks, 6 mths and 1 yr. Postoperative - Ptosis correction, lid position, contour, lidlag and any other complications were noted.

Results of ptosis correction were grouped as:

1. Good if postop. lid height was within 1 mm. of the desired height or with respect to the opposite lid.
2. Satisfactory if 1-2 mm. undercorrection was seen.
3. Poor if > 2 mm undercorrection occurred or any other cosmetic blemish like lagophthalmos, notching of lid border or abnormal lid fold was seen.

4. RESULTS

49 patients had congenital simple ptosis. 46 patients had unilateral congenital ptosis. 3 of them had bilateral congenital ptosis.

In all 52 eyes were operated upon. Moderate ptosis was seen in 38 eyes. Severe ptosis was seen in 14 eyes. All had poor LPS action—nil to 5 mm.

4.1 Age Grps

There were 4 patients less than 10 years of age, 41 patients in 10-25 years age group, and 4 patients in 25-50 years of age. The mean age was 19.5 years

4.2 Sex Ratio

26 patients were males and 23 were females.

Preoperatively 2 patients had some kind of small surgery, probably Fasanella Servat done in a plastic surgery camp. 1 patient had a conjunctival suture cyst with abscess.

Table 1. Severity of ptosis

52 eyes were operated upon.

Severity	Eyes	LPS resection done
Moderate ptosis	38	22-25 mm
Severe ptosis	14	24-27 mm

The amount of LPS resection was decided depending on severity of ptosis. For Severe ptosis 24-27 mm LPS was resected and for Moderate ptosis. 22-25 mm LPS was resected.

Postop. results were very encouraging. 43 eyes (82.69%) showed good correction. 7 eyes (13.46%) showed satisfactory correction. 2 cases showed minor temporal lid drooping. One young male had some fluid collection repeatedly at the stitch site, which was given hot compresses, antibiotics and was drained. One had minor trichiasis, the lashes were directed down. Early lidlag was observed in patients with large resection which was not seen later.

Two eyes (3.84%) showed poor correction, 1 had undercorrection seen after 6 mths., this patient had unilateral congenital moderate ptosis with 3 mm. LPS action, the muscle was re-resected, 1 had overcorrection for which marginal myectomies were done and the muscle relaxed, thus lid was corrected.

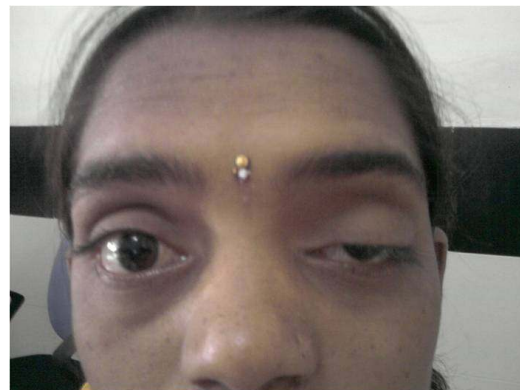


Fig. 1. (LE) severe ptosis with nil LPS

5. DISCUSSION

Management of unilateral moderate to severe congenital ptosis with nil to poor levator action is controversial. Ideal ptosis surgery should be both anatomically and physiologically acceptable without endangering the vision.

Perfect postop. result should be a more normal symmetrical lift of upper lid, adequate mobility when blinking, a normal good lid contour and fold, no diplopia or any sight threatening complications, and a complete cover of eye on lid closure.

True Congenital ptosis occurs from levator muscle dystrophy.

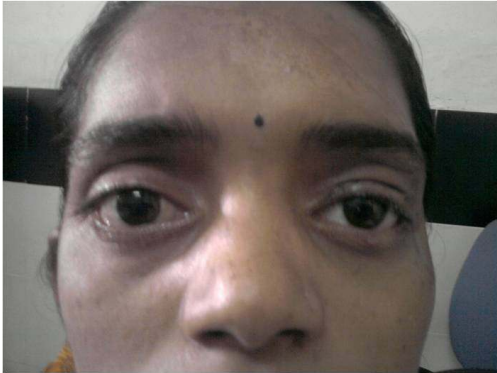


Fig. 2. Postop corrected (LE)

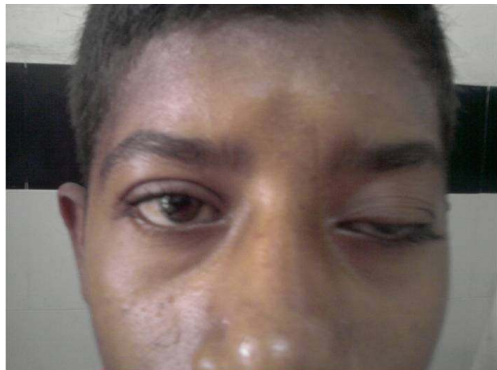


Fig. 3. (LE) Severe ptosis with 2 mm LPS

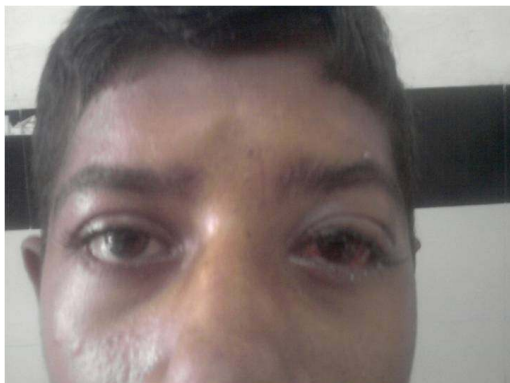


Fig. 4. Postop corrected (LE)

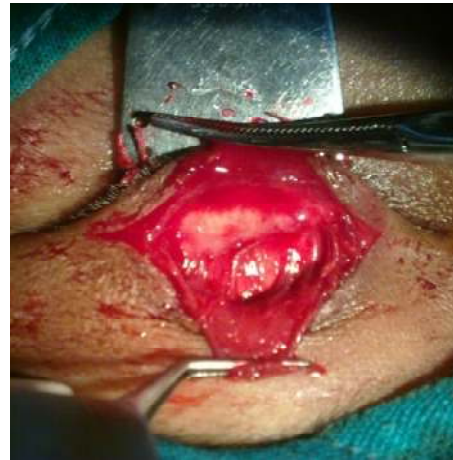

Fig. 5. Dissected levator muscle

Unilateral Brow suspension is the treatment of choice by many. Bilateral Brow suspension after excision of Levator on normal side also done for more symmetric results.

Brow suspension procedures produce cosmetically disfiguring results due to unilateral lidlag in downgaze and ptosis on upgaze. The lid remaining open in sleep also worries the patient. Relative immobility of upperlid is a constant defect. Brow suspension with nonabsorbable sutures caused infection and granuloma formation and cicatricial bands formed at suture sites. Gradual recurrences of ptosis were also reported. Hence, we undertook LPS resection in severe ptosis with poor LPS action too.

Blaskovics (1923), Illiff (1954), Berke (1959), Jones (1975) studied levator resection and proved it to be effective [1].

When the LPS muscle is present, the most reasonable and physiological operation is to shorten it by partial resection. This gives the best functional and cosmetic result [2,3,4,5]. Maximum levator resections could be performed easily with external approach surgery. This also preserved tear producing structures and mullers muscle [6,7].

In a similar study, Abdulla Mujaini et al. [8] treated 7 patients successfully with no complications and recommended this as an ideal procedure.

Press UP, et al. [9] in their study on 44 patients, showed good results in 81.81% and concluded that maximal levator resection is the treatment of

choice in congenital ptosis with poor LPS function.

Mete A, Cruz AA, Mauriello JA, Epstein GA, in their studies also gave successful cosmetic and functional results with maximal Levator resection for primary congenital ptosis with poor levator function [10-13].

Goncu T, et al. [14] studied 32 patients with severe congenital ptosis and reported 78.6% overall success rate and concluded that levator resection surgery resulted in a substantial improvement of postop levator muscle functioning which might have an additive effect on the surgical success especially for those with poor levator function.

Andalib et al. [15] studied 7 patients and also concluded that total levator aponeurosis resection is an effective tool in elevating ptotic lids with poor levator function.

Our study had a comparable, similar encouraging result in a larger sample size. Success rate was 82.69%. We also did levator resection in bilateral congenital ptosis with very satisfying results. Proper dissection of the LPS muscle and its resection with severing of medial and lateral horns was important for effective results. Correct placement of sutures on the tarsal plate took care of the lid contour.

No sight threatening complication was noted.

Our study shows that even moderate to severe unilateral/bilateral congenital ptosis can be operated for levator resection surgery irrespective of poor levator action giving good cosmetic result, good eyelid movement and closure without compromising corneal protection and is the most physiological operation.

6. CONCLUSION

LPS resection is an effective procedure of choice even for congenital ptosis with poor LPS action.

COMPETING INTERESTS

Authors have declared that no competing interests exist.

REFERENCES

1. Berke RN. Results of resection of the levator muscle through a skin incision in

congenital ptosis. Arch. of Ophthalmol. 1959;61(2):177-80.

2. Jordan DR, Anderson RL. The aponeurotic approach to congenital ptosis. Ophthalmic Surg. 1990;21(4):237-44.
3. Allard FD, Durairaj VD. Current techniques in surgical correction of congenital ptosis. Middle East Afr J Ophthalmol. 2010; 17(2):129-33.
4. Jones LT, Quickert MH, et al. Aponeurotic Repair Arch Ophthalmol.1975;8:629-34.
5. Finsterer J. Ptosis: Causes, presentation and management. J Aesthetic Plast Surg. 2003;27:193-204.
6. Nirankari MS, Khanna KK, et al. Levator resection in ptosis, how much and How? Indian J Ophthalmol. 1973;21:95-7.
7. Mustarde JC. Correction of ptosis by split level lid resection. Clin Plas Surg. 1978;5:533-5.
8. Abdullah Al- Mujaini, Upender K. Wali. Total levator aponeurosis resection for primary congenital ptosis with very poor levator function. Oman J Ophthalmol. 2010;3(3):122-125
9. Press UP, Hubner H. Maximal levator resection in the treatment of unilateral congenital ptosis with poor levator function. Orbit. 200;20(2):125-129.
10. Mete A, Cagatay HH, et al. Maximal levator muscle resection for primary congenital blepharoptosis with poor Levator function. Semin. Ophthalmol. 2015;4:1-6.
11. Cruz AA, Akaishi PM, et al. Supramaximal levator resection for unilateral congenital ptosis: Cosmaetic and functional results. Ophthal Plast Reconstru Surg. 2014; 30(5):366-71.
12. Mauriello JA, Wagener RS, et al. Treatment of congenital ptosis by maximal levator resection. Ophthalmology. 1986; 93(4):466-9.
13. Epstein GA, Putterman AM Supermaximum levator resection for severe unilateral congenital blepharoptosis. Ophthalmic Surg. 1984; 15(12):971-9.
14. Goncu T, Cakmak S, et al. Improvement in levator function after anterior levator resection for the treatment of congenital Ptosis. Ophthal Plast Reconstr Surg. 2015;31(3):197-201.

15. Andalib D, Davood Gharebhagi, Reza Nabie, Nassim Taghaddosifar. The outcome and Influential factors involved in levator resection for Blepharoptosis correction. Iranian J. Of Ophthalmol. 2010;22(2):63-66.

© 2016 Jhavar et al.; This is an Open Access article distributed under the terms of the Creative Commons Attribution License (<http://creativecommons.org/licenses/by/4.0>), which permits unrestricted use, distribution, and reproduction in any medium, provided the original work is properly cited.

Peer-review history:

*The peer review history for this paper can be accessed here:
<http://sciencedomain.org/review-history/13891>*