



A Comparative Radiological Evaluation of the Condylar Position in Pre and Post Bilateral Sagittal Split Osteotomy

Shifa^{a+++*} and Joyce P. Sequeira^{a#}

^a Department of Oral and Maxillofacial Surgery, Yenepoya Deemed to be University, Yenepoya Dental College and Hospital Deralakatte, Mangalore, India.

Authors' contributions

This work was carried out in collaboration between both authors. Both authors read and approved the final manuscript.

Article Information

Open Peer Review History:

This journal follows the Advanced Open Peer Review policy. Identity of the Reviewers, Editor(s) and additional Reviewers, peer review comments, different versions of the manuscript, comments of the editors, etc are available here: <https://www.sdiarticle5.com/review-history/97958>

Original Research Article

Received: 17/01/2023

Accepted: 21/03/2023

Published: 22/03/2023

ABSTRACT

Purpose: Several procedures have been described for correction of Orthognathic deformities of the mandible. Currently, the Bilateral Sagittal Split Osteotomy (BSSO) maintains its popularity because of its versatility and its amenability to rigid fixation techniques. Postoperative change in the position of the condyle can be classified, using radiographs, as either physiological condylar remodelling (CR) or pathological condylar resorption (PCR) according to the severity of the observed change in condylar morphology, which demonstrates a significant relation between condylar volume loss and skeletal relapse after Bilateral sagittal split osteotomy. The present study was conducted to evaluate the changes in the condylar position following Bilateral Sagittal Split Osteotomy using lateral cephalograms and to quantify the amount of displacement of the condyle.

Methods: Ten patients who needed Bilateral Sagittal Split Osteotomy for mandibular advancement and setback with a mean age group of 20 from January 2017 to September 2018 were included in the study. The standardized Bilateral Sagittal Split Osteotomy procedure was carried out under general anaesthesia. Lateral cephalograms were taken preoperative, immediate post-operative,

⁺⁺ Lecturer;

[#] Professor and Head of Department;

^{*}Corresponding author: Email: amina.shifaiqbal@gmail.com;

after 1 month and 3 months to evaluate the condylar position. Movement of condyles is assessed in which horizontal (i.e anterior and posterior) and vertical (i.e superior and inferior) change in the position was evaluated using lateral cephalogram superimposition method.

Results: There is no statistically significant movement of condyles however there was movement of the condyles in horizontal and vertical dimensions at the immediate post operative period, one month and third month postoperative period.

Conclusion: Eventhough there is no statistically significant movement of condyles, there is change in movement of condyles in the insignificant ratio. However, larger sample size and larger follow up period is required to achieve a conclusive results.

Keywords: Condylar Sag; bilateral sagittal split osteotomy; lateral cephalogram.

1. INTRODUCTION

Sagittal Split Osteotomy was first introduced by Schuchardt in 1954, but the most important outbreak in the surgical correction of severe skeletal class III malocclusion by “Bilateral Sagittal Split Osteotomy” was developed by Trauner and Obwegeser in 1957. It was later modified by Dalpoint (1961), Hunsuck (1968), Gallo et al. (1976), and Epker (1977) [1].

Bilateral Sagittal Split Osteotomy (BSSO) is the most favoured surgical procedure used for the three dimensional reorientation of mandible in the skeletal jaw deformities. Many surgeons preferably use this procedure because of a wider range of advantages, a quick recovery, and a higher degree of occlusal stability. Post operative occlusal stability has been an important factor following BSSO. Current literature reveals that stability after sagittal split osteotomy directly related to the preoperative condylar position, magnitude of movement, muscle tension and methods of fixation [2].

Many factors which can affect post surgical stability includes changes in the position of the mandibular condyles, proximity of the osteotomised bony cuts, inter maxillary immobilization period, amount and direction of the movement of the mandible. Among these, the altered position of the condyles has been believed to be a critical factors causing postoperative instability in connection with occlusion, which may further lead to complications that may range from immediate post operative relapse to degenerative changes in the condyle [3].

Positional changes in the condyle are difficult to identify and even harder to predict following orthognathic surgery of the mandible. It is evident that orthognathic surgery involves complex positional changes of the condyle that

need to be assessed in a systematic manner [4,5]. Displacement of the condyle can be expected in the following directions: horizontal (i.e anterior and posterior) and vertical (i.e superior and inferior) which can be accessed using various radiological modalities [6,7].

The purpose of this study is to evaluate the changes in position of the condyle following bilateral sagittal split osteotomy with lateral cephalograms in horizontal and vertical dimensions.

1.1 Aims and Objectives

- To evaluate the changes in the condylar position following Bilateral Sagittal Split Osteotomy using lateralcephalograms.
- To quantify the amount of displacement of the condyles following Bilateral Sagittal Split Osteotomy in twodimensions.

2. METHODOLOGY

2.1 Study Design

The subjects for the present study were selected from among ten patients who had undergone BSSO for mandibular advancement and setbacks during the period of 2016 to 2018.The standardized Bilateral Sagittal Split Osteotomy procedure was carried out under general anaesthesia at Yenepoya Dental College Hospital. Surgery was performed by the senior faculty of the department. The study was approved by the institutional review board and informed consent was obtained prior to their enrollment in the study.

Lateral cephalograms were taken pre- operative, immediate post-operative, 1 month and 3 months post surgically to evaluate the condylar position. The cephalograms were taken using the same machine with the subjects standing upright and

trying to assume the same natural position of the head with lips relaxed. Lateral cephalograms were taken in occlusion under standard conditions with a cephalostat.

The change in position of the condyle from pre-operative to the immediate post-operative, 1 month post-operative and 3 months post-operative is measured using lateral cephalograms super imposition method. The cephalometric analysis was carried out using the reference points and lines mentioned below.

2.2 Analysis of Lateral Cephalograms

Four lateral cephalograms were taken one at each of the following periods consisting of pre-operative (T1), immediate post-operative (T2), one month post-operative (T3) and three months post-operative (T4). Each post-operative

cephalometric radiographs were traced and superimposed to the pre-operative cephalometric radiograph using following stable linear measurements on the cranial base such as sella-nasion line and seven degree parallel line drawn from the sella-nasion line [8].

The position of the condylion point of the post-operative cephalometric tracings were transferred the pre-operative cephalometric radiographic tracing using super imposition of the post-operative cephalometric tracings to the pre-operative cephalometric tracing.

The movement of condylion point from the pre-operative radiographic tracings (T1) to the immediate post-operative (T2), one month post-operative (T3) and third month post-operative (T4) is measured in antero-posterior and superior-inferior directions.

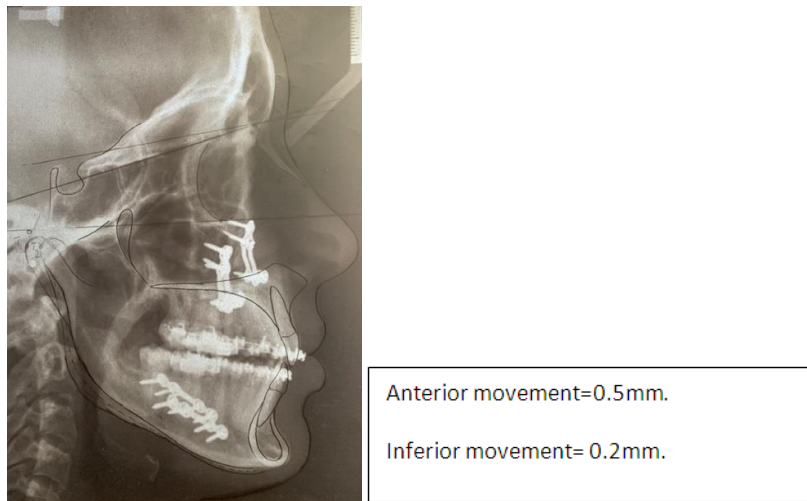


Fig. 1. Analysis of lateral cephalogram at immediate post operativeperiod

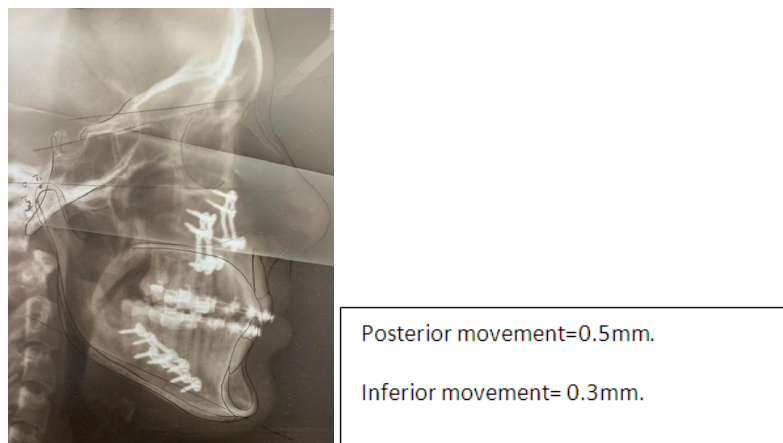


Fig. 2. Analysis of lateral cephalogram at one month post operativeperiod

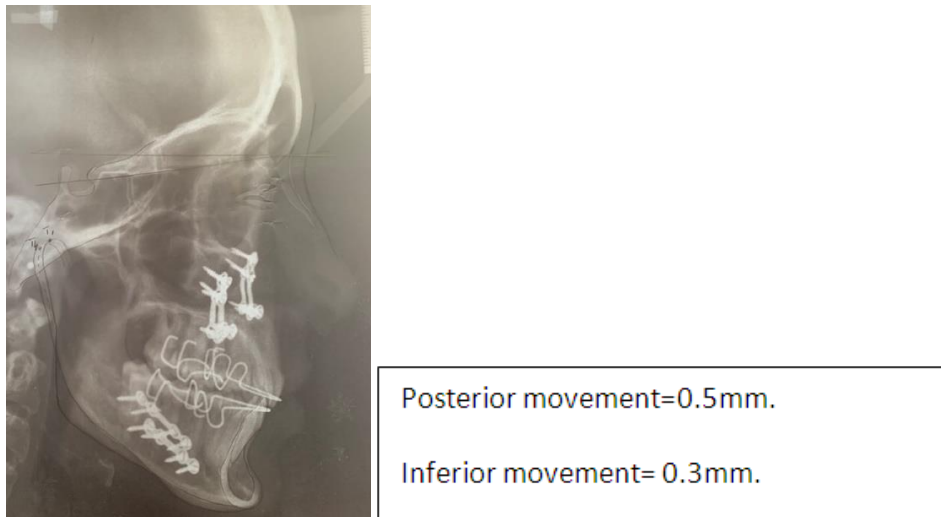


Fig. 3. Analysis of lateral cephalogram at third month post operativeperiod

3. RESULTS

A total number of ten patients were enrolled in the study who were randomly allocated into two groups. Lateral cephalograms were taken pre-operative, immediate post-operative, one month and three months post surgically to evaluate the condylar position.

3.1 Analysis of Position of Condyles Using Lateral Cephalograms

Table 1. Movement of condyle following Bilateral Sagittal Split Osteotomy in antero posterior andsuperior-inferior directions

Immediate Post OP (T1)(mm)		1 ST Month Post OP(T2) (mm)		3 RD Month Post OP(T3)(mm)	
Horizontal	Vertical	Horizontal	Vertical	Horizontal	Vertical
0.4	-0.2	-0.3	-0.8	-0.8	+0.2
-0.3	+0.2	0.3	0.2	0.3	0.2
0.4	0.3	0.5	0.4	0.4	0.4
-0.9	0.3	-0.4	-0.2	-0.6	-0.2
-0.6	0	-0.2	0.1	0.2	0
0.3	-0.5	0.2	-0.5	0.4	-0.3
0.4	0.2	0.3	0.2	0.3	0.2
0.4	-0.5	0.5	-0.5	0.4	-0.4
0.5	-0.2	-0.5	-0.3	-0.5	-0.3
-0.6	0.4	-0.3	-0.3	-0.4	0.3

Vertical dimensions: Superior movement – Positive(+); Inferior movement- Negative(-). Horizontal dimensions: Anterior movement – Positive(+); Posterior movement – Negative(-)

3.2 Movement of Condyles in Anterior and Posterior Directions

In the immediate post operative period, six of the patients showed anterior movement of the condyle and four patients showed posterior movement of the condyle. At one month post operative period, five patients showed anterior movement of the condyle, and five patients

showed posterior movement of the condyle. At third month post operative period, six patients showed anterior movement of the condyle, and four patients showed posterior movement of the condyle. However, there is no statistically significant difference between the anterior and posterior movement at immediate, one month and third month post operatively.

Table 2. Showing postoperative movement of condyle in anterior and posterior directions

		Count	Column N %	Binomial test p value
Immediate Post OP (T1)	Positive	6	60.0%	.754
	Negative	4	40.0%	NS
	Total	10	100.0%	
1ST Month Post OP (T2)	Positive	5	50.0%	1.000
	Negative	5	50.0%	NS
	Total	10	100.0%	
3RD Month Post OP (T3)	Positive	6	60.0%	.754
	Negative	4	40.0%	NS
	Total	10	100.0%	

Table 3. Showing movement of the condyle in superior and inferior directions.

		Count	Column N %	Binomial test p value
IMMEDIATE POST OP (T1)	Positive	6	60.0%	.754
	Negative	4	40.0%	NS
	Total	10	100.0%	
1ST MONTH POST OP (T2)	Positive	4	40.0%	.754
	Negative	6	60.0%	NS
	Total	10	100.0%	
3RD MONTH POST OP (T3)	Positive	5	50.0%	1.000
	Negative	5	50.0%	NS
	Total	10	100.0%	

Table 4. Amount of movement of condyle in anterior and posterior dimensions

		95% Confidence Interval for Mean						
		N	Mean	Std. Deviation	Lower Bound	Upper Bound	T test p value	
IMMEDIATE POST OP (T1)	Positive	6	.400	.063	.334	.466	.000	HS
	Negative	4	-.600	.245	-.990	-.210		
	Total	10	.000	.537	-.384	.384		
1ST MONTH POST OP (T2)	Positive	5	.360	.134	.193	.527	.000	HS
	Negative	5	-.320	.084	-.424	-.216		
	Total	10	.020	.374	-.247	.287		
3RD MONTH POST OP (T3)	Positive	6	.333	.082	.248	.419	.000	HS
	Negative	4	-.600	.163	-.860	-.340		
	Total	10	-.040	.495	-.394	.314		

Table 5. Showing amount of movement of condyle in superior and inferior directions

		95% Confidence Interval for Mean						
		N	Mean	Std. Deviation	Lower Bound	Upper Bound	t test p value	
IMMEDIATE POST OP (T1)	Positive	4	.225	.126	.025	.425	.000	HS
	Negative	6	-.467	.207	-.683	-.250		
	Total	10	-.190	.396	-.473	.093		
1ST MONTH POST OP (T2)	Positive	4	.225	.126	.025	.425	.000	HS
	Negative	6	-.467	.207	-.683	-.250		
	Total	10	-.190	.396	-.473	.093		
3 RD MONTH POST OP (T3)	Positive	5	.200	.141	.024	.376	.000	HS
	Negative	5	-.320	.084	-.424	-.216		
	Total	10	-.060	.295	-.271	.151		

3.3 Post Operative Movement of Condyle in Superior and Inferior Directions

In the immediate post operative period, six of the patients showed superior movement of the condyle and four patients showed inferior movement of the condyle. At one month post operative period, four patients showed superior movement of the condyle, and four patients showed inferior movement of the condyle. At third month post operative period, six patients showed superior movement of the condyle, and four patients showed inferior movement of the condyle.

However, there is no statistically significant difference between the change in movement of condyle in superior and inferior directions.

3.4 Amount of Movement of Condyle in Anterio-posterior Directions

In the immediate post operative period, condyles moved a mean value of 0.4 (0.06) millimeter anteriorly and 0.6(0.24) millimeter posteriorly. In the first month postoperatively, the condyles moved a mean value of 0.3 (1.34) millimeter anteriorly and 0.3 (0.08) millimeters posteriorly. In the third month postoperatively, the condyles moved a mean value of 0.3 (0.82) mm anteriorly and 0.04(0.4) mm posteriorly.

3.5 Amount of Movement of Condyle in Superior and Inferior Directions

In the immediate post operative period, condyles moved a mean value of 0.2 5(0.126) mm superiorly and 0.46 (0.20) mm inferiorly. In the first month postoperatively, the condyles moved a mean value of 0.225(0.126) mm superiorly and 0.467 (0.207) mm inferiorly. In the third month postoperatively, the condyles moved a mean value of 0.200 (0.141) mm superiorly and 0.32 (0.84) mm inferiorly.

4. DISCUSSION

Condylar sag can be defined as an immediate or late caudal movement of the condyle in the glenoid fossa after surgical establishment of a preplanned occlusion and rigid fixation of the bone fragments, leading to a change in the occlusion. Altered occlusion due to a change in the condylar position may occur immediately after removal of the maxillomandibular fixation or later during the postoperative course.

Postoperative change in the position of the condyle can be classified, using radiographs, as either physiological condylar remodelling (CR) or pathological condylar resorption (PCR) according to the severity of the observed change in condylar morphology, which demonstrates a significant relation between condylar volume loss and skeletal relapse after Bilateral sagittal split osteotomy.

The present study was conducted from January 2017 to September 2018 to evaluate the changes in the condylar position following Bilateral Sagittal Split Osteotomy using lateral cephalograms and to quantify the amount of displacement of the condyle following bilateral sagittal split osteotomy in two dimensions. Lateral cephalograms were taken pre-operative, immediate post-operative, after 1 month and 3 months to evaluate the condylar position.

The patients included in the study were in the age group of 15-30 yrs who required Bilateral Sagittal Split Osteotomy. Out of the total patients selected for the study 3 were females and 7 were males. This gender difference can act as confounding factor. As reported by the Paknahad et al there is no significant differences in condylar position in asymptomatic subjects according to gender. Conversely as reported by Hajati et al and Gunson et al, females have more chances of condylar resorption [9]. Eventhoughthere is still no pathophysiological evidence of the relationship between the female gender and the major morphological changes of the condyles, there is strong speculation that the female hormone estrogen exerts a regulatory effect on the bone metabolism of the TMJ.

In the present study, at immediate post operative period six of the patients showed anterior movement, four patients showed posterior movement, six patients showed superior movement and four patients showed inferior movement of the condyles. In the immediate post operative period, condyles moved a mean value of 0.4mm anteriorly and 0.6mm posteriorly, 0.2 mm superiorly and 0.46 mm inferiorly. The condyle moved more posteriorly and inferiorly. However statistically not significant. This posterior movement could be because of inter maxillary fixation maintained during immediate postoperative period.

At first month postoperative period five patients showed anterior movement, five patients showed posterior movement, four patients showed

superior movement and six patients showed inferior movement of the condyles. However, there is no significant change in the movement of the condyles in antero-posterior and superio-inferior directions. In the first month post operative period, condyles moved a mean value of 0.3mm anteriorly and 0.3mm posteriorly, 0.225 mm superiorly and 0.46 mm inferiorly. Though it showed some amount of movement (0.46 mm) inferiorly, statistically it was not very significant. It could be because of inflammation of the joint comes down by a period of four weeks and also supra hyoid group of muscles have a tendency to pull the mandible in the inferior direction.

At third month post operative period six of the subjects showed forward movement, four patients showed backward movement, six patients showed upward movement and four patients showed downward movement of the condyles. In the third month post operative period, condyles moved a mean value of 0.3mm anteriorly and 0.04mm posteriorly, 0.2 mm superiorly and 0.32 mm inferiorly. The condyle moved more anteriorly and inferiorly. However, statistically not significant. Though the movement of condyles was not statistically significant, the minimum change in the position of the condyle can be attributed to the regaining of muscular activity.

Since mandibular condyles demonstrate adaptability to changed functional stimuli after the orthognathic surgery, progressive changes with a decrease in condylar volume may alter skeletal stability postoperatively [10]. In all our cases, both clinically and statistically there was no significant alteration in the condylar position in comparison to the preoperative position of the condyles. This was possible because all the measures were taken to position the condyle in the right place intra operatively with rigid fixation.

The present study had limitations. A very small number of participants and brief follow up periods were included in the the study. The influence of other confounding factors like age, gender were not considered in the study. With these limitations, the results of the present study cannot be generalised among patients undergoing Bilateral Sagittal Split Osteotomy.

A Long-term study with a larger sample size and a longer follow up period can be considered in future studies to evaluate the changes in the condylar position following Bilateral Sagittal Split Osteotomy using lateral cephalograms and to

quantify the amount of displacement of the condyle following Bilateral Sagittal Split Osteotomy in two dimensions.

5. CONCLUSION

This study was conducted to evaluate condylar position in pre and post Bilateral Sagittal Split Osteotomy using lateral cephalograms. The change in position of the condyles from pre-operative to the immediate post-operative, one month post-operative and three months post-operative is measured using lateral cephalograms super imposition method.

Following conclusions can be drawn from this study:

There is no statistically significant difference in the changes of movement of condyles in antero-posterior and superio-inferior directions at immediate post operative, one month post operative and third month post operative period.

In the immediate post operative period the condyle moved more posteriorly and inferiorly. However, statistically not significant. And this posterior movement could be because of inter maxillary fixation maintained during immediate postoperative period.

In the first month postoperative period, the condyles moved more inferiorly when compared to the preoperative position of the condyles and was not statistically significant which could be because of inflammation of the joint comes down by a period of four weeks and also supra hyoid group of muscles have a tendency to pull the mandible in the inferior direction.

In the third month post operative period, the condyle moved more anteriorly and inferiorly. However, statistically not significant. Though the condylar movement were not statistically significant, the minimum change in the position of the condyle can be attributed to the regaining of muscular activity.

Eventhough there is no statistically significant movement of condyles, there is change in movement of condyles in the insignificant ratio. However, larger sample size and larger follow up period is required to achieve a conclusiveresults.

CONSENT

As per international standard or university standard, patient (s) written consent has been collected and preserved by the author(s).

ETHICAL APPROVAL

As per international standard or university standard written ethical approval has been collected and preserved by the author(s).

COMPETING INTERESTS

Authors have declared that no competing interests exist.

REFERENCES

1. Raymond J Fonseca: Textbook of oral and maxillofacial Surgery. Published 2009;III: 68.
2. Byung-Joon Choi, Yong-Ha Choi, Baek-Soo Lee, Yong-Dae Kwon, Yong-Jin Choo, Joo-Young Ohe: A CBCT study on positional change in mandibular condyle according to metallic anchorage methods in skeletal class III patients after orthognathic surgery. Journal of Cranio-Maxillo-Facial Surgery. 2014;42:1617-1622.
3. Carl JG, Joseph Hon S, William JT. Causes, location and timing of relapse following rigid fixation after mandibular advancement. J Oral Maxillofac Surg. 1990;48(4):50-54
4. White and Pharoah: Oral Radiology: Principles & Interpretation, 5th edition.
5. Marden EA, Thomas D, Stephen RM, et al: Short-term changes of condylar position after sagittal split osteotomy for mandibular advancement. Oral Surg Oral Med Oral Pathol Oral Radiol Endod. 1999;87:159.
6. Akitoshi Kawamata, Masami Fujishita, Kuniteru Nagahara, Nobutake Kanematu, Kin-ichiro Niwa, and Robert R Langlais MS, D Gifu, Japan, and San Antonio, Tex; Oral Surg Oral Med Oral Pathol Oral Radiol Endod. 1998;85:371-6.
7. Piet E. Haers^b, Axel Zimmermann^b, Christian Oechslin^b: Surgical risk factors for condylar resorption after orthognathic surgery. Oral Surgery, Oral Medicine, Oral Pathology, Oral Radiology, and Endodontology. 2000;89(5):542-552.
8. Jevgenija Podčernina, Ilga Urtāne, Pertti Pirttiniemi, Ģirts Šalms: Evaluation of Condylar Positional, Structural, and Volumetric Status in Class III Orthognathic Surgery Patients. Medicina Kaunas. 2020;56(12):672. DOI: 10.3390/medicina56120672
9. Mark W Ochs: Bicortical screw stabilization of sagittal split osteotomies, Volume 61, Issue 12.
10. Yong-Il Kim, DDS, MSD, Bong-Hae Cho, DDS, MSD, PhD, Yun-Hoa Jung, DDS, MSD, PhD, Woo-Sung Son, DDS, MSD, PhD, and Soo-Byung Park: To compare the changes of the condylar axis, the anteroposterior condylar position relative to the glenoid fossa, and post-2-jaw surgery stability. Oral Surg Oral Med Oral Pathol Oral Radiol Endod. 2011;111(6):681-7.

© 2023 Shifa and Sequeira; This is an Open Access article distributed under the terms of the Creative Commons Attribution License (<http://creativecommons.org/licenses/by/4.0>), which permits unrestricted use, distribution, and reproduction in any medium, provided the original work is properly cited.

Peer-review history:

The peer review history for this paper can be accessed here:

<https://www.sdiarticle5.com/review-history/97958>