

Multidisciplinary Approach for Mapping Genetic Variants in Naevoid Basal Cell Carcinoma Syndrome. Newly Identified Patched 1 Mutations in Half-Sisters

E. Vetró ^{a*}, J. Olah ^b, T. Kalmar ^c, Z. Maróti ^c, E. Horvath ^d, M. Szell ^d, J. Piffko ^a and L. Seres ^{a*}

^a Department of Oral and Maxillofacial Surgery, University of Szeged, Hungary.

^b Department of Oncotherapy, University of Szeged, Hungary.

^c Department of Pediatrics University of Szeged, Hungary.

^d Department of Medical Genetics, University of Szeged, Hungary.

Authors' contributions

This work was carried out in collaboration among all authors. All authors read and approved the final manuscript.

Article Information

Open Peer Review History:

This journal follows the Advanced Open Peer Review policy. Identity of the Reviewers, Editor(s) and additional Reviewers, peer review comments, different versions of the manuscript, comments of the editors, etc are available here: <https://www.sdiarticle5.com/review-history/83431>

Case Study

Received 09 December 2021

Accepted 18 February 2022

Published 20 February 2022

ABSTRACT

Objective: Naevoid basal cell carcinoma syndrome is a rare and autosomal dominant inherited condition with variable expressivity. Several genetic mutations have been identified but clear genotype-phenotype correlations have not been demonstrated; therefore, the diagnosis is still based on clinical criteria that may not be present or are not recognized. Numerous medical specialties have a role in the care of these patients, so the number of cases treated in a single center is usually low, thus making the implementation of standardized diagnostic and treatment protocols difficult.

Materials and Methods: A multidisciplinary research team was set up to collect and diagnose naevoid basal cell carcinoma syndrome patients according to the same principles. All patients suspected for this syndrome underwent the same diagnostic steps involving molecular genetic investigation.

Results: One of the first results of this study was the identification of a novel mutation of the patched-1 gene in two maternal half-siblings. Both patients fulfilled the specific criteria for diagnosis

of naevoid basal cell carcinoma syndrome. Detailed descriptions of clinical, radiological, and genetic findings are given in this paper. Molecular genetic analysis identified a new deletion mutation in exon 13 of the Patched 1 gene in both half-siblings.

Conclusion: Genetic mapping of mutations can facilitate our understanding of the correlation between genetic background and clinical manifestations.

Keywords: *Naevoid basal cell carcinoma syndrome; odontogenic keratocysts, basal cell carcinoma; genetic polymorphism; mutation.*

1. INTRODUCTION

Gorlin syndrome, also known as naevoid basal cell carcinoma syndrome (NBCCS), is a rare, hereditary condition that is characterized by a wide range of developmental disorders and a predisposition to different malignancies. It was first reported by Jarisch and White in 1894 and recognized as a syndrome by Gorlin and Goltz in 1960 [1-3]. Its incidence is difficult to determine due to its rarity and misdiagnosis. It is estimated to affect an average of 1 in 19,000 to 1 in 256,000 people worldwide, with a male-to-female ratio of 1:1 [4,5]. Its signs and symptoms are extremely variable; the central nervous, ocular, auditory, genitourinary, cardiovascular and skeletal systems may be affected [6]. NBCCS is most frequently characterized by the development of multiple jaw keratocyst and/or basal cell carcinomas. Keratocysts usually first appear during adolescence and rarely develop after the age of 30 [7]. The diagnosis of NBCCS is usually based on clinical criteria that were suggested by Evans et al. in 1993 and later modified by Kimonis et al. in 2004 [8,9]. According to the current principles, the diagnosis can be established if two major criteria (basal cell carcinomas, odontogenic keratocysts, palmar and/or plantar pits, ectopic calcifications of the falx cerebri, bifurcated ribs or a first degree relative with NBCCS) and one minor criterion (spina bifida, macrocephaly, cleft lip and palate, hypertelorism, ovarian fibroma, medulloblastoma) or one major and three minor criteria are present [10]. Approximately, 70%–80% of NBCCS patients have an affected parent, and the remaining 20%–30% are due to a de novo pathogenic variant [10,11]. In most cases, mutations of the patched-1 (PTCH1) gene are responsible for the development of NBCCS [12,13]. The PTCH1 is a tumor suppressor gene, a member of the sonic hedgehog pathway (SHH). It encodes a membrane receptor Patched (Ptch), which binds and inhibits another transmembrane protein and activator, smoothed (Smo), thus inactivating SHH pathway signaling. The SHH pathway plays an

essential role during embryonic development. Aberrations of this pathway are associated with birth defects or tumorigenesis. Despite investigations, the molecular mechanism of the interplay among Ptch and Smo remains undefined [14]. Mutations in other genes in the hedgehog signaling pathway, such as patched-2 (PTCH2) and suppressor of fused homolog (SUFU) genes, have also been associated with this syndrome. These may be deletions, insertions, splice site alterations, nonsense, or missense mutations [15]. Clear genotype-phenotype correlations have not been demonstrated [16]. Multi-layered mutations in genes involved in the hedgehog pathway may explain the wide phenotypic variability of Gorlin–Goltz syndrome [17]. If clinical features are inconclusive, identification of a *PTCH1* or *SUFU* pathogenic variant on molecular genetic testing can establish the diagnosis [10]. Occasional variants in *PTCH2* may not be conclusive [18].

2. AIMS

Because of the variable expressivity, a significant part of the NBCCS patients is not recognized as they are scattered amongst different medical specialties. Due to the low incidence and diagnostic difficulties, studies with a large number of patients are hardly available [18]. To understand this complicated disorder better, information on a large number of patients is necessary. The aim of this study was to diagnose NBCCS patients from different medical centers according to the same principles and to collect data for further analysis.

3. MATERIALS AND METHODS

A multidisciplinary team, including oral and maxillofacial surgeons, dermatologists, radiologists, and clinical geneticists worked out a diagnostic protocol for all patients suspected of NBCCS. Panoramic radiography, chest x-ray (chest wall deformity) posterior-anterior skull radiography (falx cerebri), abdominal and pelvic ultrasound are performed in all cases. If a

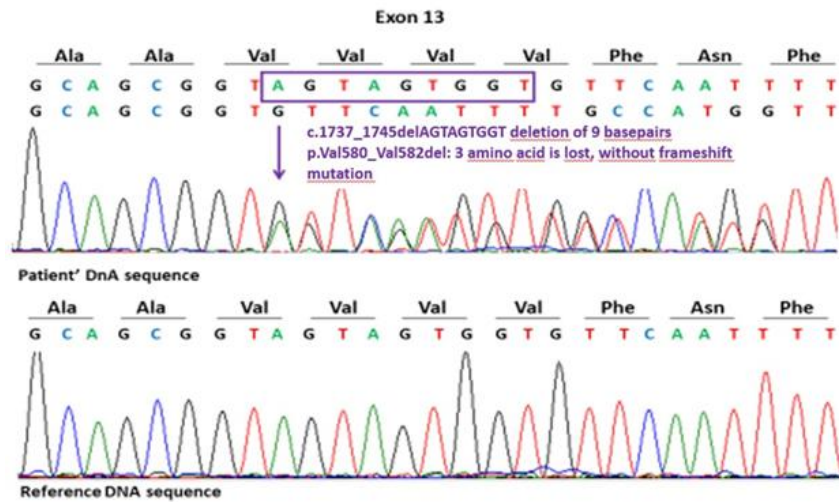


Fig. 1. DNA sequence chromatograms show the heterozygous deletion mutation (purple arrowhead) in exon 13 of PTCH1

genitourinary or a central nervous system disorder is suspected on radiology or clinical symptoms, magnetic resonance imaging of the region of interest is carried out too.

Routine chromosomal analysis was performed by standard techniques. Genomic DNA was extracted from peripheral blood samples with the Puregene kit (Gentra) after obtaining informed consent. The Illumina Trusight One Exome Sequencing Panel (Illumina Inc., San Diego, CA, USA) covering the coding region of 4813 clinically relevant genes was applied using Illumina MiSeq (Illumina Inc., San Diego, CA, USA). Variants were filtered based on severity and frequency against public variant databases

including single-nucleotide polymorphism database (dbSNP), ClinVar, Exome Aggregation Consortium (ExAC), Exome Variant Server (EVS) and in-house clinical exome database of 360 unrelated Hungarian persons. The presence of the identified variant was confirmed by Sanger sequencing using primers (Fig. 1).

4. RESULTS

A novel mutation of the patched-1 gene was detected in two half-siblings (Fig. 2). Detailed clinical, radiographic, and genetic analyses were undertaken in both affected members.

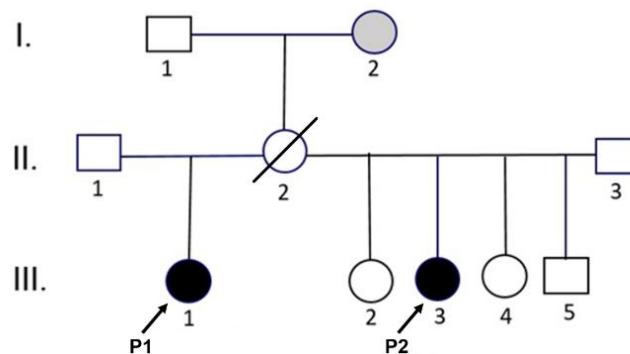


Fig. 2. Genealogy tree of the affected family. Patient 1 and Patient 2 (individuals III-1, and III-3, respectively) carry the PTCH1 mutation with clinical manifestations of NBCCS. Symbol filled in grey (individual I-2) indicates the maternal grandmother with multiple basalioomas and hypertelorism

Patient 1

A 15-year-old girl was referred to our maxillofacial department with a huge cyst involving the whole ramus, angle, and body of the mandible on the right side. On facial and oral examination, she exhibited previously operated bilateral cleft lip and palate, macrocephaly (head circumference was 59.0 cm, 99th percentile), frontal bossing, and hypertelorism. Canthal index

on measurement of inner and outer canthal distance was 42.8 (Fig. 3 A, B).

She was undergoing orthodontic treatment. All her lower teeth, except the third molars, had erupted. The right premolars and molars were slightly displaced. Previous routine panoramic radiographs at the ages of 6 and 12 failed to show any pathology in the mandible (Fig. 4 A, B, C).

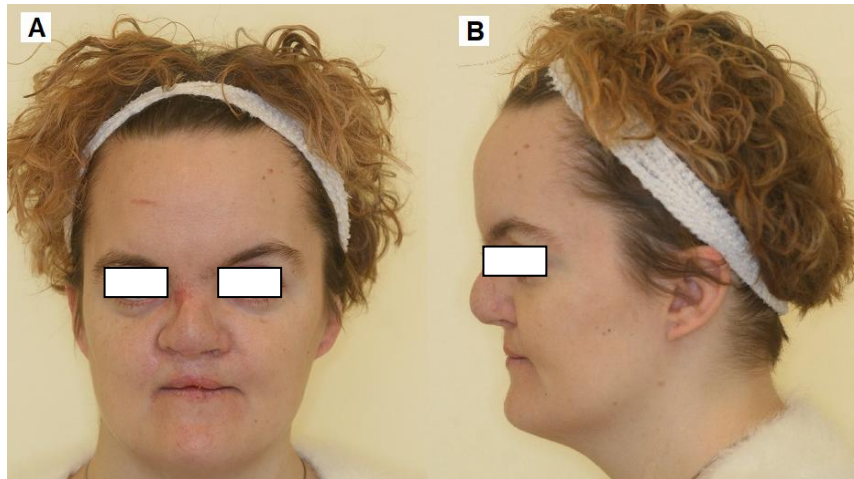

Fig. 3. (A) Frontal profile with increased inner canthal distance and scars of previous cleft lip surgery; (B) Side profile with frontal bossing and moderate macrocephaly.

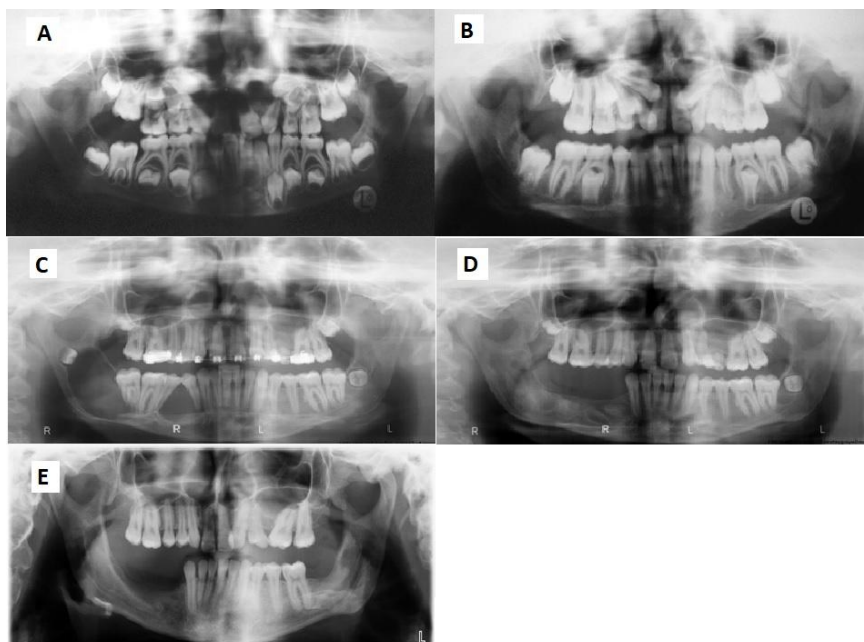


Fig. 4. Panoramic radiograph (A) at the age of 6 without signs of abnormality; (B) at the age of 12 with normal mandibular anatomy; (C) at the age of 15 shows a huge cystic lesion with inferior alveolar nerve canal displacement; (D) at the age 16 reveals development of a cyst around the left lower wisdom tooth; (E) at the age of 22

The cyst was removed together with the premolars and molars and the cystic cavity was filled with an autologous bone graft from the iliac crest. Histopathology was consistent with an odontogenic keratocyst. The diagnosis of NBCCS was made upon one major criterion (odontogenic keratocysts) and three minor criteria (cleft lip and palate, macrocephaly, hypertelorism). From her medical history, it should also be mentioned that she was under psychiatric treatment for distress, bipolar affective disorder, and schizophrenia. She was diagnosed with hypothyroidism, too. Further investigations did not find any involvement of other organs.

A year later another cyst with the same histology was enucleated along with the left lower third molar (Fig. 4 D). At the same time, impacted upper third molars were also removed as a preventive measure. Following that, the development of further cysts was not noted (Fig. 4 E).

Although at her first visit she was free of dermatological lesions, after the age of 18 she had several basal cell cancers removed from her face.

Patient 2

The younger maternal half-sibling of the patient mentioned above was also referred to our department with a unilateral facial swelling at the age of 17. Clinical examination revealed a prominent forehead, hypertelorism (canthal index was 42.2), and macrocephaly (head

circumference was 57.0 cm, 99th percentile) (Fig. 5).

A panoramic x-ray and CT scan showed multiple extended radiolucent lesions bilaterally in both jaws (Fig. 6 B, C, D). The previous X-ray at the age of 9 was normal (Fig. 6 A). Skull radiograph confirmed lamellar calcification of falx cerebri. Dermatological examination revealed pits on the soles of the feet and multiple pigmented nevi. After endodontic treatment of the nonvital mandibular first molars, all the cysts were removed together with both lower second molars and the lower right third molar. Histological findings were consistent with odontogenic keratocysts from all biopsies. The diagnosis of NBCCS was established on the presence of two major criteria (multiple odontogenic keratocysts, pits on the soles) and of one minor sign (hypertelorism). One year after the first operation, panoramic x-ray revealed recurrence in the left maxillary sinus, which was enucleated (Fig. 6 E).

4.1 The Patients' Mother and Grandmother

The girls' mother passed away when they were young. They were often accompanied by their maternal grandmother who had hypertelorism and reported that she had been operated with basal cell carcinoma several times (Fig. 7). Medical records of the patient's mother were not available, but according to the grandmother, she had had a number of jaw cysts removed.

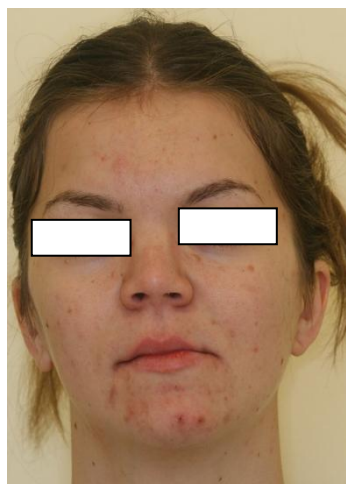

Fig. 5. The maternal half sibling's frontal profile photograph with hypertelorism

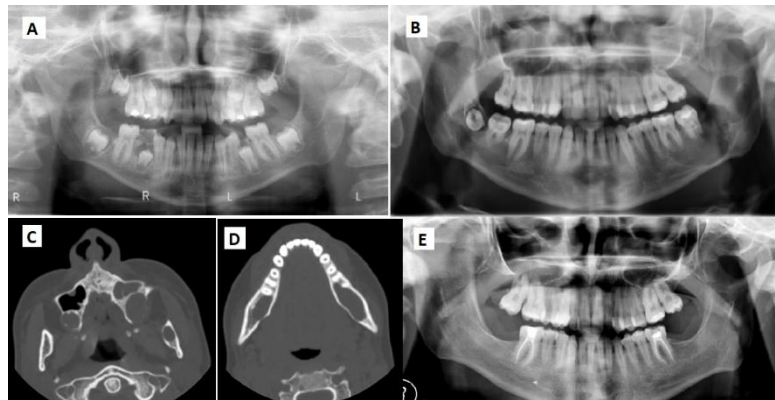


Fig. 6. Radiological findings in the half-sibling (A) normal panoramic radiograph at the age of 9; (B) at the age of 17 with multiple expansile radiolucencies associated with impacted teeth; (C, D) CT image shows large cystic lesions on both sides of the maxilla and the mandible (E) check-up after one year

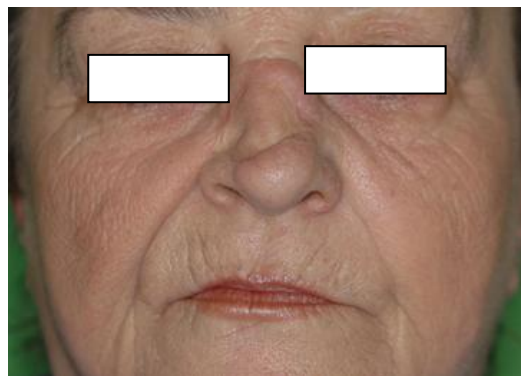

Fig. 7. The maternal grandmother's photograph reveals hypertelorism and scars on the nose after basal cell carcinoma removals

4.2 Genetic Investigations

Sequence analysis of *SUFU* was carried out without identifying any mutation. A yet to be known *PTCH1* gene heterozygous mutation has been validated, and its causative role in NBCCS has been confirmed with bioinformatic analysis of the molecular genetic investigation of family members with and without clinical signs of the syndrome.

Clinical exome (Trusight One panel) sequencing revealed a heterozygous variant (NM_000264.3:c.1737_1745delAGTAGTGGT, NP_000255.2:p.Val580_Val582del) in exon 13 of the *PTCH1* gene. This variant has not been found in either dbSNP (database of Single Nucleotide Polymorphisms), ClinVar, ExAC (Exome Aggregation Consortium), HGMD or EVS (Exome Variant Server) public databases or a cohort of 360 unrelated Hungarian controls. Sanger sequencing confirmed the heterozygous

mutation in the patient and revealed that her stepsister was heterozygous for this mutation, while the maternal grandmother was not a carrier. Samples were not available from the deceased mother of the girls. The confirmed genetic variation was submitted into ClinVar Database (Submission ID: SUB5336561).

5. DISCUSSION

Early diagnosis is essential to improve the standard for NBCCS patients [19]. In the above, two maternal half-siblings with NBCCS are presented. In both cases, signs and symptoms in the maxillofacial region raised suspicion of the syndrome, and this was confirmed by further clinical, radiological, and genetic investigations. Molecular genetic analysis identified a deletion mutation in exon 13 of the *PTCH1* gene in both half-siblings that has not previously been reported in the literature. Although the half-siblings have an identical mutation, their

phenotypes are quite different as described by other authors [20,21]. Their mother passed away, so her genetic analysis was not possible. Clinical examination of the maternal grandmother showed one major sign (multiple basal cell carcinomas) and one minor sign (hypertelorism). Although it can be assumed that the girls inherited the disease from their mother and maternal grandmother, interestingly, the defective gene could not be detected in the grandmother's genome. If the mother was alive, we could probably set up her and the grandmother's diagnosis of NBCCS. The deceased mother is the missing link, and although she most probably had NBCCS, it cannot be proved. Without a "first degree relative with NBCCS" as a major criterion, the grandmother's diagnosis of NBCCS cannot be made either. This paradox situation highlights the inaccuracy of the present diagnostic system.

6. CONCLUSIONS

The etiopathogenesis of NBCCS is far from being completely understood. As genetic investigations can be carried out even before clinical symptoms arise, every patient suspected of NBCCS should be genetically tested as early as possible. Genetic mapping of mutations can facilitate our understanding of the correlation between genetic background and clinical manifestations. The presented cases may add to our knowledge of this complicated genetic puzzle. The present diagnostic system of NBCCS will certainly move towards a genetic-based approach.

Further research is needed in order to reach a solid correlation between phenotype-based diagnosis and genetic analysis.

CONSENT

All authors declare that 'written informed consent was obtained from the patients for publication of this case report and accompanying images. A copy of the written consent is available for review by the Editorial office.

ETHICAL APPROVAL

The study was conducted in accordance with The Code of Ethics of the World Medical Association's Declaration of Helsinki for the experiments involving humans.

COMPETING INTERESTS

Authors have declared that no competing interests exist.

REFERENCES

1. Jarisch W. On the doctrine of skin tumors. *Arch Dermatol Syphilol*. 1894;18:162-222.
2. White JC. Multiple benign cystic epitheliomas. *J Cutan Genitourin Dis*. 1894;12:477-84.
3. Gorlin RJ, Goltz RW. Multiple nevoid basal-cell epithelioma, jaw cysts and bifid rib. A syndrome. *N Engl J Med*. 1960;262:908-12.
4. Evans DG, Howard E, Giblin C, Clancy T, Spencer, H, Huson, et al. Birth incidence and prevalence of tumor-prone syndromes: Estimates from a UK family genetic register service. *Am J Med Genet B*. 2010;152:327-332.
5. Lo Muzio L, Nocini PF, Savoia A, Consolo U, Procaccini M, Zelante L, et al. Nevoid basal cell carcinoma syndrome. Clinical findings in 37 Italian affected individuals. *Clin Genet*. 1999;55:34-40.
6. Lo Muzio L. Nevoid basal cell carcinoma syndrome (Gorlin syndrome). *Orphanet J Rare Dis* [serial on the Internet]. 2008;3:(32):[about 16p.]. [Cited 2020 Nov 08] Available:<https://doi.org/10.1186/1750-1172-3-32>
7. Kimonis VE, Goldstein AM, Pastakia B, Yang ML, Kase R, Di Giovanna JJ, et al. Clinical manifestations in 105 persons with nevoid basal cell carcinoma syndrome. *Am J Med Genet*. 1997;69:299-308.
8. Evans DG, Ladusans EJ, Rimmer S, Burnell LD, Thakker N, Farndon PA. Complications of the naevoid basal cell carcinoma syndrome: results of a population based study. *J Med Genet*. 1993;30:460-64.
9. Kimonis VE, Mehta SG, Digiovanna JJ, Bale SJ, Pastakia B. Radiological features in 82 patients with nevoid basal cell carcinoma (NBCC or Gorlin) syndrome. *Genet Med*. 2004;6:495-502.
10. Evans DG, Farndon PA. Nevoid basal cell carcinoma syndrome. *GeneReviews®* [serial on the Internet]. 2002;3:(32):[about 21p.]. [updated 2018 Mar] [Cited 2020 Nov 14] Available:<https://www.ncbi.nlm.nih.gov/books/NBK1151/>
11. Okamoto N, Naruto T, Kohmoto T, Komori T, Imoto I. A novel PTCH1 mutation in a

- patient with Gorlin syndrome. Hum genome var [serial on the Internet]. 2014;1:(14022):[about 3p.]. [cited 2020 Nov 02] Available:<https://doi.org/10.1038/hgv.2014.22>
12. Hahn H, Wicking C, Zaphiropoulos PG, Gailani MR, Shanley S, Chidambaram A, et al. Mutations of the human homolog of Drosophila patched in the nevoid basal cell carcinoma syndrome. Cell. 1996;85:841-51.
 13. Johnson RL, Rothman AL, Xie J, Goodrich LV, Bare JW, Bonifas JM et al. Human homolog of patched, a candidate gene for the basal cell nevus syndrome. Science. 1996;272:1668-71.
 14. Gong X, Qian H, Cao P, Zhao X, Zhou Q, Lei J, et al. Structural basis for the recognition of Sonic Hedgehog by human Patched1. Science [serial on the Internet]. 2018;361:(6402):[about 13p.]. [Cited 2020 Oct 28] Available:<https://science.sciencemag.org/content/361/6402/eaas8935>
 15. Wicking C, Shanley S, Smyth I, Gillies S, Negus K, Graham S, et al. Most germ-line mutations in the nevoid basal cell carcinoma syndrome lead to a premature termination of the PATCHED protein, and no genotype-phenotype correlations are evident. Am J Hum Genet. 1997;60:21-6.
 16. Onodera S, Saito A, Hasegawa D, Morita N, Watanabe K, Nomura T, et al. Multi-layered mutation in hedgehog-related genes in Gorlin syndrome may affect the phenotype. PLoS One [serial on the Internet]. 2017;12:(9):[about 14p.]. [Cited 2020 Oct 28] Available:<https://doi.org/10.1371/journal.pone.0184702>
 17. Fujii K, Ohashi H, Suzuki M, Hatsuse H, Shiohama T, Uchikawa H, et al. Frameshift mutation in the PTCH2 gene can cause nevoid basal cell carcinoma syndrome. Fam Cancer. 2013;12:611-14.
 18. Jones EA, Sajid MI, Shenton A, Evans DG. Basal cell carcinomas in Gorlin syndrome: a review of 202 patients. J Skin Cancer [serial on the Internet]; 2011. Available:<https://www.hindawi.com/journals/jsc/2011/217378/>
 19. Škodrić-Trifunović V, Stjepanović M, Savić Ž, Ilić M, Kavečan I, Privrodski JJ, et al. Novel Patched 1 mutations in patients with nevoid basal cell carcinoma syndrome—case report. Croatian medical journal. 2015;56:63-7.
 20. Li TJ, Yuan JW, Gu XM, Sun LS, Zhao HS. PTCH germline mutations in Chinese nevoid basal cell carcinoma syndrome patients. Oral Dis. 2008;14:174-9.
 21. Boutet N, Bignon YJ, Drouin-Garraud V, Sarda P, Longy M, Lacombe D, et al. Spectrum of PTCH1 mutations in French patients with Gorlin syndrome. J. Invest. Dermatol. 2003;121:478-81.

© 2022 Vetró et al.; This is an Open Access article distributed under the terms of the Creative Commons Attribution License (<http://creativecommons.org/licenses/by/4.0>), which permits unrestricted use, distribution, and reproduction in any medium, provided the original work is properly cited.

Peer-review history:

The peer review history for this paper can be accessed here:
<https://www.sdiarticle5.com/review-history/83431>