



Diagnosis of Senile Amyloidosis by Fine Needle Aspiration Biopsy and Cell Block from Abdominal Fat Pad

Arvind Bhake¹ and Kaustubh Kharche²

¹Department of Pathology, Jawaharlal Nehru Medical College, Central Research Laboratory, Datta Meghe Institute of Medical Sciences, Wardha, India.

²Department of Pathology, Jawaharlal Nehru Medical College, Datta Meghe Institute of Medical Sciences, Wardha, India.

Authors' contributions

This work was carried out in collaboration among all authors. 'All authors read and approved the final manuscript.

Article Information

DOI: 10.9734/JPRI/2021/v33i39A32145

Editor(s):

(1) Dr. Vasudevan Mani, Qassim University, Saudi Arabia.

Reviewers:

(1) Tan Xiao Jian, Tunku Abdul Rahman University College, Malaysia.

(2) Vaibhav Vijaykumar Kulkarni, University of Mumbai, India.

Complete Peer review History: <https://www.sdiarticle4.com/review-history/71212>

Study Protocol

Received 20 May 2021

Accepted 25 July 2021

Published 29 July 2021

ABSTRACT

Background: Amyloidosis is menacingly increasing medical problem in aging population across globe. Its clinical presentation is varied. Its laboratory diagnosis often requires biopsy material. The fine needle aspiration cytology (FNAC, FNAB) offers dependable diagnostic alternative to cumbersome biopsy. Present protocol describes the FNAC of abdominal pad of fat as surrogate site for diagnosis of senile systemic amyloidosis avoiding biopsy other known sites.

Aim: To study diagnostic accuracy of subcutaneous abdominal fat tissue fine needle aspiration cytology/biopsy for detecting systemic (senile) amyloidosis and its utility in clinical practice.

Objectives:

- i) To diagnose systemic amyloidosis (senile) by fine needle aspiration cytology/biopsy of abdominal fat pad on crush smears of aspirates and cell blocks.
- ii) To correlate the diagnosis of deposits of amyloid with the clinical manifestations in specific and non specific clinical manifestations of amyloidosis.

iii) To know the sensitivity and specificity of the diagnosis of amyloid deposition on fine needle aspiration cytology/biopsy of abdominal fat pad in comparison to the results of cell block preparations.

Methodology: A prospective study carried out to compare results of FNAC of abdominal pad of fat with paraffin embedded cell block in diagnosis of amyloidosis in suspected cases of cases of senile systemic amyloidosis. Technical adopted methods to be used are regular tissue stains, congo red stain and polarized microscopy.

Expected Results: It is expected that results of study will establish FNAC of abdominal pad of fat as dependable office diagnostic procedure that would avoid complicated biopsy procedures of gastrointestinal tissue, skin, bone marrow and others for senile systemic amyloidosis.

Keywords: Senile systemic amyloidosis; abdominal pad of fat; FNAC; clinical manifestations.

1. INTRODUCTION

One of the functional compromisers of the organs at ageing is the process of senile amyloidosis. Amyloid is an abnormal protein that is deposited in extracellular space existing either as a fibrillar protein or as abnormally folded insoluble aggregate in tissue [1].

Amyloidosis remains unnoticed and unsuspected clinically over a long duration until there is unexplained functional comprises of organs noticed and the index of clinical suspicion is high. Clinical presentations of amyloidosis are varied. It may be as common as refractory anemia or more dreaded disease such as Alzheimer to another pole.

The pathology of amyloidosis has three basic clinicopathologic categorizations of, i) Systemic generalized amyloidosis, ii) Hereditary amyloidosis and iii) Localized amyloidosis.

Amyloid monomers of beta sheet structure exists as i) amyloid like protein (AL), ii) amyloid associates (AA) and iii) transthyretin (ATTR) [1].

Several studies published from European and American continents have documented that senile systemic amyloidosis and localized senile amyloidosis especially senile cerebral amyloidosis is responsible for Alzheimer disease is increasing for its incidence [2-5]. The continent of Asia does not lack behind for occurrence of the amyloid of ageing as could be seen from published literature.

However, the amyloid of ageing has scarcely been studied in Indian population even though its clinical manifestations exist in the population of elderly patients in their seventies and eighties.

The multipronged diagnostic approach in detection of amyloidosis has been suggested as

described in flow chart (Fig. 1) below in the review of Wisniowski and Wechalekar [6]

The studies from India on senile amyloidosis are sparse. The clinical triad (renal, cardiac, and gastrointestinal) and anemia in the diagnosis of amyloidosis is helpful but requires confirmation on tissue. Aspiration cytology, an established procedure in pathology is simple and non-cumbersome yet definite diagnostic procedure. Its thoughtful alternative of biopsy diagnosis. Studies on amyloidosis in Indian population is are scarce. Therefore a study is required in a population of patients with clinically suspected amyloidosis by aspirations from surrogate sites such as abdominal pad of fat which avoid the invasive procedure of biopsies from the sites of rectum, liver, kidney, skin and bone marrow.

The clinical presentation of amyloidosis is amazingly dubious. It may present with conditions as a rare as cardiomyopathy and refractory diarrhea.

The central objective of the present project is to establish the value of aspiration biopsy carried out on abdominal pad of fat in clinically suspected cases of senile systemic or localized amyloidosis for its diagnosis.

There are studies available in literature that advices the fine needle aspiration biopsies of abdominal pad of fat for the diagnosis of senile systemic amyloidosis on the crush cytologic preparations and histological sections upon the congo red staining followed by polarized microscopy [7,8] and also by immunohistochemical methods [9,10] The sensitivity and specificity of this procedure in the diagnosis of amyloidosis has been quoted in the studies much equivalent to organ specific biopsies carried out from kidneys, rectum, skin and others like of bone marrow.

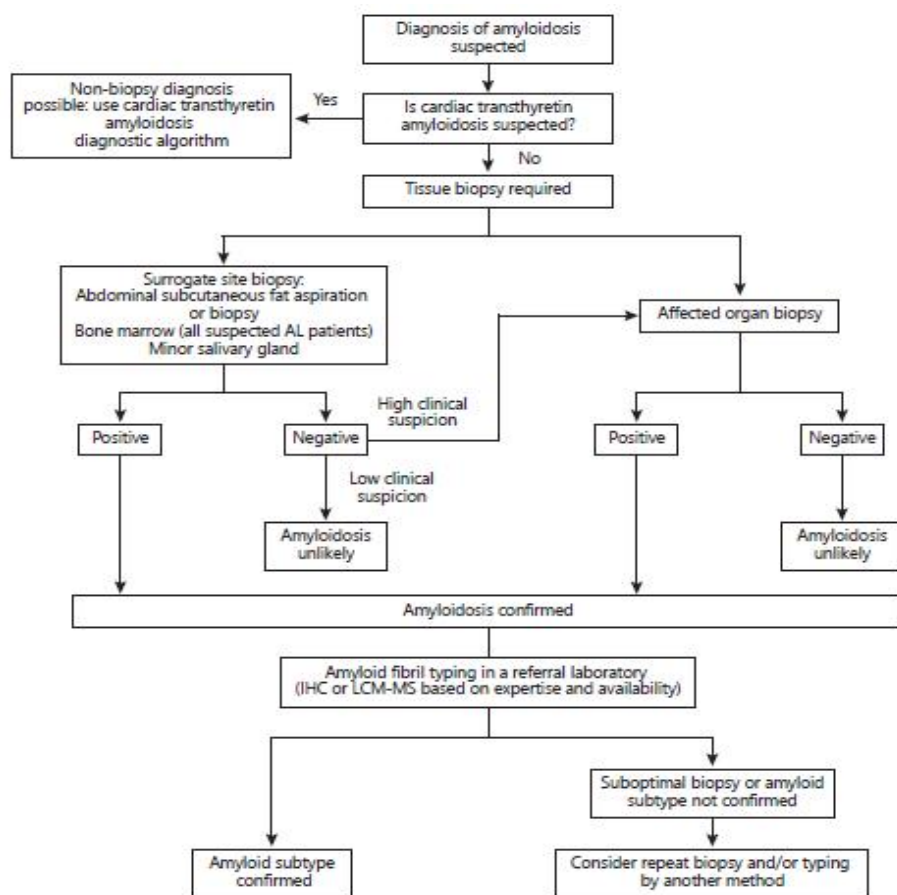


Fig. 1. Flow chart of diagnostic workup suggested for amyloidosis

1.1 Research Gap

The google engine search for the diagnosis of amyloidosis in Indian population on fine needle aspiration biopsy of surrogate sites is scant. There is ever rising incidence of amyloidosis but has not been either diagnosed or followed in Indian population. Surrogate site aspiration biopsy is yet not a popular diagnostic modality as could be seen by published literature. There exists a population that is presenting with clinical diagnostic triad (renal, cardiac, gastrointestinal) and anemia of amyloidosis yet not evaluated diagnostically by aspiration cytology. Therefore, such a study is undertaken at AVBRH, a university attached at tertiary care hospital, DMIMSDU, Sawangi, Wardha, Maharashtra, India.

1.2 Hypothesis

Fine needle aspiration biopsy from abdominal fat pad is an efficient diagnostic procedure to detect

the amyloid deposits in clinically suspected patients of senile systemic amyloidosis.

1.3 Aim and Objectives

Aim

To study diagnostic accuracy of subcutaneous abdominal fat tissue fine needle aspiration cytology/biopsy for detecting systemic (senile) amyloidosis and its utility in clinical practice.

Objectives

- iv) To diagnose systemic amyloidosis (senile) by fine needle aspiration cytology/biopsy of abdominal fat pad on crush smears of aspirates and cell blocks.
- v) To correlate the diagnosis of deposits of amyloid with the clinical manifestations in specific and non-specific clinical manifestations of amyloidosis.

- vi) To know the sensitivity and specificity of the diagnosis of amyloid deposition on fine needle aspiration cytology/biopsy of abdominal fat pad in comparison to the results of cell block preparations.

- iii) The patients with coetaneous infection over abdominal fat pad

2.1 Procedure

2.1.1 Interventions and procedure

The fine needle aspiration cytology/biopsy from abdominal fat pad is to be carried out by using twenty three gauge SN needle with following steps [11,12]:

- i) Ten ml syringe is connected by a valve system to a needle of 23 gauges.
- ii) The skin of the patient is marked and cleaned on both sides of umbilicus at about 7-10 cm distance. The needle is inserted in subcutaneous fat beneath the skin under the aseptic precautions.
- iii) 5-6 oscillations were made under negative pressure within the abdominal pad of fat. The plunger is released. The needle with the syringe is removed.
- iv) The procedure is repeated 3-4 times for aspirations from the different sites are until enough fat is collected.
- v) Aspiration is to be done at both sides of the umbilicus in order to obtain at least 60 mg of fat tissue.

2.2 Laboratory Methods

A] Processing of aspirated material

- i) The material collected at fine needle aspiration biopsy is to be examined by hand lens for visualization of fragments of the tissue.
- ii) A few of the fragments to be lifted and fixed in formalin to make cell block and the remaining tissue is made to the smears on regular microscopic glass slides and fixed in ethyl alcohol fixative 90%
- iii) Cell blocks is to be made of the fragments by thrombin clot method later to be processed in the histokinette similar to paraffin block making [13]
- iv) Sections of the cell blocks of five micron thickness is to be cut and deparaffinization of it will be done by standard steps.

2. MATERIALS AND METHODS

The present study titled, "Diagnosis of senile amyloidosis by fine needle aspiration biopsy and cell block from abdominal fat pad" is supposed to be conducted with following material and methods.

- **Place of study:**

AVBRH, DMIMS, Sawangi (Meghe), Wardha (Maharashtra)

- **Data collection:**

The data will be collected in proforma that contains the patient and clinical details

- **Sample size:**

Sample size is calculated by following formula

$$n = (Za/2)^2 \times p \times (1-p) / d^2$$

Where, $Za/2$ is the level of significance at 5% i.e. 95 % confidence interval
 p = prevalence of neonatal sepsis.
 d = desired error of margin
 n =sample size (20 cases)

Estimated sample size is 20 cases of clinically suspected systemic senile amyloidosis.

- **Patient characteristics:**

The following patients were included or excluded by criteria adopted:

- **Inclusion criteria:**

Male and female patients over age of sixty years.

The clinically suspected of systemic amyloidosis.

- **Exclusion criteria:**

- i) Patients below age of sixty years
- ii) Patients deemed unfit to undergo needle aspiration of abdominal fat pad.

B] Staining

- i) The alcohol fixed cytology smears of the aspirate of abdominal fat pad is later to be stained by Papanicolaou/Hematoxylin Eosin stains by standard steps.
- ii) The cytology smears as well as the deparaffinized section of the cell block is to be stained for congo red stain by Bennhold's method and modified alkaline version of it with following steps followed by polarized light microscopy [11,13]

Steps for congo red staining:

- i) Stain for 30 sec with Mayer's hematoxylin
- ii) Rinse in running tap water for 10 mins
- iii) Stain for 30 min in freshly filtered working solution 1
- iv) Stain for 30 min in freshly filtered working solution 2
- v) Rinse briefly in ethanol (100%) 2x
- vi) Rinse briefly in demineralised water 2x
- vii) Cover the slides with Kaiser's glycerol gelatin and a cover glass.

The positive results for amyloid is to be reported when polarized microscopy reveals apple green birefringence around the fat, intercellular spaces or around endothelial cell loops or vessel walls.

C] Reporting

Reporting of amyloidosis on HE stain of cytologic smears and HE staining of cell blocks will be made by definition characters as amorphous, fibrillary, eosinophilic material in the extracellular tissue as described in the standard text [14,15]

2.3 Statistics

The statistical tests will be applied for to know the sensitivity, specificity, positive predictive value by comparison of the observation made on cytology crush smears and cell blocks made out of aspirates of abdominal fat pad [16-19].

3. RESULTS

Expected outcome of the study is detection of amyloid by Fine needle aspiration cytology/biopsy of abdominal pad of fat at confirmation of clinical suspicion of systemic amyloidosis.

4. DISCUSSION

The following are the major studies reviewed for comparison of results of present study. Gameren

et al. [4] conducted a study on diagnostic accuracy of subcutaneous abdominal fat tissue aspiration for detecting systemic amyloidosis and its utility in clinical practice. The objective of the study was to know the accuracy of fat tissue aspiration for the diagnosis of systemic amyloidosis and its utility in clinical practice. The method by which it was done was by choosing patients who were suspected of having systemic amyloidosis and had undergone subcutaneous abdominal fat aspiration/biopsy. Congo red stained tissue was observed in a single smear by single observer and was examined in 3 smears by 2 independent observers. One hundred and twenty patients with diagnosed systemic amyloidosis were studied. Routine assessment was associated with 80% sensitivity. Sensitivity was increased to 93% when three smears were examined independently. The specificity of fat aspiration in 45 controls was 100%. One hundred and sixty two patients with a suspicion of systemic amyloidosis underwent screening by fat tissue aspiration/biopsy for amyloidosis. Out of these a diagnosis of amyloidosis was established in 66 patients. So, the study showed that the clinical utility of fat tissue aspiration/biopsy was greater than that of the biopsy of rectum [4].

Halloush et al. [1] did a study for the diagnosis and typing of systemic amyloidosis and to know the role of abdominal fat pad fine needle aspiration/biopsy. Thirty nine fat pad fine needle aspiration biopsies were taken from 38 patients. Smears and cell blocks were stained with congo red. A panel of antibodies (serum amyloid protein, serum amyloid A, albumin, transthyretin, kappa light chain and lambda light chain) was used on 6 cell blocks. The results were correlated with clinical and histological follow up. Positive results were seen in 5, suspicious in 1, negative in 28 and insufficient for diagnosis in 5 out of 39 samples. Among the 28 negative cases, 21 were diagnosed as systemic amyloidosis, rest were lost to follow up. Specificity was 100% and sensitivity was 19%. So, the study concluded that a negative result of fat pad fine needle aspiration biopsy does not exclude a diagnosis of systemic amyloidosis and immune phenotyping of amyloid is possible on cell block [1].

5. CONCLUSION

Likely conclusions is that Fine needle aspiration cytology/biopsy of abdominal fat is sensitive and specific at detection of systemic amyloidosis. It is an option to more cumbersome biopsies from

kidney, rectum and skin. This would avoid the invasive procedures of biopsy for diagnosis of senile systemic amyloidosis.

5.1 Implications of the Study

- i) The Fine needle aspiration cytology/biopsy of abdominal fat pad in clinically suspected amyloidosis provides a simple and safe procedure yet definitive diagnosis of amyloidosis with high sensitivity and specificity.
- ii) It therefore can become the part of diagnostic algorithm of systemic amyloidosis.

CONSENT AND ETHICAL APPROVAL

As per international standard or university standard guideline patients consent and ethical approval will be collected and preserved by the authors.

COMPETING INTERESTS

Authors have declared that no competing interests exist.

REFERENCES

1. Halloush R, Truong L, Lavrovskaya E, Mody D, Lager D. Diagnosis and typing of systemic amyloidosis: The role of abdominal fat pad fine needle aspiration biopsy. *Cyto Journal*. 2009;6(1):24.
2. Bogov BML, BK., Biopsy of subcutaneous fatty tissue for diagnosis of systemic amyloidosis. 2008;12(4):236-239.
3. Jr BFP, Federico R. Tewes. What attorneys should understand about Medicare set-aside allocations: How Medicare Set-Aside Allocation Is Going to Be Used to Accelerate Settlement Claims in Catastrophic Personal Injury Cases. *Clinical Medicine and Medical Research*. 2021;2(1):61-64. Available: <https://doi.org/10.52845/CMMR/2021v1i1a1>
4. Arahata M, Shimadoi S, Yamatani S, Hayashi S, Miwa S, Asakura H, et al. Three cases of systemic amyloidosis successfully diagnosed by subcutaneous fat tissue biopsy of the hip. *CIA*. 2016;11: 1061–6.
5. Gameren IIV, Hazenberg BPC, Bijzet J, Rijswijk MHV. Diagnostic accuracy of subcutaneous abdominal fat tissue aspiration for detecting systemic amyloidosis and its utility in clinical practice. *Arthritis Rheum*. 2006;54(6): 2015–21.
6. Daniel V, Daniel K. Diabetic neuropathy: new perspectives on early diagnosis and treatments. *Journal of Current Diabetes Reports*. 2020;1(1):12–14. Available: <https://doi.org/10.52845/JCDR/2020v1i1a3>
7. Devata S, Hari P, Markelova N, Li R, Komorowski R, Shidham VB. Detection of amyloid in abdominal fat pad aspirates in early amyloidosis: Role of electron microscopy and Congo red stained cell block sections. *CytoJournal*. 2011;8:11.
8. Wisniowski B, Wechalekar A. Confirming the Diagnosis of Amyloidosis. *Acta Haematol*. 2020;143(4):312–21.
9. Bowen K, Shah N, Lewin M. AL-Amyloidosis Presenting with Negative Congo Red Staining in the Setting of High Clinical Suspicion: A Case Report. *Case Reports in Nephrology*. 2012;2012:1–4.
10. Daniel V, Daniel K. Perception of Nurses' Work in Psychiatric Clinic. *Clinical Medicine Insights*. 2020;1(1):27-33. Available: <https://doi.org/10.52845/CMI/2020v1i1a5>
11. Quarta CC, Gonzalez-Lopez E, Gilbertson JA, Botcher N, Rowczenio D, Petrie A, et al. Diagnostic sensitivity of abdominal fat aspiration in cardiac amyloidosis. *European Heart Journal*. 2017;38(24): 1905–8.
12. Li T, Huang X, Cheng S, Zhao L, Ren G, Chen W, et al. Utility of abdominal skin plus subcutaneous fat and rectal mucosal biopsy in the diagnosis of AL amyloidosis with renal involvement. *Khodarahmi R, editor. PLoS ONE*. 2017;12(9):e0185078.
13. Daniel, V, Daniel K. Exercises training program: It's Effect on Muscle strength and Activity of daily living among elderly people. *Nursing and Midwifery*. 2020;1(01):19-23. <https://doi.org/10.52845/NM/2020v1i1a5>
14. Rokke P, Sadat Gousheh N, Westermarck P, Suhr OB, Anan I, Ihse E, et al. Abdominal fat pad biopsies exhibit good diagnostic accuracy in patients with suspected transthyretin amyloidosis. *Orphanet J Rare Dis*. 2020;15(1):278.
15. Hazenberg B. Fat aspiration procedure for the detection of amyloid [Internet]. 2011 [cited 17/02/2020].

- Available:<http://www.amyloid.nl/Files/Fat%20aspiration%20procedure02>.
16. Orell SR, Sterrett GF. Orell and Sterrett's fine needle aspiration cytology Edinburgh, Churchill Livingstone; 2012.
Available:<http://www.clinicalkey.com/dura/browse/bookChapter/3-s2.0-C20090495321>.
17. Suvarna SK, Layton C, Bancroft JD. Bancroft's theory and practice of histological techniques. [Oxford], Churchill Livingstone Elsevier; 2013.
18. Kumar V Abbas AK Aster JC, Robbins SL. Robbins basic pathology, 2013 Philadelphia, PA, Elsevier/Saunders.
19. Rosai J, Ackerman LV. Rosai and Ackerman's surgical pathology. Edinburgh, Mosby; 2011.
Available:<http://www.clinicalkey.com/dura/browse/bookChapter/3-s2.0-C20090365277>.

© 2021 Bhake and Kharche; This is an Open Access article distributed under the terms of the Creative Commons Attribution License (<http://creativecommons.org/licenses/by/4.0>), which permits unrestricted use, distribution, and reproduction in any medium, provided the original work is properly cited.

Peer-review history:

*The peer review history for this paper can be accessed here:
<https://www.sdiarticle4.com/review-history/71212>*