

Surgery for Crohn's Disease: Experience in the Department of General Surgery: A Retrospective Study of 60 Cases

A. Bachar^{a,b}, N. Fakhiri^{a,b*}, K. Falousse^{a,b}, T. El Abbassi^{a,b} and M. R. Lefriyekh^{a,b}

^a *Visceral Surgery Department, University Hospital Center Ibn Rochd, Casablanca, Morocco.*

^b *Faculty of Medicine and Pharmacy, Hassan II University, Casablanca, Morocco.*

Authors' contributions

This work was carried out in collaboration among all authors. All authors read and approved the final manuscript.

Article Information

Open Peer Review History:

This journal follows the Advanced Open Peer Review policy. Identity of the Reviewers, Editor(s) and additional Reviewers, peer review comments, different versions of the manuscript, comments of the editors, etc are available here: <https://www.sdiarticle5.com/review-history/94464>

Original Research Article

Received 08 October 2022

Accepted 15 December 2022

Published 19 December 2022

ABSTRACT

Crohn's disease (CD) consists of segmental digestive inflammation and transmural, Sometimes associated to anoperineal and extradigestive manifestations.

The clinical manifestations of our patients were varied ranging from simple pain Abdominal with diarrhea to occlusion or koenig's syndrome.

Paraclinical diagnosic was based on endoscopy and radiology performed on all our Patients.

The treatment of crohn disease is mainly medical, but surgery is still necessary in Case of complications or medical treatment resistance. Our work is a series of 60 patients, operated at the visceralSurgery department of the "CHU IBN ROCHD" Casablanca (Morocco). Over a period of 7 years, from 2015 to 2021. The purpose of which is to describe the surgical experience of the Department in the treatment of crohn's disease as well as its different indications.

The surgical indication was symptomatic stenosis in 38% of cases, and digestive Fistula in 36% of cases. The most used surgical approach was median laparotomy in 100% of patients.

The predominant surgical procedure was ileocecal resection performed in 58% of Patients In the absence of postoperative recurrence, surgery allows a significant Improvement in quality of life, however it will not cure the patient who will remain Exposed to a high risk of recurrence in the remaining bowel Mortality in our series was zero, morbidity was 16% of cases, represented by 6 Infections of the wall.

*Corresponding author: E-mail: nassima.fakhiri@gmail.com;

Keywords: Koenig's syndrome; crohn's disease; sténosis; fistula.

1. INTRODUCTION

Crohn's disease is an inflammatory and transmural granulomatous enterocolitis of unknown etiology. Infection of the entire digestive tract from the oral cavity to the anus, but most frequently the ileum, colon, and anus, the lesions are discontinuous and separated by areas of healthy mucosa [1].

It can be observed at any age but mainly affects young adults [2]. A disease that evolves by relapses, interspersed with remissions, it can be complicated by stenosis, abscesses and fistulas [1]. The clinic table is most often marked by digestive manifestations, but there are numerous extra-digestive manifestations that can be most often articular, cutaneous, and ocular.

The diagnosis is based on a range of clinical and paraclinical Features particularly endoscopic and histological [3].

Radiological and endoscopic examinations play an essential role in the positive diagnosis, also in the diagnosis of complications.

The treatment of Crohn's disease is essentially medical based on four major classes of drugs: aminosalicylates, corticosteroids, immunosuppressants and anti-TNF α . However, surgery remains necessary in more than 80% of patients [4]. It should not be indicated as a first-line treatment, but after failure or ineffectiveness of medical treatment or in case of complications requiring surgical intervention.

2. MATERIALS AND METHODS

Our work is a retrospective descriptive monocentric study of 60 cases of CD operated on in the visceral Surgery department of CHU Ibn Rochd of Casablanca (Morocco) over a period of 7 years from January 2015 to December 2021.

The average age of our patients at the time of diagnosis was 37 years with extremes from 16 to 68 years. The most affected age group was the 3rd decade: 30-39 years with 15 cases or 27%, followed by the 20-29 years age group with 13 cases (22%) in our series we noted a clear female predominance with 62% and 38% men, The sex ratio was 1.6, 76% of our patients were known to be carriers of CD and were put on

medical treatment, while for 24% of the patients the diagnosis was retained after surgical treatment and anatomopathological study of the surgical specimen. There were several associated comorbidities such as: diabetes in 2%, pulmonary tuberculosis in 4%, peritoneal tuberculosis in 2% treated with quadritherapy according to the national protocol and declared cured, ankylosing spondylitis in 2% and helicobacter pylori gastritis in 2%.

Appendectomy is the most frequent surgical history in 32% of our patients and ileo-coecal resection in 12% and anal fistula in 8%.

The symptomatology was variable: Abdominal pain at various sites was present in 78% of patients, chronic diarrhea in 58% of cases, Koenig's syndrome in 56% of cases, fecaluria in 6% of cases with general signs such as weight loss and asthenia in 46%.

The average BMI was 18.20 kg/m² with extremes of 14.28 and 27 kg/m² L, fever in 18 cases (18%) and pallor in 11 cases (11%).

The abdominal examination revealed: A swelling of the IDF in 6 patients (12%), a diffuse abdominal sensitivity in 50% of the cases with an enterocutaneous fistula in 22% with an abdominal meteorism in 16% of the cases, Anoperineal manifestations were found in 40% of the cases with an anal fistula in 12% and an anal fissure in 6%. The clinical examination was normal in 24% of cases.

Colonoscopy was performed in all our patients (100%) with a biopsy and systematic anatomopathological study.

Fibroscope was performed in only 22% of the patients and the following results were found An aspect of erythematous pangastritis in 12% of cases, a superficial ulceration in 4% of cases, a duodenitis in one case 2%.it was without particularities in 2% and for colonoscopy: It was performed in all our patients (100%).it revealed lesions such as aphthoid ulcerations, pseudo-polyps, stenosis, fistula and exulceration.

Staged biopsies were performed systematically, with anatomopathological study.

for the anatomopathological study: Histological analysis of colonic and bowel biopsies most often

allows to affirm the diagnosis in front of the presence of various lesions dominated by chronic non-specific inflammation in 34% ,Abdominal CT scan:It was carried out in 50% in search of collections abscessed, fistulas, or stenoses and objectified various lesions: Intestinal parietal thickening in 48 % of cases, 28% of stenosis, 18% of deep abscesses, 16% A fistula An agglutination of the intestinal coils in 20% of cases.

The enteroscanner was performed in 58% of cases. The purpose of the scan was exploration of the small intestine and the intestinal wall in search of stenosis and fistulas. 24% of the

patients had not received any medical treatment before the surgical indication. The remaining 14% were on salicylates before surgery, including 11% on mesalazine and 6% on salazopyrine. 24% were on corticosteroid therapy. 36% of the patients received azithioprine-based treatment One patient was on methotrexate the surgical indications were variable, they were : Digestive fistula in 36%, intestinal stenosis in 38%, stenosis associated with a fistula in 10%, an intra-abdominal collection of the IDF and the psoas in 10%, a sigmoidal colostomy of cleanliness on polyfistulized perineum 6% case.

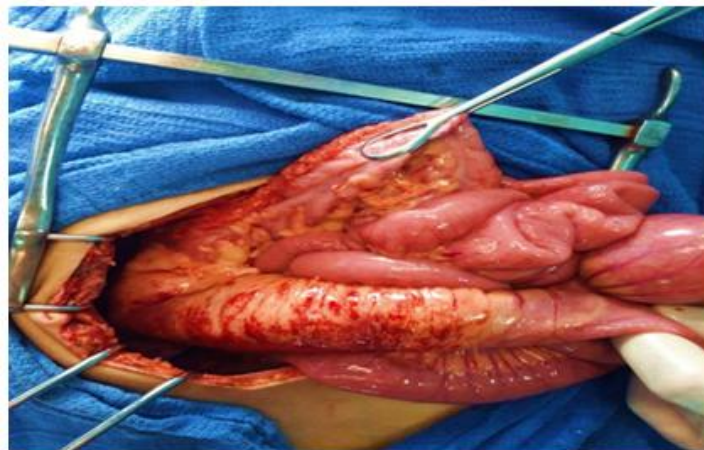


Fig. 1. Image showing a terminal ileum and thickening of the Jic. (Iconography of the department of visceral surgery wing i at Ibn Rochd Hospital)

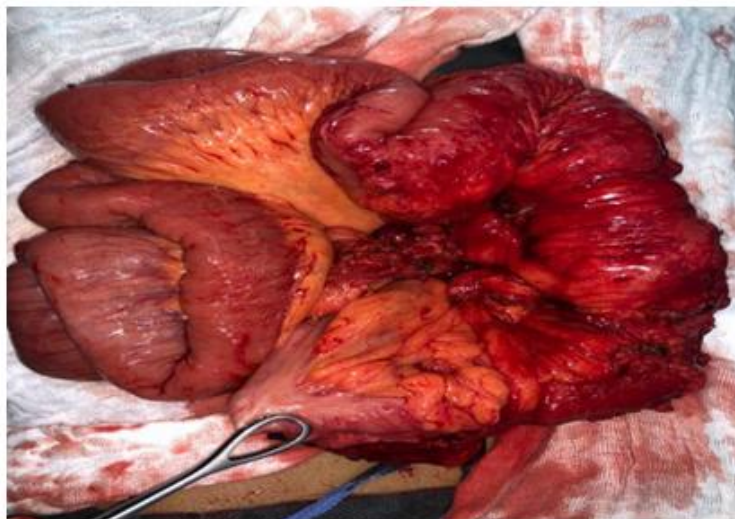


Fig. 2. Intra-operative image showing a distended bowel upstream of an extensive stenosis of the IAD during surgical exploration. (Iconography of the department of visceral surgery (Iconography of the visceral surgery department, Wing I, Ibn Rochd Hospital)

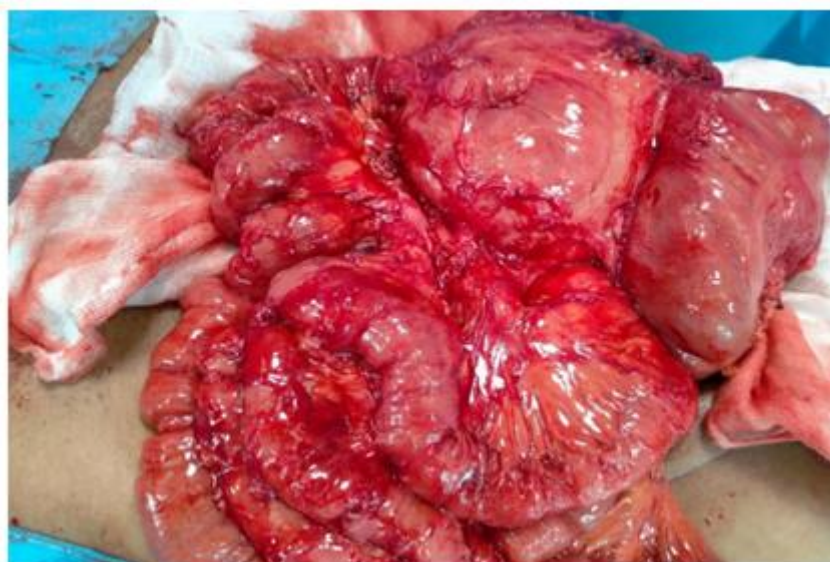

Fig. 3. Intraoperative image showing a magma of agglutinated gall bladders with fistulas (iconography of the visceral surgery department, Wing I at Ibn Rochd Hospital)

3. DISCUSSION

Crohn's disease is a chronic inflammatory condition of unknown cause that can affect all segments of the gastrointestinal tract, but most commonly the ileum and colon: ileo-caecal involvement, and to a lesser degree the anus region. It has been known by several names: Crohn's colitis, Crohn-Lesniowsky disease, Crohn-Lesniowsky syndrome, and regional Crohn's disease. Giovanni Battista Morgagni (1682-1771) was the first to report the case of granulomatous enterocolitis in a 20-year-old man who presented with diarrhea sometimes bloody with abdominal colic type pain [5].

Currently, it is known that CD, if it is especially frequent at the level of the terminal ileum, can reach simultaneously or successively any segment of the digestive tract, from the mouth to the anus. The lesions are characterized by their segmental aspect, sometimes the lesions are characterized by their segmental aspect, sometimes plurisegmental, leaving apparently healthy intervals between them [6].

Crohn's disease appears to be multifactorial, although the cause(s) of the disease remain unknown. Several arguments suggest the role of different factors [7-10].

Crohn's disease can therefore be considered as a digestive inflammatory disease which affects

predisposed subjects, linked to a dysregulation of the intestinal immune system induced by one or more stimuli and leading to an increased local production of pro-inflammatory cytokines responsible for the digestive lesions.

The role of genetic factors was initially suspected due to the existence of cases of the disease [11,12].

Smoking is the only environmental factor clearly identified in the etiopathogenesis of CD, especially in women. It increases the risk of the onset of CD and worsens its evolution, and increases the risk of the occurrence of fistulizing forms (considered the most aggressive), of the occurrence of relapses and therefore, the recourse to surgery, corticoids and immunosuppressants [13].

It also increases the risk of postoperative recurrence, mainly in women, with a dose-response relationship [14]. Intestinal permeability is decreased in patients with CD, which exacerbates the harmful role of tobacco [15]. Cessation reduces the risk of CD relapse by half in the first year, although an intermediate risk remains and disappears after three and four years of cessation [13].

The number of registered cases of CD per year tends to increase with the industrialization or westernization of populations [3]. In Europe, the annual incidence of Crohn's disease ranges from

3.7 to 7.0 cases/100,000 H. The prevalence rate of Crohn's disease, however, is quite variable in the studies. In Europe, it varies between 8.3 and 214 cases/100000 inhabitants. Concerning our Moroccan population, we do not have global statistics at the moment The only studies that have been carried out concern the university hospitals of Rabat, Casablanca and Marrakech.

Marrakech reported dozens of cases, but it is clear from the study data that Crohn's disease represents a pathology that is not rare and is increasing since its incidence has been rising in recent years [10,16,17].

Therapeutic strategies in CD must consider the age of the disease, its location, the severity and frequency of relapses, associated extradigestive diseases and nutritional status. The objectives of CD management include [18] prevention of relapses and complications as well as limiting the progression of lesions, ensuring psychological management, and maintaining a correct nutritional status.

to obtain a remission of the crisis and secondly the maintenance of the remission and the prevention of the relapses. (drug treatment). With the arrival of With the advent of biotherapies, the last ten years have seen the emergence of the concept of mucosal healing which [19] now appears to be the new objective to be achieved; mucosal healing is easier to obtain in recent diseases and is associated with a better prognosis with a reduction in complications.

Despite improvements in medical treatments, surgery remains an essential component in the management of CD. It is considered that approximately 15% to 20% of patients will undergo bowel resection surgery one year after diagnosis and 50% after 10 years [20]. After this initial surgery, the rate of clinical recurrence in the remaining bowel requiring further surgery is between 25 and recurrence rate on the remaining bowel requiring a new surgical procedure is between 25 and 65% at 10 years [20]. In Crohn's disease, surgery is not curative since the disease can recur in any part of the disease can recur in any segment of the digestive tract, The knowledge of this risk of recurrence justifies being sparing in terms of intestinal intestinal resection, to resect only symptomatic lesions, and finally, to propose after surgery a to propose a prophylactic treatment of recurrence after surgery.

With the exception of complicated forms revealing CD, surgery is always preceded by medical preceded by medical treatment, which is often reintroduced postoperatively in order to prevent to prevent relapse [21]. Azathioprine and metronidazole should be used for at least 3 months after surgery as they are known to decrease relapse.

4. CONCLUSION

Surgery remains an essential component in the management of CD. It is not curative since the disease can recur in any segment of the digestive tract.

Whatever its indication, surgery is only conceivable in association with medical treatment, and should be reserved for complicated forms or those resistant to well-managed medical treatment. For procedures involving the small intestine, resections or Strictureplasty are used. Resections must be minimal, limited to macroscopically affected areas because of the risk of short bowel syndrome. For colonic and rectal lesions, the aim of the succession of operations is to defer as much as possible the realization of a definitive terminal ileostomy. Laparoscopy has taken an increasingly important place in surgical management in recent years. It is the approach of choice for simple forms requiring ileocaecal resection. In case of complicated forms (abscess, fistula, recurrence), it can also be proposed but requires more experience. Postoperative complications are dominated by anastomotic fistula in the short term and by postoperative recurrence in the long term. The risk of postoperative recurrence and the risk of extensive or repeated intestinal resections that can lead to disorders of intestinal absorption imposes on the surgeon to make the principle of intestinal sparing prevail. This high risk of postoperative recurrence requires the introduction of a medical treatment to prevent relapse: maintenance treatment.

CONSENT

As per international standard or university standard, patient(s) written consent has been collected and preserved by the author(s).

ETHICAL APPROVAL

As per international standard or university standard written ethical approval has

been collected and preserved by the author(s).

COMPETING INTERESTS

Authors have declared that no competing interests exist.

REFERENCES

1. Caroline Klotz, Marion Dhooge, Ammar Oudjit, Maximilien Barret, Frederic Beuvon, et al. Management of Crohn's disease. *Med Press*. 2015;44(4):411-417.
2. Bernstein Cn. World gastroenterology organization practice guidelines for the diagnosis and management of Ibd; 2010.
3. De Saussure P, Bouhnik Y. Adult Crohn's Disease. *Emc*. 2007;9-057-G-10
4. Dash E, Karoui M. Surgical treatment of crohn's disease: Principles of tactics and operative technique. *Encycl Med Chir. Techniques*. 2006;40- 667:10. doi:10.1016/S0246-0424(06)39771-3
5. Crohn BB, Ginzburg. Regional Ileitis; A pathology and clinical entity. *Journal of American Medical Association*; Chicago. 1932;99:13:1329.
6. Crohn BB. Granulomatous disease of small and large bowel: A historical survey. *Gastro-Enterology*. 1967;767-772.
7. Brazier F. Remicade (Infliximab) in the treatment of crohn's disease" *La Presse Médicale*. September 16, 2000;29(26).
8. Colombel JF. Crohn's disease: Bacteria-mucosa interaction involved. *Le Concours Médical Tome 124-10*;2002.
9. Parodi André-Laurent. Crohn's disease and paratuberculosis of ruminants. *The Practitioner's Review*. 2002.52:1401-1404
10. Shutz G. Imaging of chronic small intestine stenosis. *Emc*. 2003;10:33-330.
11. Grainge MJ, West J, Card TR. Venous thromboembolism during active disease and remission in inflammatory bowel disease: a cohort study. *Lancet*. 2010;375:657–63.
12. Cortot Antoine. Homogeneous groups of patients during Crohn's disease: reality or fantasy? *Gastroenterol Clin and Biol*. 1998;22:591-593.
13. Ford, Alexander C, Sandborn, William J, Khan, Khurram J, et al. Efficacy of biological therapies in inflammatory bowel disease: Systematic review and meta-analysis. *The American Journal Of Gastroenterology*. 2011;106(4):644-659.
14. De Saussure P, Bouhnik Y. Adult crohn's disease. *Emc*. 2007;9-057-G-10.
15. Ali, Mr Fassi Fihri Mohamed. Risk factors for surgery for intestinal complications in patients with crohn's disease (About 218 Cases); 2016.
16. Elkessabi R. Surgical management of chronic inflammatory bowel disease. 2016.
17. Couturier M, Panis Y, Treton X, et al. Nod2 in ileal postoperative recurrence during crohn's disease surgery. 2016; 15(1):018-024.
18. Ephgrave K. Extra-intestinal manifestations of Crohn's disease. In: *Surgical Clinics of North America*. 2007;87:673-680.
19. Dignass A, Van Assche G, Lindsay JO. The second European evidence-based Consensus on the diagnosis and management of Crohn's disease: Current management. *J Crohns Colitis*. 2010 Feb;4(1):28-62.
20. Dr Charles N. Inflammatory bowel disease: A global approach world gastroenterology organization global guidelines; 2009.
21. Manceau G, Panis Y. Surgical treatments for Crohn's disease. In: *Post'U. France*. Springer. 2011;125-131.

© 2022 Bachar et al.; This is an Open Access article distributed under the terms of the Creative Commons Attribution License (<http://creativecommons.org/licenses/by/4.0>), which permits unrestricted use, distribution, and reproduction in any medium, provided the original work is properly cited.

Peer-review history:
The peer review history for this paper can be accessed here:
<https://www.sdiarticle5.com/review-history/94464>