

EVALUATION OF THE EFFECTS OF AQUEOUS GARLIC EXTRACT ON LEAD-INDUCED CHANGES ON CEREBELLUM OF WISTAR RATS

Hamza GA¹, Ibegbu AO², Buraimoh AA³

1. Department of Human Anatomy, Faculty of Basic Medical Sciences, Northwest University Kano, Nigeria
2. Department of Human Anatomy, Faculty of Medicine, Ahmadu Bello University, Kaduna State, Nigeria
3. Department of Human Anatomy, Faculty of Medicine, Kaduna State University (KASU) Kaduna State, Nigeria

Corresponding Author: Hamza G.A.

Email: hgadamu@gmail.com, hamzoic08@yahoo.com

ABSTRACT

Aims: The effects of aqueous garlic extract on lead-induced changes on the cerebellum of Wistar rats was investigated.

Methods: Forty five Wistar rats were randomly divided into nine groups. Group 1 served as Control. Groups 2 and 3 received lead at low and high doses. Group 4 received lead and garlic extract at low doses while Group 5 received lead at high dose and garlic extract at low dose. Group 6 received lead at low dose and garlic extract at high dose while Group 7 received lead and garlic extract at high doses. Group 8 and 9 received lead and Succimer at low and high doses respectively. Blood samples were collected for estimation of oxidative stress and the cerebellum sections were stained using routine hematoxylin and eosin and cresyl violet staining.

Results: Oxidative stress analyses of lead treated groups showed significant decrease in antioxidant enzymes activities and increased malondialdehyde level ($P \leq 0.05$) while significant increase in antioxidant enzymes activities and decrease in malondialdehyde level was noted in the lead and garlic extract Groups. Sections of the lead treated groups showed deleterious effects on cerebellum while aqueous garlic extract ameliorates the severity of the lead induced changes.

Conclusion: Our study suggests that aqueous garlic extract can reverse lead induced changes on the cerebellum.

Key words: Lead, Garlic, Oxidative stress, Antioxidant, Cerebellum

INTRODUCTION

Lead is a useful metal in life as it can be used in modern industries and agriculture, it is one of the most toxic heavy metals for body and its poisoning is known as an important public health problem (Patrick et al., 2006). Numerous studies have shown that lead exposure to body organs and systems to heavy metals including lead has been found to cause a number of disturbances which include neurological, hematological, gastrointestinal, reproductive, circulatory, and immunological disorders (Finkelstein, 1998; Dey, 2005). Lead can enter the body mainly via inhalation of automobile exhaust from gasoline containing alkyl lead additives, ingestion of dust

contaminated with lead, lead-based paints and drinking water that had passed through lead piping and transported to many tissues such as kidney, liver, bones and brain (Verma and Dubey, 2003; Flora, 2009; Alissa and Ferns, 2011). It has been reported that one of the major mechanisms by which lead induces its toxicity is by oxidative stress mechanism occurring on two different pathways; first, by generation of reactive oxygen species (ROS), like hydro peroxides (HO), singlet oxygen and hydrogen peroxide (H_2O_2), and second, by inactivation of the antioxidant reserves (Flora et al., 2002). The brain, including the spinal cord is highly metabolically active organ which, even at rest,

utilizes an estimated 20% of the total oxygen taken by the lungs. This percentage increases substantially when the brain is active (Shukla et al., 2011). This high utilization of oxygen, however, comes at a heavy biological price. As important as oxygen is for the survival of neurons and glia, it also indirectly contributes to their destruction and death over time. The reason for this is that a small percentage of oxygen that enters the cells is metabolized to derivatives that gradually erode and destroy essential molecules (Reiter et al., 2010). These destructive derivatives of oxygen are often referred to as free radicals or reactive oxygen species (ROS). Some of the notably destructive oxygen metabolites include the superoxide anion radical, hydrogen peroxide and hydroxyl radical (Volko, 2005). Garlic (*Allium sativum*) as a phytomedicine is a species in the onion genus, *Allium*. Garlic is one of the most researched plants, with long history of medicinal use (Omotoso et al., 2009). Garlic contains sulphur, phosphorus, potassium and zinc ions, moderate amounts of selenium, vitamin A, vitamin C and smaller amounts of calcium, magnesium, sodium, iron, B complex vitamins and allicin, a compound to trap free radicals (El Demerdash et al., 2005).

MATERIALS AND METHOD

Management and Treatment

Forty five Wistar rats (both sexes) were used in this study and were purchased from the animal house, Faculty of Pharmaceutical Sciences, Ahmadu Bello University, Zaria Nigeria. The animals were maintained at the animal house, Department of Human Anatomy, Faculty of Medicine, Ahmadu Bello University, Zaria Nigeria, under controlled conditions of temperature and humidity with rats chow and water provided *ad libitum*.

Experimental Groups:

The Wistar rats were randomly divided into nine groups as follows:

Group I (Control): each animal was administered with distilled water.

Group II (Lead treated): each animal was administered with 10% of LD₅₀ of lead acetate (60mg/kg body weight) dissolved in distilled water once a day.

Group III (Lead treated): each animal was administered with 20% of LD₅₀ of lead acetate (120mg/kg body weight) dissolved in distilled water once a day.

Group IV (LL + LE): each animal received aqueous garlic extract (300mg/kg body weight) and 10% of LD₅₀ of lead acetate (60mg/kg body

weight) dissolved in distilled water once a day by oral gavages.

Group V (HL + LE): each animal received aqueous garlic extract (300mg/kg body weight) and 20% of LD₅₀ of lead acetate (120mg/kg body weight) dissolved in distilled water once a day by oral gavages.

Group VI (LL + HE): each animal received aqueous garlic extract (500mg/kg body weight) and 10% of LD₅₀ of lead acetate (60mg/kg body weight) dissolved in distilled water once a day by oral gavages.

Group VII (HL + HE): each animal received aqueous garlic extract (500mg/kg body weight) and 20% of LD₅₀ of lead acetate (120mg/kg body weight) dissolved in distilled water once a day by oral gavage.

Group VIII (SD + LL): each animal was administered with Meso 2,3dimercapto succinic acid (30mg/kg body weight) and 10% of LD₅₀ of lead acetate (60mg/kg body weight) dissolved in distilled water once a day.

Group IX (SD + HL): each animal was administered with Meso 2,3dimercapto succinic acid (30mg/kg body weight) and 20% of LD₅₀ of lead acetate (120mg/kg body weight) dissolved in distilled water once a day.

All the treatments were carried out orally once a day for 21 days.

Histological method

At the end of the experiment, the animals were deeply anaesthetized with ether. The skull was opened through the mid-sagittal suture and the brain tissue was removed carefully, washed in normal saline and fixed in normal saline fixative containing 10% formaldehyde in 0.01M PBS at room temperature. The specimens were processed for preparation of paraffin blocks. Paraffin sections of cerebellar were cut longitudinally, prepared and stained using hematoxylin and eosin stain. Cresyl PAS violet stain was used for demonstration of Nissl substances.

Biochemical Assays

Blood samples were centrifuged at 1000rpm for 10 mins and the serum was collected and used for the estimation of oxidative stress markers.

Measurement of lipid peroxidation level (MDA)

MDA is commonly used as an index of lipid peroxidation. MDA content was assayed using method described by Ohkawa et al., (1979) modified by Atawodi et al., (2011). And the

specific activity was expressed as nmol/mg protein.

Measurement of Antioxidant Enzymes Activities

The SOD activity was estimated according to Fridovich et al., (1989); CAT according to Abei's method (1974) and GSH activity assayed by Ellman's method (1959). The activities of SOD, CAT and GSH were defined as u/ml, u/mg protein and µg/ml respectively.

Lead Acetate and its Preparation

High dose: 20% (120mg/kg body weight) of the LD₅₀ (600mg/kg body weight) of the lead acetate were dissolved in 1ml of distilled water for each of the adult Wistar rat according to their body weight.

Low dose: 10% (60mg/kg bw) of the LD₅₀ (600mg/kg body weight) of the lead acetate were dissolved in 1ml of distilled water for each of the adult Wistar rat according to their body weight according to the method of Magaji et al., (2014).

Source of Garlic and Preparation of the Extract:

Fresh garlic bulbs were obtained from Abubakar Rimi market, Kano and authenticated at the Department of Biological Science, Ahmadu Bello University Zaria, Nigeria. The garlic bulbs were then separated, peeled and washed with distilled water. After drying in a shed, the clean garlic bulbs were crushed with an electric grinder and then dissolved in distilled water. The extracts were then decanted carefully through muslin cloth (Senapati et al., 2000).

Source of Succimer (Meso 2, 3 dimercapto succinic acid)

Succimer (DMSA) was purchased from ABCAM Plc in United Kingdom with quote order reference number (#1887607) and product key (ab142294) respectively.

Statistics

All the results were analyzed using statistical package for social scientist (SPSS version 20) and the results were expressed as mean ±SEM. The statistical significance between the means were analyzed using one way analysis of variance (ANOVA) and P- value ≤ 0.05 was considered statistically significant.

RESULTS

Evaluation of Malondialdehyde Levels and Antioxidant Enzymes Activities

The results of the effect of lead acetate on the antioxidant enzyme activities and lipid peroxidation (MDA) are shown in the Table 1.0. The result of lipid peroxidation (MDA) level, showed that there was significant increase in lipid peroxidation (MDA) level in Group 2, 3, and 4 when compared to lipid peroxidation (MDA) level in the Control Group (P≤0.05), while there were non-significant increases in lipid peroxidation (MDA) level in Groups 5, 6, 7, 8, and 9 when compared to the Control Group. However, the results of antioxidant enzymes activities, showed that there were significant decreases in enzyme activities (SOD, GSH, & CAT) in Groups 2, 3, and 4 when compared to the Control Group (P≤0.05), while there were non-significant increases in enzyme activities (SOD, GSH, & CAT) in Groups 5, 6, 7, 8, and 9 when compared to the Control Group

Table 1 Effect of aqueous Garlic extract on lead induced changes on oxidative stress markers

| | SOD | GSH | CAT | MDA |
|--------------------------------------|--------------|--------------|-------------|------------|
| Group | Mean ±SEM | Mean ±SEM | Mean ±SEM | Mean ±SEM |
| 1 Control | 155.10±2.35 | 22.26±1.46 | 6.63±0.39 | 6.30±0.17 |
| 2 60mg/kg Pb ²⁺ | 136.35±1.89* | 11.29±1.04* | 2.75±0.24** | 7.95±0.48* |
| 3 120mg/kg Pb ²⁺ | 137.22±2.43* | 12.33±0.46* | 2.63±0.37** | 8.11±0.47* |
| 4 60mg/kg Pb ²⁺ + Extract | 136.08±3.19* | 21.67±1.66 | 4.56±0.53* | 7.86±0.54* |
| 5 120mg/kgPb ²⁺ + Extract | 156.87±1.20 | 10.71±0.91** | 6.14±0.20 | 6.68±0.29 |
| 6 60mg/kg Pb ²⁺ + Extract | 140.90±1.99 | 26.66±2.63 | 5.91±0.52 | 6.72±0.11 |
| 7 120mg/kgPb ²⁺ + Extract | 158.17±6.53 | 25.83±1.07 | 6.70±0.42 | 6.58±0.43 |
| 8 120mg/kgPb ²⁺ + DMSA | 159.19±4.08 | 27.22±4.74 | 6.69±0.37 | 6.76±0.16 |
| 9 120mg/kgPb ²⁺ +DMSA | 161.90±4.90 | 25.56±1.46 | 7.18±0.61 | 6.80±0.33 |

All the values are expressed as Mean ± SEM, the value in the same column with the same superscript are significantly different at *P = ≤0.05 or **P = ≤0.01

Histology

The results from histological observations showed changes in the tissues studied. The cerebellum of the animals in the control group (Group 1), showed normal cyto-architecture with clearly defined three layers of cerebellum; an outer Molecular layer, inner Granular layer and intermediate Purkinje layer with normal Purkinje cells while the cerebellum of the animals exposed to low and high doses of a Lead acetate only, showed marked neuro-degeneration of layers of the cerebellum with much of the Purkinje layer been affected. These changes include distortion of the cerebellar layers especially the Purkinje cell layer, loss of cellular

architecture, deformity of nuclei, loss of Nissl substance from Purkinje cells, and loss of nuclear cytoplasmic differentiation. The cerebellum of the animals exposed to low doses of the lead acetate and aqueous garlic extract; lead acetate and 30mg/kg body weight of Succimer showed more or less similar cyto-architecture with the Control Group with normal molecular layer, granular layer and middle Purkinje layer. However, the cerebellum of the animals exposed to high doses of the lead acetate and aqueous garlic extract; lead acetate and 30mg/kg body weight of Succimer revealed mild neuro-degeneration of the cerebellum layer as compared with the animals in the Control group.

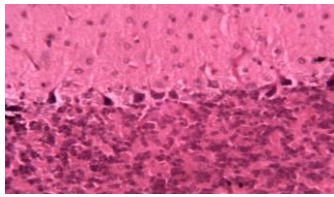


Plate 1: Cerebellum of the Control group (G1), showing normal orientation of the Molecular layer (ML), Granular layer (GL), and Purkinje layer (PL) with normal purkinje cells (PC) (H&E x250)

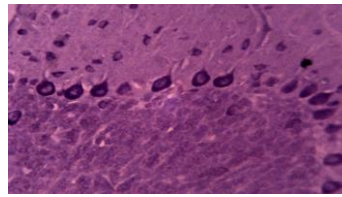


Plate 2: Cerebellum of a Control group (G1), showing normal Granular layer (GL), molecular layer (ML) and Purkinje cell layer (PL) with large flask shaped, uniformly arranged purkinje cells with a vesicular nuclei (Cresyl violet x250)

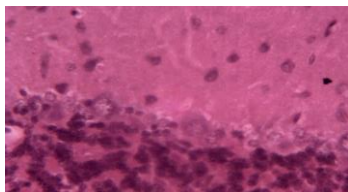


Plate 3: Cerebellum of the high lead treated group (G3), showing degenerated purkinje cells (DPC) (H&E X250)

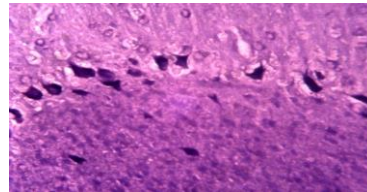


Plate 4: Cerebellum of a high lead treated group (G3) showing degeneration and distortion of Purkinje cells (P) with increase of the intensity of staining for Nissl granules (Cresyl violet x250)

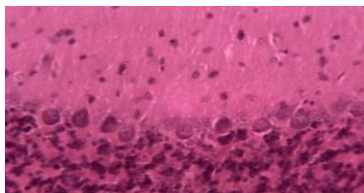


Plate 5: Cerebellum of the high lead & high garlic extract dose treated group (G7, showing normal Molecular layer (ML), Granular layer (GL) and Purkinje layer (PL) (H&E X250)

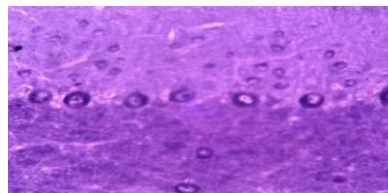


Plate 6: Cerebellum of a high lead + high garlic extract treated group (G7). The purkinje cells (PC) are more or less normal and some purkinje cells were observed in the granular layer (cresyl violet x250)

DISCUSSION

Several studies have shown that heavy metals induced oxidative stress and this has been the focus of toxicological research for the last two decades to evaluate the possible mechanism of their toxicity (Valavanidis et al., 2006). In the present study, the activities of the antioxidant enzymes; CAT, SOD and GSH were found to decrease significantly with increases malondialdehyde levels in the lead treated animals compared to the animals in the Control Group and this could be attributed to increases in reactive oxygen species (ROS) generation. The reduced activity observed was in agreement with work of Hatice et al., (2015); on the effect of lead and mercury on antioxidant systems in rat brain and reported that the mercury chloride and lead nitrate exhibited a significant inhibition of antioxidant enzymes activities and increased of malondialdehyde levels. However, the enzymes activity in the lead and aqueous garlic extract or Succimer (DMSA) Groups increases significantly with decreased malondialdehyde levels when compared with lead treated group only which is an indicator that aqueous garlic extract has beneficial effects against oxidative stress. However, histological examinations of the cerebellum sections in the present study of the Control Group, aqueous garlic extract and the standard drug (DMSA) showed normal cytoarchitecture of the cerebellum with relatively little histological changes while the cerebellum sections of the animals in the lead treated group only showed evident of histological changes which could be as result of macro molecules oxidation within the cells. These changes include distortion of the cerebellar layer especially the Purkinje cell layer, loss of cellular architecture, deformity of nuclei, loss of Nissl substance from Purkinje cells, and loss of nuclear cytoplasmic differentiation. Histological changes observed in cerebellum sections in the present study are supported by previous findings which showed changes in the cerebellum following lead exposure. One of such works was the work of Hesham et al., (2015) that studied if allicin combined with Vitamin B-complex have superior potentials than α -tocopherol alone in ameliorating lead acetate induced Purkinje cell alterations in rats.

CONCLUSION

The findings of the present study suggest that aqueous garlic extract can reverse lead induced changes on the cerebellum of Wistar rat.

REFERENCES

- Aebi H. (1984). Catalase in vitro; *Methods in Enzymology*, vol. 105, pp. 121–126.
- Alissa EM, Ferns GA. (2011). Heavy metal poisoning and cardiovascular disease. *J. Toxicol.*, Article ID 870125. 21 pp. Doi: 10.1155/2011/870125.
- Dey PM, Burger J, Gochfeld M, Reuhl KR. *Toxicology* (2005). Developmental lead exposure disturbs expression of synaptic neural cell adhesion molecules in herring gull brains; 146:137-147.8.
- El- Demerdash FM, Yousef MI, El-Naga NI. (2005). Biochemical study on onion and garlic in alloxan induced diabetic rats. *Food Chem Toxicol*; 43: 57-63.
- Ellman GC. (1959). Tissue sulfhydryl groups. *Arch Biochem Biophys*; 82: 707.
- Finkelstein Y, Markowitz ME, Rosen JF (1998). Low-level lead-induced neurotoxicity in children: an update on central nervous system effects. *Brain Res Brain Res Rev*; 27:168-176.9.
- Flora SJS (2009).Metal poisoning: threat and management. *Al Ameen J. Med. Sci.* 2(2): 4-26.
- Flora SJS. (2002). Nutritional components modify metal absorption, toxic response and chelation therapy. *J Nut Environ Med* 12: 53–67.
- Fridovich I, McCord JM. (1969). Superoxide dismutase; an enzymic function for erythrocyte (hemocuprein); *The Journal of Biological Chemistry*, vol. 244, no.22, pp. 6049–6055.
- Hatice B, Suna K, Hatice K, Apaydin FG. (2015). The effects on antioxidant enzyme systems in rat brain tissues of lead nitrate and mercury chloride; *Gazi University Journal of Science*; 28(2):169-174.
- Hesham NM, Adel MH (2015). Does allicin combined with vitamin B-complex have superior potentials than α -tocopherol alone in ameliorating lead acetate- induced Purkinje cell alterations in rats? *Folia Morphologic*; 10.5603.0076.

- Magaji RA, Magaji MG, Yusha'u Y, Faruk F, Muhammad UA, Fatihu MY. (2014). CNS depressant activity of acute lead acetate administration in mice. *Journal of Basic and Clinical Pharmacology and Toxicology*; 115 pp. 72.
- Ohkawa H, Ohishi N, Yagi K, (1979). Assay for lipid peroxides in animal tissues by thiobarbituric acid reaction", *Anal Biochem*, 95: 351-358.
- Omotoso G, Oyewopo A, Kadir, Olawuyi S, Jimoh A. (2009). Effects of Aqueous Extract (*AlliumSativum*) on Semen Parameters in Wistar Rats. *The Internet Journal of Urology*. Vol 7 Number 2.
- Patrick L. (2006). Lead toxicity a review of the literature part: exposure, evaluation and treatment. *Altern Med Rev*; 11:2-22.
- Patrick L. (2006). Lead toxicity part II: the role of free radical damage and the use of antioxidants in the pathology and treatment of lead toxicity; alternative medicine review volume 11, number 2.
- Reiter R, Lucien J, Manchester C, Dun X. (2010). Neurotoxins: Free radical mechanisms and melatonin protection. *CurrNeuropharmacol*; 8(3): 194-210.
- Senapati SK, Dey S, Dwivedi SK. (2000). The defects of garlic (*alliumsativum*) extract on tissue lead level in rats. *J. Ethnopharmacol.*; 76: 229-232.
- Shukla V, Santosh K., Mishra, and Harish, C. Pant (2011). Oxidative Stress in Neurodegeneration: Article ID 572634, 13 pages.
- Valavanidis A, Vlahogianni T, Dassenkis M, Scoulios M. (2006). "Molecular biomarker of oxidative stress in aquatic organisms in relation to toxic environmental pollutants", *Ecotoxicol. Environ.* 64: 178–189.
- Verma S, Dubey RS. (2003) Lead toxicity induces lipid peroxidation and alters the activities of antioxidant enzymes in growing rice plants. *Plant Sci.* 164:645-655.
- Volko M, Morris H, Cronim MT. (2005). Metals, toxicity and oxidative stress. *Curr Med Chem.* 12(10):1161-208.