



A Comparative Analysis of the Chest X-ray Findings between Pulmonary Tuberculosis Subjects with and without HIV/AIDS at the University of Nigeria Teaching Hospital, Enugu State, Nigeria

Emeka F. Ezenekwe ^{a*}, Enyereibe C. Ajare ^b,
Augustine C. Onuh ^b, Emeka K. Mgbe ^{b*}, Ngozi R. Dim ^b
and Chike C Chinweike ^c

^a Department of Radiology, Nnamdi Azikiwe University Teaching Hospital, Nnewi, Nigeria.

^b Department of Radiation Medicine, Faculty of clinical Sciences, College of Medicine, University of Nigeria, Ituku-Ozalla, Enugu, Nigeria.

^c Department of Radiology, Alex Ekwueme Federal University Teaching Hospital, Abakaliki, Ebonyi, Nigeria.

Authors' contributions

This work was carried out in collaboration among all authors. Authors EFE, ECA and ACO designed the study, performed the statistical analyses, wrote the protocol, and first draft of the manuscript. Author EKM managed the analyses of the study. Authors NRD and CCC managed the literature searches. All authors read and approved the final manuscript.

Article Information

DOI: <https://doi.org/10.9734/jammr/2024/v36i65467>

Open Peer Review History:

This journal follows the Advanced Open Peer Review policy. Identity of the Reviewers, Editor(s) and additional Reviewers, peer review comments, different versions of the manuscript, comments of the editors, etc are available here: <https://www.sdiarticle5.com/review-history/117904>

Original Research Article

Received: 21/03/2024

Accepted: 26/05/2024

Published: 05/06/2024

*Corresponding author: E-mail: emeka.mgbe@unn.edu.ng;

Cite as: F. Ezenekwe, Emeka, Enyereibe C. Ajare, Augustine C. Onuh, Emeka K. Mgbe, Ngozi R. Dim, and Chike C Chinweike. 2024. "A Comparative Analysis of the Chest X-Ray Findings Between Pulmonary Tuberculosis Subjects With and Without HIV/AIDS at the University of Nigeria Teaching Hospital, Enugu State, Nigeria". *Journal of Advances in Medicine and Medical Research* 36 (6):241-51. <https://doi.org/10.9734/jammr/2024/v36i65467>.

ABSTRACT

Introduction: Human immunodeficiency virus/Acquire immunodeficiency syndrome (HIV/AIDS) is one of the major health problems in developing countries. It is pandemic and has caused a resurgence of pulmonary tuberculosis (PTB), resulting in increased morbidity and mortality.

Aims: To document the chest radiographic findings in adult HIV/AIDS patients co-infected with pulmonary tuberculosis before the commencement of antiretroviral therapy, and to compare these with HIV-negative PTB subjects before the commencement of anti-tuberculosis drugs.

Study Design: Prospective cross-sectional study.

Place and duration of study: Department of Radiation Medicine, university of Nigeria teaching hospital Ituku/Ozalla, Nigeria. April 2023 to January 2024

Methodology: This was a descriptive cross-sectional study of chest radiographs of 230 HIV positive PTB subjects matched for age and sex with HIV negative PTB subjects at UNTH Enugu. The finding was analyzed using Statistical Package for the Social Sciences (SPSS) version 26.

Results: Patchy ($p=0.018$), perihilar and hilar opacities ($p=0.001$) are more prevalent in HIV - positive PTB subjects when compared with controls respectively. However, the controls had more cavitary lesions ($p=0.001$). The cavitary lesions were located more in the right upper zone in both groups. Volume loss ($p=0.001$), reticulonodular opacities ($p=0.001$) and pleural effusion ($p=0.014$) were more in HIV - negative PTB subjects.

Conclusion: Patchy, perihilar and hilar opacities provide a high index of suspicion for PTB in HIV - positive subjects.

Keywords: Chest X-Ray; adult; HIV/AIDS; PTB; chest findings; tuberculosis; mycobacterium tuberculosis.

1. INTRODUCTION

The Human Immunodeficiency Virus (HIV) infection which normally leads to Acquired Immunodeficiency Syndrome (AIDS) is a pandemic that has led to a rise in the incidence of tuberculosis [1-4]. Tuberculosis (TB) is a leading cause of morbidity and mortality in patients with HIV/AIDS [1,2,5,6]. HIV and TB are also intricately linked to malnutrition, unemployment, alcoholism, drug abuse, poverty and homelessness. The direct and indirect costs of illness due to TB and HIV are enormous. It is estimated that in developing countries about half the people living with HIV infection will develop active tuberculosis [7]. Tuberculosis (TB) is an infectious disease caused by *Mycobacterium tuberculosis*. TB has been described as a major public health problem in most low-income countries worldwide and about 80% of TB cases are in the economically productive age group of 15-49 years with the highest risk group being the male subjects[8,9]. Pulmonary tuberculosis (PTB) is the most frequent form of the disease, usually comprising over 70% of cases. [8-10]. Nigeria, being the continent's most populous country has the second highest burden of TB in Africa and fifth in the World [2]. Death due to TB co-infection in HIV infected patients is about 22%.[11] The past decades, have witnessed a dual

epidemic of TB and HIV/AIDS in sub-Saharan Africa.

Chest radiography is a relatively cheap and easily accessible imaging modality used for the screening and diagnosis of PTB. It is used in the assessment of chest findings in confirmed HIV positive PTB patients. Although routine screening for TB is recommended for people living with HIV/AIDS (PLWHA), there has been no internationally accepted evidence-based approach to screening and diagnosis among this population. Imaging is one of the most important modalities for diagnosing TB infection.

Chest x-ray as a diagnostic tool in the investigation of HIV-TB co-infection needs to be explored to increase the case detection rate. This study is very important in the management of PTB in HIV prevalent setting especially in smear negative pulmonary tuberculosis and also seeks to contribute to the improvement of TB detection rate among people living with HIV/AIDS.

2. MATERIALS AND METHODS

The study was conducted at the Department of Radiation Medicine, University of Nigeria Teaching Hospital (UNTH), Ituku-Ozalla, Enugu. This was a descriptive cross-sectional study of chest radiographs of 230 HIV positive, PTB subjects matched for age and sex with HIV

negative PTB subjects at University of Nigeria Teaching Hospital, (UNTH) Enugu. The study group of seropositive HIV subjects with PTB co-infection were recruited from referrals (with clinical features of PTB) to the Radiation Medicine Department (from the HIV clinic) for baseline chest x-ray screening. The control group (HIV seronegative PTB subjects) were recruited from referrals with clinical features of PTB from the chest clinic of the hospital. An informed consent was obtained from both groups after adequate and clear explanation of the objectives of the study. Subjects were assured of the confidentiality of information obtained while their names were not included in the data sheet.

The chest x-rays were evaluated by consultant radiologists. The confirmed radiological findings were recorded into the data sheet. The HIV and sputum microscopy results done in the respective clinics of the hospital were documented. Approval for this study was granted by the Ethics and Research Committee of the University of Nigeria Teaching Hospital Enugu.

Inclusion Criteria are subjects who are above 18 years of age, HIV positive, co-infected with pulmonary tuberculosis and have not also started antiretroviral or anti-tuberculous drugs.

2.1 The Chest Findings Sought for Included

2.1.1 Cavitory lesion

This is a gas filled space surrounded by an opaque wall. The wall is 3mm or greater in thickness. The cavity may have an air-fluid level when it is an active lesion.

2.1.2 Opacities

These are soft tissue inhomogeneous to near-homogenous soft tissue densities within the lung fields. When they are irregular in appearance, they are called patchy opacities. When they are within the hila, they are called hilar opacities while when they are close to the hila, they are called perihilar opacities.

2.1.3 Calcification

This is an opaque density within the lung or the pleura.

2.1.4 Honeycomb appearance within the lung field

This is when the lung parenchyma is replaced by fine network of microcystic lesions.

2.1.5 Miliary shadows

These are numerous discrete uniform nodular densities that are less than 5mm and evenly distributed throughout the lung fields.

2.1.6 Reticular and nodular shadowing in the lung field

These are called reticulonodular densities.

2.1.7 Consolidation

This is seen as homogenous opacification in the lung field with or without air bronchogram.

2.1.8 Pleural effusion

This is seen as uniform homogenous opacification in the dependent area with obliteration of costophrenic angles in erect film. Significant quantity causes homogenous opacification of the hemithorax with meniscus sign. It could also be loculated along the pleura.

2.1.9 Pneumothorax

A pneumothorax is defined as hyperlucent area devoid of lung markings inside the thoracic cavity but outside the lung viz. pleural cavity.

2.1.10 Volume loss

This is depicted as direct evidence exemplified by cavitations and indirect evidence such as, crowding of the vessels within the collapsed area, displacement or bowing of the fissures, ipsilateral displacement of the mediastinal structures and crowding of ribs.

2.1.11 Hilar lymphadenopathy

This is seen as a lobulated opacity within the hilum.

2.2 Sample Size Determination

The sample size (n) was determined using the formula [12] $n = Z^2 pq/E^2$ with attrition rate of 5%.

This amounted to a minimum sample size of 228 for the study group and the control group which gives a total of 456 subjects for both the study and control groups.

2.3 Data Analysis

The data was analysed using Statistical Package for Social Sciences (SPSS) version 26 (IBM

Corp. Armonk, NY, USA). Data comparison (statistical test of significant) was done with the student t-test and Pearson's correlation coefficient for continuous variables, and chi square test for categorical data. At 95% confidence interval, two-tailed p-values less than or equal to 0.05 was considered statistically significant.

3. RESULTS

The ages of the subjects in this study ranged from 18 to 71 years. The age range for the study group is 19 to 67 years while the age range for the control group is 18 to 71 years. The control

was matched for age group and sex with the study group. Out of the 230 HIV - positive PTB subjects studied, there were 105 (45.6%) males and 125 (54.4%) females indicating a close sex distribution of 1:1.2. The mean age was 34.5 ± 9.9 years for the study group and 34.8 ± 10.6 years for the control group. The highest prevalence of HIV - positive PTB subjects was recorded in the 30-39-year age group with male and female values of 32 (30.5%) and 52 (41.6%) respectively. The highest prevalence of HIV - negative PTB subjects was recorded in the 20 - 29-year age group for male 36 (34.3%) and in the 30 - 39-year age group for female 49 (39.2%).

Table 1. Socio-demographic characteristics of subjects

Characteristic		HIV +VE PTB n (%)	HIV -VE PTB n (%)
Occupation	Students	69 (30.0)	39 (17.0)
	Traders	137 (59.6)	140 (60.9)
	Civil servants	24 (10.4)	50 (21.7)
	Doctors, nurses, laboratory Scientists	0 (0)	1 (0.4)
	Total	230 (100)	230 (100)
Educational Level Attained	Primary	12 (5.2)	31 (13.5)
	Secondary	140 (60.9)	143 (62.2)
	Tertiary	78 (33.9)	56 (24.3)
	Total	230 (100)	230 (100)
Marital Status	Single	139 (60.4)	93 (40.4)
	Married	91 (39.6)	137 (59.6)
	Total	230 (100)	230 (100)

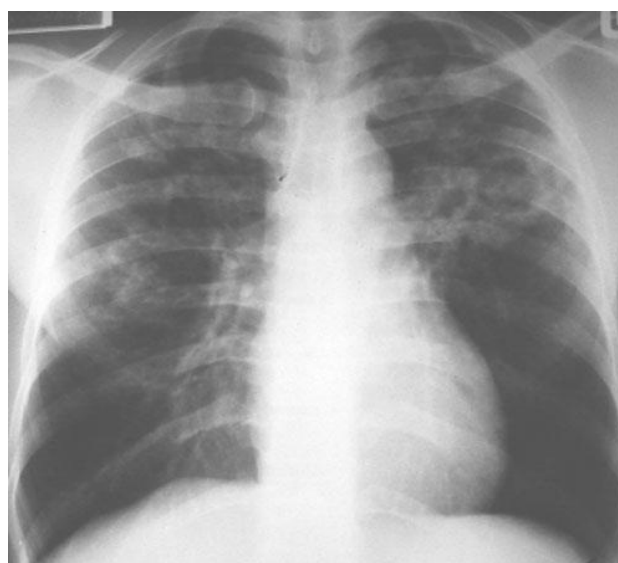


Fig. 1. PA chest X-ray of HIV - negative PTB subject that shows multiple thick walled cavitory lesions involving the upper and mid lung zones bilaterally. Patchy opacities are noted as in both zones as well with sparing of the lower lung zone

Table 2. Frequency of radiological findings in the lung fields of HIV-positive PTB and HIV-negative PTB subjects

FINDINGS	HIV - POSITIVE PTB				HIV - NEGATIVE PTB				P-Value
	Right Lung	Left Lung	Both Lungs	Total	Right Lung	Left Lung	Both Lungs	Total	
	n (%)	n (%)	n (%)	n (%)	n (%)	n (%)	n (%)	n (%)	
Cavitary lesions	22(36.7)	11(18.3)	27(45.0)	60 (26.1)	50(43.9)	23(20.2)	41(36.0)	114(49.6)	0.001
Reticulonodular Opacities	3(9.4)	3(9.4)	26(81.2)	32(13.9)	14(16.5)	17(20.0)	54(63.5)	85 (37.0)	0.001
Perihilar & Hilar Opacities	9(18.0)	9(18.0)	32(64.0)	50 (21.7)	3(50.0)	1(16.7)	2(33.3)	6(2.6)	0.001
Volume loss	18(85.7)	1(4.8)	2(9.5)	21(9.1)	33(53.2)	27(43.6)	2(3.2)	62 (27.0)	0.001
Pleural effusion	21(70.0)	7(23.3)	2(6.7)	30 (13.0)	21(42.0)	20(40.0)	9(18.0)	50 (21.7)	0.014
Patchy Opacities	35(31.5)	20(18.0)	56(50.5)	111(48.3)	31(36.0)	22(25.6)	33(38.4)	86(37.4)	0.018
Bullae	0	0	0	0 (0.0)	4(100)	0	0	4 (1.7)	0.046
Hilar Lymphadenopathy	13(46.4)	7(25.0)	8(28.6)	28 (12.2)	6(37.5)	3(18.7)	7(43.8)	16 (7.0)	0.057
Consolidation	25(73.5)	4(11.8)	5(14.7)	34(14.8)	9(39.1)	12(52.2)	2(6.7)	23 (10.0)	0.120
Honeycombing	0	0	0	0 (0.0)	0	0	2(100)	2 (0.9)	0.156
Pneumothorax	0	0	0	0 (0.0)	0	2(100)	0	2 (0.9)	0.156
Streaky Opacities	3(30.0)	1(10.0)	6(60.0)	10 (4.4)	6(37.6)	5(31.2)	5(31.2)	16 (7.0)	0.226
Miliary Shadow	0	0	5(100)	5(2.2)	0	0	2(100)	2 (0.9)	0.253
Calcification	1(50.0)	1(50.0)	0	2 (0.9)	0	1(50.0)	1(50.0)	2 (0.9)	1.000

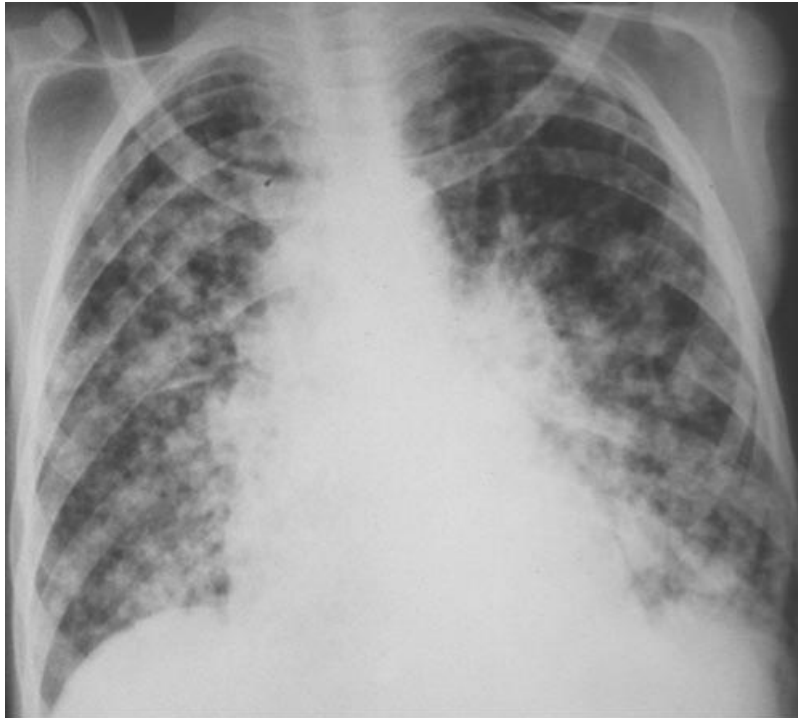

Fig. 2. PA Chest X-ray of HIV - positive PTB subject that shows bilateral diffuse reticulonodular and patchy opacities involving both lung fields

Table 1 shows that in HIV - positive PTB subjects, the majority, 137 (59.6%) were traders while 69 (30.0%) were students and 24 (10.4%) were civil servants. A total of 140 (60.9%) had secondary education while 78 (33.9%) had tertiary education and 12 (5.2%) had primary education; 139 (60.4%) were single while 91 (39.6%) were married.

Table 2 shows the distribution of chest radiographic findings observed in the HIV - positive PTB and HIV - negative PTB subjects. Patchy opacities 56(50.5%), perihilar and hilar opacities 32(64.0%) occurred more bilaterally in HIV - positive PTB subjects. The commonest radiological findings in HIV - positive PTB subjects in descending order was: patchy opacities in 111 cases (48.3%), cavitory lesions in 60 cases (26.1%), perihilar and hilar opacities in 50 cases (21.7%), consolidation in 34 cases (14.8%), reticulonodular opacities in 32 cases (13.9%), pleural effusion in 30 cases (13.0%), hilar lymphadenopathy in 28 cases (12.2%) and volume loss in 21cases (9.1%). The commonest radiological findings in the HIV - negative PTB subjects was cavitory lesions in 114 cases (49.6%), patchy opacities in 86 cases (37.4%), reticulonodular opacities in 85 cases (37.0%), volume loss in 62

cases (27.0%) and pleural effusion in 50 cases (21.7%).

Figs. 1 and 2 shows the common chest radiograph findings of cavitory lesions and opacifications seen in HIV negative and positive patients respectively.

The distribution of cavitory lesions by sex is highlighted in Table 3. Females with HIV - negative PTB had a higher prevalence of cavitory lesions compared with HIV - positive PTB females (48.8% vs 21.6%; $p=0.001$). Similarly, a higher prevalence was seen in males with HIV - negative PTB compared to males with HIV - positive PTB (50.5% vs 31.4%; $p=0.005$). Table 4 shows the distribution of cavitory lesions by age. There was a bi-modal age group prevalence of 20-29 year age group with 26.9% for HIV - positive PTB subjects and 57.7% for controls and 30-39 years age group with 25.0% for HIV - positive PTB subjects and 52.4% for controls. The control group had one and two subjects with cavitations respectively below 20 and above 60 years. There was 114 cavitations in the HIV - negative PTB subjects against 60 in HIV - positive PTB subjects (49.6% vs 26.1%; $p=0.001$).

Table 3. Distribution of cavitory lesions by sex in HIV - positive PTB and HIV - negative PTB

Sex	HIV +VE PTB	HIV –VE PTB	P-Value
	n(%)	n(%)	
Male	33 (31.4)	53 (50.5)	0.005
Female	27 (21.6)	61 (48.8)	0.001
Total	60 (26.1)	114 (49.6)	0.001

Table 4. Distribution of cavitory lesions by age groups of HIV - positive PTB and HIV - negative PTB subjects

Age group	HIV+VE PTB	HIV –VE PTB	P-Value
	Present n(%)	Present n(%)	
< 20	0 (0.0)	1 (25.0)	1.000
20 – 29	21 (26.9)	45 (57.7)	0.001
30 – 39	21 (25.0)	44 (52.4)	0.001
40 – 49	14 (32.6)	18 (41.9)	0.494
50 – 59	4 (30.8)	4 (30.8)	1.000
≥ 60	0 (0.0)	2 (25.0)	0.429
TOTAL	60 (26.1)	114 (49.6)	0.001

Table 5. Distribution of cavitory lesions in the lung fields of HIV - positive PTB and HIV - negative PTB subjects

Slobe	HIV - POSITIVE PTB (%)			HIV - NEGATIVE PTB (%)		
	Right lung	Left lung	Both lungs	Right lung	Left lung	Both lungs
Upper	16 (26.7)	5 (8.3)	14 (23.3)	33 (28.9)	17 (14.9)	16 (14.0)
Middle	3 (5.0)	0 (0)	0 (0)	6 (5.3)	0 (0.0)	0 (0.0)
Lower	1(1.7)	4(6.7)	1(1.7)	5(4.4)	1(0.9)	0(0.0)
>One lobe	2 (3.3)	2 (3.3)	12 (20.0)	6 (5.3)	5 (4.4)	25 (21.9)
Total	22 (36.7)	11 (18.3)	27 (45.0)	50 (43.9)	23 (20.2)	41 (35.9)

In Table 5; the cavitory lesions were observed to be located in the right upper lobe in HIV - positive PTB 16 cases (26.7%) and HIV - negative PTB subjects 33 cases (28.9%). Bilateral cavitory lesions were observed in 27 cases (45.0%) of HIV - positive PTB subjects.

In the HIV - negative PTB subjects, 50 cases (43.9%) of cavitory lesions involved the right lung while bilateral involvement occurred in 41 cases (35.9%).

4. DISCUSSION

Chest radiography is a widely utilised and relatively cheap means of assessing the chest in a clinical setting. Pulmonary tuberculosis being a major contributor to the disease burden in the developing countries has been on the increase with the advent of HIV/AIDS [13]. In this study, 230 adult HIV - positive PTB subjects were matched for age and sex with 230 HIV - negative PTB subjects. A male to female ratio of 1:1.2 was observed which shows the close sex distribution.

This is consistent with the finding of Zubairu et al [14] in Kano that reported male to female ratio of 1:1.2 but differed from the findings of Nwonwu et al[15] and Uneke et al[16] both in Abakiliki, Saidu[17] et al in Sokoto , Ahidjo et al[13] in Maiduguri and Zhou et al[18]in Chinawho reported a male preponderance of 1.4:1, 2:1, 1.4:1 ,1.3:1 and 6.4:1 respectively or that of Erinle[19] in Ilorin who reported a female preponderance. Ahidjo et al[13] suggested that the non uniformity of sex distribution between studies could be due to the selection criteria used.

The mean age of the patients in this study was 34.6 ± 10.3 years. There was no difference in age distribution between the HIV - positive PTB and control. This is similar to the findings of Ahidjo et al⁸ and Idoko et al[20]. The highest prevalence of HIV - positive PTB in the present study was in the 30-39 year-old in both sexes. Nwonwu et al[15] in Abakiliki, Affusim et al[21] in Benin and Zubairu et al[22] in Kano also made similar observations. This finding may be related

to the fact that the extremely young and old people are less likely to be involved in the risky behaviours that predispose individuals to HIV infection. This corroborates the fact that HIV is more common in the reproductive, economically viable and sexually active age group[13,16]. They are also more exposed to multiple sexual partners and thus more predisposed to HIV infection.

The common chest radiographic findings seen in HIV negative PTB subjects in this study include cavitory lesions, pleural effusion, volume loss, patchy and reticulonodular opacities. Higher frequencies of patchy opacities (48.3%), perihilar and hilar opacities (21.7%), consolidation (14.8%), and volume loss (9.1%) were observed among HIV - positive PTB subjects. This is similar to the studies of Aguwa et al[23] and Nwonwu et al[15]. Although no normal chest radiograph was noted in this study, a good proportion of normal chest radiographs were reported by Ahidjo et al[13], Ahmadi et al[11] and Affusim et al[21] while Oriekot[22] et al has only 3% as normal. In this study, a diagnosis of PTB with normal chest finding was not documented as most subjects with normal radiographs declined sputum for AFB analysis. It is also important to note that the design of all the previous studies had some sputum smear analysis done before the chest radiographs were taken probably because the subjects were referred from the chest clinic rather than from HIV clinic.

Although there is lack of uniformity between studies in the choice of description of features[6,22], opacities of different types form the most common finding in the study group. Furthermore, bilateral patchy subsets of opacities were more prevalent, though Nwonwu et al[15] in Abakiliki reported a prevalence of patchy opacities that is lower than that of cavitory lesions in HIV - positive PTB subjects.

The cavitory lesions were more prevalent in the HIV - negative PTB subjects and were seen more in the right upper lobe in both subject groups. This is also in keeping with majority of the previous studies that reported right upper lobe cavitory lesions[14,21,23-25] but different from the study of Nwonwu et al[15] which reported a higher frequency of cavitory lesion involvement in HIV - positive PTB subjects. The reduced cavitory lesions observed in HIV - positive subjects have been reported to be related to the decreased cell mediated immunity in these subjects. Poor cell mediated immunity

(commonly seen in HIV - positive) results in reduced granuloma formation with the resultant reduced caseation, liquefaction and eventually reduced cavitation[26]. The greater occurrence of cavities in HIV - negative PTB subjects is due to the increased inflammatory response in this group[13] As Tripathy et al[26] showed, cavity formation is observed in patients with higher CD4 counts, indicating that cell mediated immunity is required for cavity formation. They also reported that the right sided upper lobe cavitory lesions were more prevalent in subjects with HIV - negative PTB whereas in the present study right sided upper lobe cavitory lesions were prevalent in both groups. Aguwa et al[8] and Ahmadi et al[13] noted that HIV - negative PTB subjects had more of right upper lobe cavitory lesions whereas HIV - positive PTB subjects had more of mid/lower zone cavities. Patel et al[27] reported bilateral upper lobe involvement in HIV - positive PTB subjects. The differences in the cavitory locations in HIV - positive PTB subjects may still be related to the level of cell mediated immunity in these subjects at the time of presentation. The CD4 count or viral load assay would have helped to elucidate these findings but was not done for the study subjects. The study by Atalabi et al[28] shows no significant statistical difference in the chest radiographic pattern between children with different levels of immunosuppression. This finding might not be unrelated to the fact that the CD4 percent results were obtained in less than half of the subjects and the study was on children rather than adult.

The low prevalence of miliary opacities (2.2%) in HIV - positive PTB subjects in the present study is in agreement with the findings of Aguwa et al[8] (0.5%) and Nwonwu et al[11] (0 %). Ahidjo et al[13] and Ahmadi et al[11] reported a higher prevalence of 20.0% and 17.0% respectively.

In present study a prevalence of 12.2% for hilar lymphadenopathy was observed in the HIV - positive PTB subjects. It is in keeping with the findings of Ahidjo et al[13] and Ahmadi et al[11] who reported a prevalence of 8.3% and 26.4% respectively. However, Nwonwu et al[15] reported a lower prevalence of 2.6%. Aguwa et al[24] combined hilar and mediastinal shadows and reported a prevalence of 55.2% in HIV - positive PTB subjects. Their higher prevalence may be due to the fact that the phrase "hilar and mediastinal shadows" may include hilar lymphadenopathy, hilar and perihilar opacities.

Reticulonodular opacities of 13.9% was noted among HIV - positive PTB subjects in this study while Ahidjo et al[13] and Kisembo et al[29] reported prevalence of 3.3% and 45.0% respectively. Nwonwu et al[15] were ambiguous in their description of reticulonodular opacities: (they reported prevalences of 3.4% and 2.6% for reticulonodular and patchy reticulonodular opacities respectively), Aguwa et al[24] and Ahmadi et al[11] did not document reticulonodular opacities. In the present study, a prevalence of 13.0% for pleural effusion was noted among HIV - positive PTB as against 21.7% in HIV - negative PTB subjects ($p=0.014$). This corroborates the study of Badie et al¹⁷ (13.0% vs 23.5%), but differs from the findings of Aguwa et al[11] (25.7% vs 21.3%), Ahmadi et al[11] (32.4% vs 8.2%) and Awil et al[30] (23.0% vs 11.0%). Ahidjo et al⁸ who studied HIV - positive PTB subjects only, noted a prevalence of 16.7% for pleural effusion. Volume loss was seen more in HIV - negative PTB subjects (9.1% vs 27.0%) in this study. The same trend was noted in all the other studies[11,23,30] although values of Aguwa et al[24](45.9% vs 47.0%) were significantly higher. No reasons were proffered by the various authors for their findings. However the differences noted in the various studies above might not be unrelated to the state of cell mediated immunity in the respective subject groups [31-32].

It is, therefore, important to state that the radiological features of PTB in HIV - positive subjects have not been able to demonstrate a clear distinct pattern when compared with HIV - negative PTB subjects.

5. CONCLUSION

Chest radiological features which included patchy opacities, hilar and perihilar opacities were more prevalent in HIV - positive PTB subjects when compared with control. Patchy opacities are the most common feature in HIV - positive PTB subjects followed by cavitory lesions.

The findings showed that HIV - positive PTB subjects presented with more patchy opacities, hilar and perihilar opacities in keeping with primary (non-immune) pattern, in contrast to HIV - negative PTB subjects presenting with more of cavitory lesions and volume loss in keeping with secondary (immune) pattern.

6. RECOMMENDATION

Chest radiography is still relevant as a diagnostic modality for PTB especially in HIV - positive subjects. Patchy opacities with or without cavitory lesions should raise the suspicion of PTB in HIV - positive subject.

Although in present study there were no CD4 counts or viral loads data, further study is recommended to evaluate and correlate the CD4 counts or viral loads data with chest x-ray findings in HIV - positive PTB subjects.

CONSENT

Informed consent was obtained from both groups after adequate and clear explanation of the objectives of the study. Subjects were assured of the confidentiality of information obtained while their names were not included in the data sheet.

ETHICAL APPROVAL

Ethical approval for this study was granted by the Ethics and Research Committee of the University of Nigeria Teaching Hospital Enugu with certificate no: NHREC/05/01/2008B-1RB00002323.

COMPETING INTERESTS

Authors have declared that no competing interests exist.

REFERENCES

1. Umar MS, Daniel SV, Suwaid MA, Luntsi GL, Jubrin Y, Zira JD Chest radiographic findings of pulmonary tuberculosis in human immunodeficiency virus-seropositive patients in a teaching hospital in Kano Northwest, Nigeria West Afr J of Radiol 2020;27(1):27-32. DOI: 10.4103/wajr.wajr_33_18
2. Thorve SM, Patil N, Vora A. To study the incidence of pulmonary tuberculosis in newly diagnosed HIV patients. Asian Pac J Health Sci. 2017;4:137-9. DOI: 10.21276/apjhs.2017.4.1.22
3. Wetscherek MTA, Sadler TJ, Lee JYJ, Maria S, Babar JL. Active pulmonary tuberculosis: Something old, something new, something borrowed, something blue. Insights Imaging. 2022;13(3).

- Available:<https://doi.org/10.1186/s13244-021-01138-8>
4. Obeagu EI, Onuoha EC. Tuberculosis among HIV Patients: A review of Prevalence and Associated Factors. *Int. J. Adv. Res. Biol. Sci.* 10(9):128-134. DOI:<http://dx.doi.org/10.22192/ijarbs.2023.10.09.014>.
 5. Yang Q, Han J, Shen J, Peng X, Zhou L, Yin X. Diagnosis and treatment of tuberculosis in adults with HIV. *Medicine (Baltimore)*. 2022;101(35):e30405. DOI: 10.1097/MD.00000000000030405. PMID: 36107594; PMCID: PMC9439776.
 6. Nel M, Franckling-Smith Z, Pillay T, Andronikou S, Zar HJ. Chest Imaging for Pulmonary TB-An Update. *Pathogens*. 2022;11(2):161. DOI: 10.3390/pathogens11020161. PMID: 35215104; PMCID: PMC8878790.
 7. Said K, Verver S, Kalingonji A, Lwilla F, Mkopi A, Charalambous S, et al. Tuberculosis among HIV-infected population: Incidence and risk factors in rural Tanzania. *Afr Health Sci* 2017;17: 208-15. DOI: 10.4314/ahs.v17i1.26.
 8. Nwonwu EU, Oyibo PG, Imo AOC, Ndukwe CD, Obionu CN, Uneke CJ. Pulmonary Tuberculosis in HIV positive and HIV Negative adult patients in South-Eastern Nigeria. *African Journal of Respiratory Medicine*. 2008;3:520-523.
 9. Nadia A, Edith A, Karen B, Penny E, Paula IF, Einar H. Eds. *Management of Tuberculosis: A Guide to the Essentials of Good Practice*. 6th Ed. Paris: International Union against Tuberculosis and Lung Diseases. 2010;84.
 10. Frey V, Phi Van VD, Fehr JS, Ledergerber B, Sekaggya-Wiltshire C, Castelnuovo B. Prospective evaluation of radiographic manifestations of tuberculosis in relationship with CD4 count in patients with HIV/AIDS. *Medicine (Baltimore)*. 2023;102(7):e32917. DOI: 10.1097/MD.00000000000032917. PMID: 36800631; PMCID: PMC9935974.
 11. Ahmadi F, Salmanzadeh S, Kimyai M. Comparison the radiologic findings of pulmonary tuberculosis among HIV seropositive patients. *Jundishaper J Microbiol*. 2012;5:421-423.
 12. Araoye AO. Research methodology with statistics for health sciences. Ilorin: Nathadex. 2003;120-125.
 13. Ahidjo A, Yusuph H, Tahir A. Radiographic Features of Pulmonary Tuberculosis among hiv patients in Maiduguri Nigeria. *Annals of African Medicine*. 2005;4:7-9.
 14. Zubairu I, Musa B. Prevalence and predictors of tuberculosis coinfection among hiv-seropositive patients attending the Aminu Kano Teaching Hospital, Northern Nigeria. *J Epidemiol* 2009;19(2):81-87.
 15. Nwonwu EU, Oyibo PG, Imo AOC, Ndukwe CD, Obionu CN, Uneke CJ. Pulmonary Tuberculosis in HIV Positive and HIV Negative Adult Patients in South-Eastern Nigeria. *African Journal of Respiratory Medicine* 2008;3:520-523. Available:<http://indexmedicus.afro.who.int/iah/fulltext/ajrm/mar08/ajrm-2023.pdf> Accessed on: 17th July 2014.
 16. Uneke CJ, Alo MN. Rising cases of smear positive pulmonary tuberculosis in Southern Nigeria:the Public Health Implication. *Afr J Respir Med*. 2006;1:11-14.
 17. Saidu SA, Makusidi AM, Njoku CH. Chest radiographic findings in sputum smear positive pulmonary tuberculosis as seen in Usman Danfodiyo University Teaching Hospital Sokoto, Nigeria. *Bo Med J* 2013; 10:20-24.
 18. Zhou Y, Li T, Lin S. Chen D. Du Y, Chen J et al. Characteristics and treatment outcomes of co-infected tuberculosis patients with human immunodeficiency virus in Southeast China, 2012–2021. *BMC Infect Dis*. 2023;23:528. Available:<https://doi.org/10.1186/s12879-023-08501-8>.
 19. Erinle SA. An Appraisal of the radiological features of pulmonary tuberculosis in ilorin. *Niger Postgrad Med J* 2003;10:264-9.
 20. Idoko JA, Anteyi EA, Idoko LO. HIV and Associated TB in Jos, Nigeria. *Nigeria Medical Practitioner*. 1994;28:24-50.
 21. Affusim CA, Kesieme E, Abah VO. The pattern of presentation and prevalence of tuberculosis in HIV - seropositive patients seen at Benin City Nigeria. *ISRN Pulmonology*.2012;2012. Available:<http://www.dx.doi.org/10.5402/2012/326572>. Accessed on 17th July 2014.
 22. Oriekot A, Sereke SG, Bongomin F, Bugeza S, MuyindaZ. Chest X-ray findings in drug-sensitive and drug-resistant pulmonary tuberculosis patients in Uganda *J Clin Tuberc Other Mycobact*

- Dis. 2022;27:100312.
DOI: 10.1016/j.jctube.2022.100312
PMCID: PMC8958542 PMID: 35355939.
23. Zubairu I, Musa B. Prevalence and predictors of tuberculosis coinfection among hiv-seropositive patients attending the aminu kano teaching hospital, Northern Nigeria. J Epidemiol 2009;19(2):81-87.
24. Aguwa EN, Agwuna KK, Aghaji MN, Okoye IJ. Chest radiographic findings in sputum linear positive tuberculosis patients and human immunodeficiency virus / tuberculosis Co - Infected Patients Treated in a Chest Unit, Enugu, Nigeria. West Afr J of Radiol. 2007;14:11-15.
25. Baidie BM, Izadi MMM, Alijani MAN, Rasoolinejad M. Comparing radiological features of pulmonary tuberculosis with and without HIV Infection. J AIDS Clinic Res 2012;3:188.
DOI: 10.4172/2155-6113.1000188.
Accessed on: 18/4/2014.
26. Tripathy S, Menon P, Joshi DR, Pati U, Gadkari DA, Paranjape RS. Preliminary observations on lymphocyte subpopulations in HIV seropositive and HIV seronegative tuberculosis patients in Pune, India. Indian Journal Medicine Research 2000;111:195-8.
27. Patel AK, Rami KC, Ghanchi FD. Radiological manifestations in patients of pulmonary tuberculosis with HIV. National Journal of Medical Research. 2012;2:420 – 422.
28. Atalabi MO, Oladokun R, Adedokun B, Obajimi MO, Osinisi K. Baseline chest radiographic features among antiretroviral therapy naive human immuno-deficiency virus positive children in a pediatric care program. West Afr J Radiol. 2012;19:5-10.
29. Kitembo HN, Boon SD, Davis JL, Okello R, Worodria W, Cattamanchi A, Huang L, Kawooya MG. Chest radiographic findings of pulmonary tuberculosis in severely immunocompromised patients with the human immunodeficiency virus. Br J Radiol. 2012;85(1014): e130-9.
DOI: 10.1259/bjr/70704099
Epub 2011 Oct 5. PMID: 21976629; PMCID: PMC3474111.
30. Awil PO, Bowlin SJ, Daniel TM. Radiology of pulmonary tuberculosis and human immunodeficiency virus infection in Guru Uganda. European Respiratory Journal 1997;10: 615-618.
PMID: 9072994.
31. Elsayed n, albibi h, msawah s, asiri o. Radiological diagnosis of pediatric pulmonary infections and follow up protocols. Asian J. Med. Health. 2021;19(5):45-5.
Accessed on:2024 may 21
Available:<https://journalajmah.com/index.php/ajmah/article/view/542>
32. Heuvelings cc, bélard s, andronikou s, lederman h, moodley h, grobusch mp, zar hj. Chest ultrasound compared to chest x-ray for pediatric pulmonary tuberculosis. Pediatric Pulmonology. 2019;54(12):1914-20.

© Copyright (2024): Author(s). The licensee is the journal publisher. This is an Open Access article distributed under the terms of the Creative Commons Attribution License (<http://creativecommons.org/licenses/by/4.0>), which permits unrestricted use, distribution, and reproduction in any medium, provided the original work is properly cited.

Peer-review history:
The peer review history for this paper can be accessed here:
<https://www.sdiarticle5.com/review-history/117904>