



# Fibroadenoma Arising from Axillary Accessory Breast: A Case Report

Nurfarah Nadhira Fadhil <sup>a\*</sup>, M. Trinyanasuntari <sup>a</sup>, Mohamad Rafie MK <sup>b</sup>,  
S. Shalini <sup>c</sup> and Sadhana Mahamad <sup>a</sup>

<sup>a</sup> Breast and Endocrine Unit, Department of Surgery, Hospital Putrajaya, Putrajaya, Malaysia.

<sup>b</sup> Pathology Department, Hospital Putrajaya, Putrajaya, Malaysia.

<sup>c</sup> Radiology Department, Hospital Putrajaya, Putrajaya, Malaysia.

## Authors' contributions

This work was carried out in collaboration among all authors. All authors read and approved the final manuscript.

## Article Information

### Open Peer Review History:

This journal follows the Advanced Open Peer Review policy. Identity of the Reviewers, Editor(s) and additional Reviewers, peer review comments, different versions of the manuscript, comments of the editors, etc are available here: <https://www.sdiarticle5.com/review-history/89705>

Case Report

Received 08 August 2022

Accepted 12 October 2022

Published 17 October 2022

## ABSTRACT

Fibroadenoma is one of the most common breast lesion. It can usually be found in the upper outer quadrants where most breast parenchyma is located. The location of fibroadenomas involving the accessory breast is, however, uncommon. There are clinical significance in accessory breast tissues being affected by the same diseases and alterations that compromise a typical breast tissue. The diagnostic (mammography, ultrasonography, cytology and biopsy) and therapeutic protocol for an accessory breast tissue is prudent in detecting early malignancies. We report a case of fibroadenoma found in accessory breasts.

**Keywords:** Accessory breast; ectopic breast; axillary breast; fibroadenoma; case report.

## 1. INTRODUCTION

“Accessory breasts, also known as polymastia, supernumerary breasts, or mammae erratae, is the condition of having ectopic breast tissue in addition to normal breasts. It occurs along the

thoracoabdominal region of the milk line (67%), which then extends down to the groin, of which the commonest site is axilla” [1]. Axillary accessory breast tissue is a cause of anxiety among women for fear of malignant change. The clinical presentation of accessory breast may be

\*Corresponding author: E-mail: faradhira.fadhil@gmail.com;

asymptomatic or may present with pain, restriction of arm movement, cosmetic problems and anxiety in the premenstrual phase [2]. "About 2% to 6% of females and 1% to 3% of males are affected by this condition, a third of whom have more than one area of supernumerary tissue growth" [3,4]. Axillary tumours have many differential diagnoses ranging from benign to malignant, and fibroadenoma arising from the axillary accessory breast has rarely been described in the English literature. We describe the clinical, radiological and pathological finding relating to a rare case of fibroadenoma arising in an axillary accessory breast.

## 2. CASE PRESENTATION

A 19-years-old Chinese female presented to the office with huge swelling over the right axilla for the duration of 6 months, with the swelling being progressively increasing in size in the initial 3 months period. She does not otherwise complain of any tenderness, discharge, or notable skin changes.

Patient is noted to be a single, nulliparous female. Her paternal grandmother has an unknown history of cancer, and was deceased at the age of 82 years old.

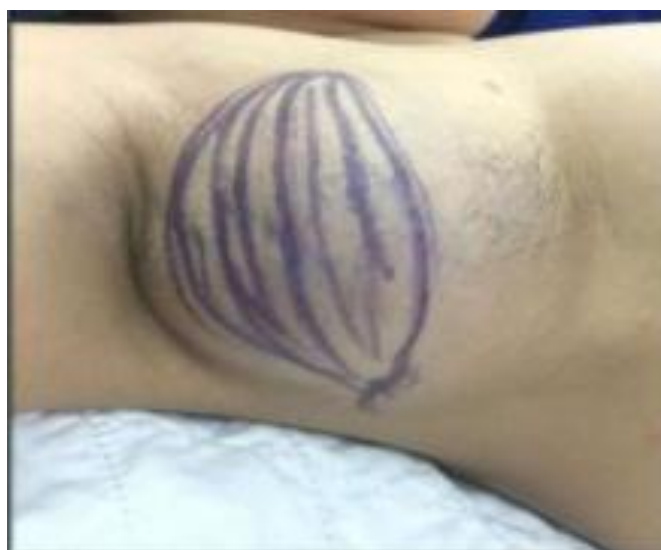Upon examination of the right axilla, there is a 6cmx5cm swelling (Fig. 1), which upon palpation noted to be firm, with well-defined borders,

mobile, non tender, and was not fixed to the skin or the underlying muscles. Contra-lateral axilla was clinically unremarkable. Examination of both breasts revealed no lump palpable. No skin changes or discharge noted at the time of examination from either in normal or accessory breast.

Ultrasound findings of the breast revealed the presence of a large, well marginated, ellipsoid, hypo-echoic lesion within the right axilla, measuring 3.4x5.7 cm (Fig. 2a and 2b). This lesion displays uniform echogenicity, with its transverse diameter larger than the AP dimension, and no posterior shadowing or foci of calcification within it. On color doppler examination of the lesion, there is peripheral and intralesional vascularity demonstrated (Fig. 2c). Sonographic findings are in keeping with a benign breast lesion, features suggestive of a fibroadenoma. Presence of thin rim of breast parenchymal tissue seen along the margins of this large lesion.

Aside from this large lesion, there are also small hypo-echoic nodules in the right breast, at 12 and 8 o'clock, measuring 0.5x0.7 cm and 0.4x0.7 cm (APxW) respectively. Sub-centimeter nodes seen in the right axilla.

No focal parenchymal lesions noted in the left breast. No enlarged or suspicious axillary nodes.



**Fig. 1. Lump and surgical landmark prior to surgery**

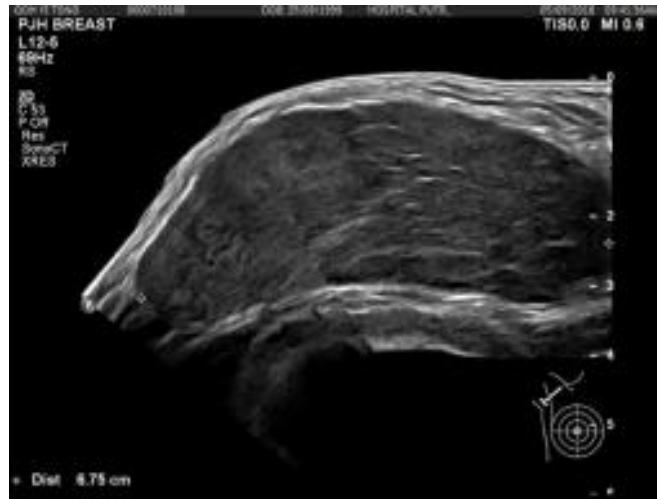


Fig. 2a. Ultrasound image of right axilla

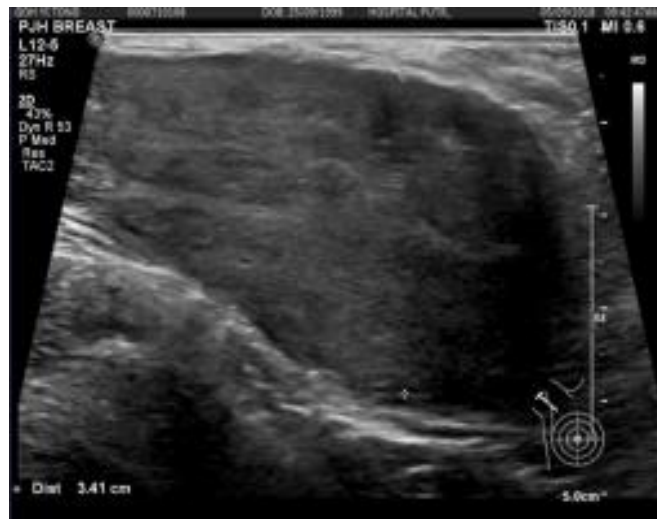

Fig. 2b. Ultrasound image of right axilla

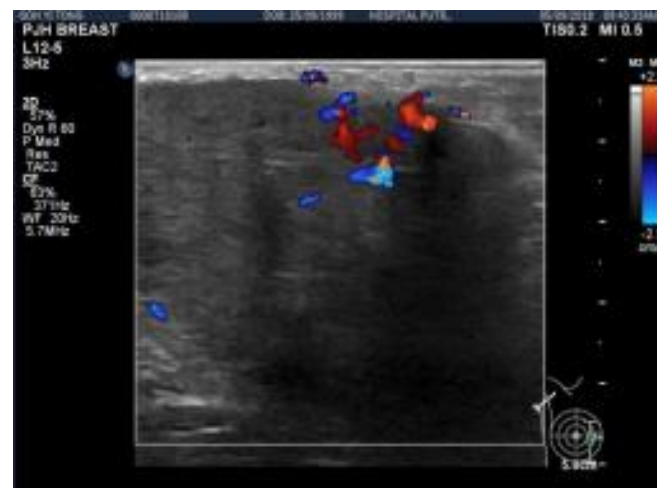

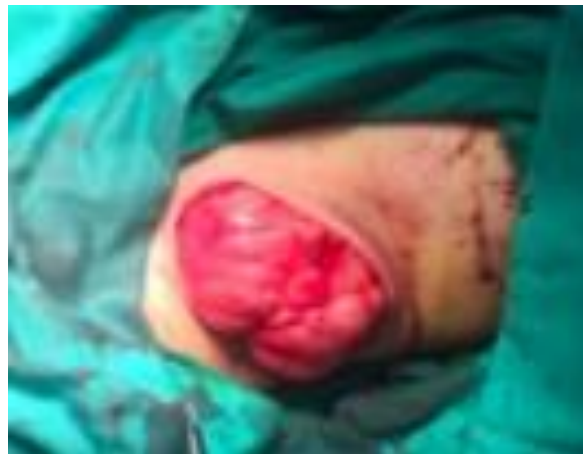Fig. 2c. Internal vascularity of right axilla

Ultrasound-guided core needle biopsy was proceeded to be performed. Procedure was done under aseptic technique under local anaesthesia- a total of 4 ml Lignocaine 2% was infiltrated along the projected biopsy track. Stab incision using 14G needle was made at the axillary tail and two passes rendered. Good core specimens was obtained and no immediate complications encountered during and after the procedure. HPE of the biopsy sample was resulted to be fibroadenoma.


After the explanation of the therapeutic choices, the patient opted for the excision of the axillary node. The surgical area was firstly cleaned and draped. An incision was made over the lump at the right axillary region. There noted to be a

large right accessory breast mass at the right axillary region (Fig. 3a). The right axillary fibroadenoma was proceeded to be excised as a whole, measuring 11 cm x 8 cm, weighing 146g (Fig. 3b). Hemostasis was secured well. One drain inserted and subsequently removed at day 3 post operatively.

Histologically, the tumour was diagnosed as fibroadenoma arising from the axillary accessory breast. Microscopically the tumour is seen as a well circumscribed lesion composed of proliferation of benign ductal epithelium with fibro-myxoid stroma. A few ducts are compressed into slit-like spaces. There is no cellular atypia or evidence of malignancy seen.

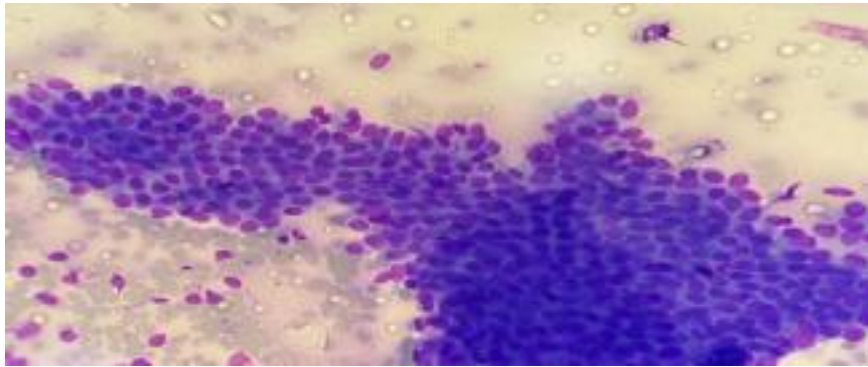


**Fig. 3a. Intraoperative section of the lump**

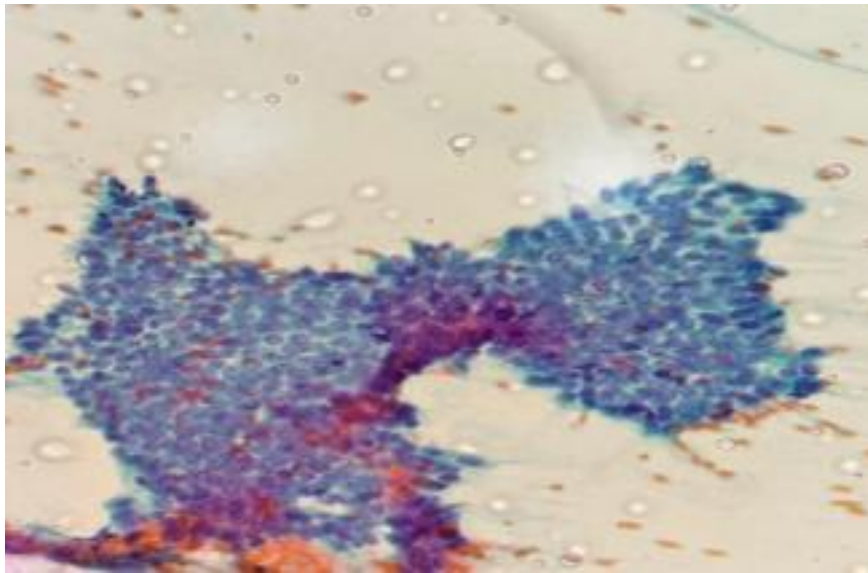


**Fig. 3b. The description of the lump excised**



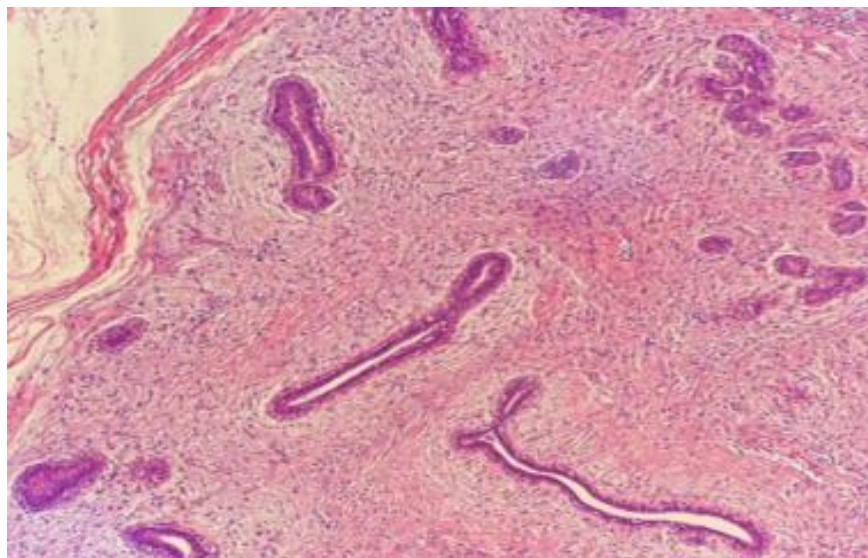


(4a)



(4b)

**Fig. 4a and 4b. Fine needle aspiration Cytology (FNAC) show cellular smears composed of cohesive clusters of benign ductal and myo-epithelial cell**



**Fig. 4c. Microscopic: H&E (x100)**

The patient has had no local recurrence at 2 years after excision of the tumour. Patient was seen in office for follow up with no history of further swelling. Clinical examination of bilateral breasts and axilla shows well-healed scar at right axilla with no palpable lump or lymph nodes felt.

### 3. DISCUSSION

Ectopic breast arises in 1-6% in the general population [5]. Reportedly, it is twice as common in female patients as in male patients [6]. "Ectopic breast tissue is usually found in proximity to the normal breast, most commonly in the axilla. Similar to those seen in normally located breast tissues, ectopic breast tissue is equivalently subjected to the same hormonal response and is at risk of developing benign and malignant pathologic processes, which includes fibrocystic disease, fibroadenoma, intraductal papilloma, lactating adenoma and carcinoma" [7,8].

Fibroadenomas of the breast account for approximately 12% of all palpable symptomatic breasts. The highest incidence of fibroadenoma in the breast is between the ages of 20 and 30 years of age. The most predominant location of fibroadenomas occur in the upper outer quadrants where most breast parenchyma is located. It is otherwise rarely described to be located in the axillary supernumerary or ectopic breasts- the exact incidence of which is not reported in various literature review. This is the only incidence of fibroadenoma in axilla accessory breast at our centre for the past 20 years of surgical practice.

"Clinically, although fibroadenomas are generally not painful, they can be associated with some degree of tenderness. The lumps are felt classically round or oval in shape, firm and rubbery in consistency, smooth, and very mobile; hence their common name - a breast mouse. They can vary in size, ranging from very small to giant fibroadenomas" [9,10].

In light of this, clinical accuracy of fibroadenomas is therefore limited, even in experienced hands. Several studies have shown that a clinical diagnosis of fibroadenoma is correct in only a half two-thirds of the cases [8]. Despite this, clinical assessment of breast mass or tumours remain an important component of the triple test, and plays a role in clinical surveillance of women with a proven fibroadenoma who choose non-surgical management.

Sonographically, fibroadenomas typically appear as oval, well-circumscribed, uniformly hypo-echoic masses with echogenic, thin fibrous internal septations and variable posterior features. The posterior features are dependent on the composition of the lesion. Therefore, lesions with solid higher hyaline content display posterior acoustic shadow, whereas lesions with epithelial dominance exhibit posterior enhancement.

Presence of an echogenic rim, or pseudo-capsule, can sometimes be seen surrounding the lesion, and is usually secondary to a compression of adjacent breast stroma. There is also internal vascularity in up to 80% on Doppler imaging.

In the presence of atypical features, i.e. irregularity of margins, microlobulations or indistinct borders, a biopsy was then performed for histopathological confirmation and reported to be fibroadenomas.

The key message is that, even in young women, all women with discrete masses should have imaging and fine needle aspiration or core biopsy to be able to exclude the possibility of malignancy.

### 4. CONCLUSION

Ectopic breast is common in masses in the axilla and has the risk of developing into malignant and benign tumours. One of the benign lesions noted to be of possibility includes the diagnosis of fibroadenoma. However, it is to note that its location in the axilla is rare. This case report underscores the need for careful workup and treatment for masses along the milk line including the axilla, as there is a risk of malignant transformation.

### CONSENT AND ETHICAL APPROVAL

Ethical approval from Clinical Research Centre of Hospital Putrajaya and written consent from the patient were obtained.

### ACKNOWLEDGEMENT

The authors thank the Ministry of Health, Malaysia for their valuable support and the utmost privilege to publish this article.

### COMPETING INTERESTS

Authors have declared that no competing interests exist.

## REFERENCES

1. Patel PP, Ibrahim AM, Zhang J, Nguyen JT, Lin SJ, Lee BT. Accessory breast tissue. *Eplasty*. 2012;2-3.
2. Arora BK, Arora R, Aora A, Singh K. Axillary accessory breast: Presentation and treatment. *Int Surg J*. 2016;3:2050-3.
3. Houssami N, Cheung MN, Dixon JM. Fibroadenoma of the breast. *The Medical Journal of Australia*. 2001;174(4):185-188.
4. Tiwary SK, Kumar P, Khanna AK. Fibroadenoma in axilla: another manifestation of ectopic breast. 2015;209-535.
5. Cheong JH, Lee BC, Lee KS. Carcinoma of the axillary breast. *Yonsei Medical Journal*. 1999;40(3):290-293.
6. Gutermuth J, Audring H, Voit C, et al. Primary carcinoma of ectopic axillary breast tissue. *J Eur Acad Dermatol Venereol*. 2006;20:217–21.
7. Shin SJ, Sheikh FS, Allenby PA, Rosen PP. Invasive Secretory (juvenile) carcinoma arising in ectopic breast tissue of the axilla. *Arch Pathol Lab Med*. 2001; 125:1372–1375.
8. Coras B, Landthaler M, Hofstaedter F, et al. Fibroadenoma of the axilla. *Dermatol Surg*. 2005;31:1152–4.
9. Valdes EK, Boolbol SK, Cohen JM, et al. Malignant transformation of a breast fibroadenoma to cystosarcoma phyllodes: case report and review of the literature. *Am Surg*. 2005;71:348–53.
10. Bartsich SA, Ofodile FA. Accessory breast tissue in the axilla: classification and treatment. *Plastic and Reconstructive Surgery*. 2011;128(1):35e-6e.

© 2022 Fadhil et al.; This is an Open Access article distributed under the terms of the Creative Commons Attribution License (<http://creativecommons.org/licenses/by/4.0>), which permits unrestricted use, distribution, and reproduction in any medium, provided the original work is properly cited.

*Peer-review history:*  
*The peer review history for this paper can be accessed here:*  
<https://www.sdiarticle5.com/review-history/89705>