



Coronavirus Disease 2019 – Dengue Fever Coinfection: A Case Report

Mohammed Amod Al Kamarany ^{a,b,#*}, Ahmed Majam ^{a,ψ},
Khaled Suhail ^{a,ψ}, Abdullah Zuhairy ^{a,c,ψ} and Elham Alabsi ^{a,ψ}

^a Center of Tropical Medicine and Infectious Diseases (CTMID), Al-Thawara Public Hospital Authority, Hodeidah, Yemen.

^b Faculty of Clinical Pharmacy and Center of Tropical Medicine and Epidemiology Studies, Hodeidah University (CTMES – HU), Hodeidah, Yemen.

^c Sub National Health Cluster Coordinator, World Health Organization (WHO), Al Hudaydah Hub, Yemen.

Authors' contributions

This work was carried out in collaboration among all authors. Author MAAK wrote, revised and edited the final manuscript and responsible for summarizing all epidemiological and clinical data. Authors KS, AM, AZ and EA collected the data and supported outbreak investigation. All authors read and approved the final manuscript.

Article Information

DOI: 10.9734/IJPR/2023/v12i4234

Open Peer Review History:

This journal follows the Advanced Open Peer Review policy. Identity of the Reviewers, Editor(s) and additional Reviewers, peer review comments, different versions of the manuscript, comments of the editors, etc are available here: <https://www.sdiarticle5.com/review-history/101573>

Case Study

Received: 03/05/2023

Accepted: 05/07/2023

Published: 17/07/2023

ABSTRACT

A lot of coronavirus disease 2019 (COVID-19) related deaths were reported in Yemen about what risk factors contributing to this excess death? Hodeidah governorate at Western part of Yemen exposed to COVID-19 pandemic like other governorates in Yemen, adding to the current chronic diseases' problems and endemic of vector – borne diseases namely malaria and dengue. The aim of this case report is to explore more data about COVID-19 – dengue fever coinfection related deaths in Hodeidah, Yemen, with both infections cause high mortality rates. The case reported

Associated Professor in Pharmacology of Infectious, Epidemic Diseases and Tropical Medicine) and scientific consultant on COVID-19 humanitarian project in Hodeidah, Yemen and – Dean of CTMES – HU;

ψ Researcher in Master Public Health (MPH) Program;

*Corresponding author: Email: alkamarany@gmail.com;

here shows a 25-year-old male, cough, hypoxia, fever 38°C, difficult in breathing, and bleeding from nose as major of symptoms with oxygen saturation (O₂) of 70%, 30 ipm of respiratory rate (RR), 120/80 mmHg of blood pressure, and 120 bpm of heart rate (HR). The patient was diagnosed with bilateral asymmetrical consolidative change with ground glass opacification based X-ray, the leukocytosis, lymphopenia, neutrophilia, and thrombocytopenia were reported. The level of random blood sugar (RBS) was normal, increase in liver enzyme was observed. Mild increase in serum creatinine with C – reactive protein (CRP) was high reactivity with positive COVID-19 and hemorrhagic dengue fever. The patient passed away (death) within two hours in triage. In conclusion, the co-infections with other infection like dengue is of high concern and this is the first reported case of COVID-19 and dengue coinfection presented as stroke and highlights the complex context of diagnostic and therapeutic management in tropical settings such as Hodeidah, Yemen.

Keywords: COVID – 19; dengue; Hodeidah; Yemen.

1. INTRODUCTION

Coronavirus disease 2019 (COVID-19) is a respiratory disease caused by a single-stranded positive sense RNA virus that was first isolated in December 2019 after it emerged in Wuhan, China [1,2]. In Yemen, the first case was registered on April 10, 2020 in Hadhramout [3], with further cases later identified in other parts of the country as the disease spread. Hodeidah governorate lies in the western part of Yemen, and has been similarly exposed to the COVID-19 pandemic to other governorates in Yemen, adding to the ongoing chronic challenges in the region. Hodeidah is facing a complex spectrum of determinants of health, including poverty, illiteracy, food insecurity, malnutrition and multiple epidemics as well as humanitarian crises resulting from the armed war that has been ongoing since 2015. At the time of writing, no research has been conducted documenting the COVID-19 pandemic in Hodeidah, especially related to morbidity and mortality. Several other notable disease outbreaks included malaria, dengue fever [4-6], chikungunya [7], west – Nile virus [8], cholera [9], diphtheria [10-11] and measles [12-13] were reported in Hodeidah, Yemen. These are due to a high density of vectors in this region and endemic areas for malaria and dengue, previous study reported high prevalence of malaria – dengue coinfection (37%) [4]. Also, AL Kamarany et al reported 49 /505 cases (severe and critical) were confirmed based on RT – PCR [14-16] and 68.05 % of Hodeidah people exposure to COVID-19 infection based on immunological method [17]. Therefore, the aim of this case report is to explore more data about COVID-19 – dengue fever coinfection related death in Hodeidah, Yemen.

2. CASE PRESENTATION

The patient was received and assessed directly clinically in triage unit of COVID-19, isolation department, Center of Tropical Medicine and Infectious Diseases (CTMID), AL-Thawrah Public Hospital Authority, Hodeidah, Yemen. A 25-year-old male, cough, hypoxia, fever 38 °C, difficult in breathing, bleeding from nose as major of symptoms with 70% of oxygen saturation (O₂), 30 ipm of respiratory rate (RR), 120/80 mmHg of blood pressure, and 120 bpm of heart rate (HR)". Chest x-ray, complete blood count, C – reactive protein (CRP) were carried out. Also, the nasopharyngeal swab was collected and the COVID-19 was confirmed based on real time – polymerase chain reaction (RT-PCR). In addition, the dengue fever infection was tested based on rapid test (IgM). The patient was diagnosed, bilateral asymmetrical consolidative change with ground glass opacification and the lung involvement more than 50 %. Increase in white blood cells (leukocytosis) that was 26000 ×10⁹/L, lymphopenia (6%), neutrophilia (90 %), and thrombocytopenia (141 x 10³ /L) were reported, and a mild increase in hematocrit (Hct) was 47%. The level of random blood sugar (RBS) was normal (131 mg/dL), increase in liver enzymes (51 unit/L of Alanine transaminase (ALT), and 157 unit/L of Aspartate transferase (AST)). Mild increase in serum creatinine (1.6 mg/dL). On the other mean, increase the neutrophil 90/6 lymphocyte ratio (NLR) that was 15% as predication of severity of case with CRP was high reactivity (43 mg/dL) with positive COVID-19 infection and hemorrhagic dengue fever (coinfection). The patient was died within two hours in triage unit of COVID-19.

Table 1. Results of haematological parameters

Parameters	Values	Normal values [18,19]
RBC ($\times 10^9/L$)	5.5	3500-5000
Hb (g/dl)	16.5	12-15
Hematocrit (%)	45.3	35-45
WBC ($\times 10^9/l$)	26200	3.5 \pm 7.5
Neutrophil (%)	90	40-75
Lymphocyte (%)	6	20-45
Monocyte (%)	2	2-10
Eosinophil (%)	2	1-6
Basophil (%)	0	0-1
Platelets($\times 10^3/ul$)	141	150-450

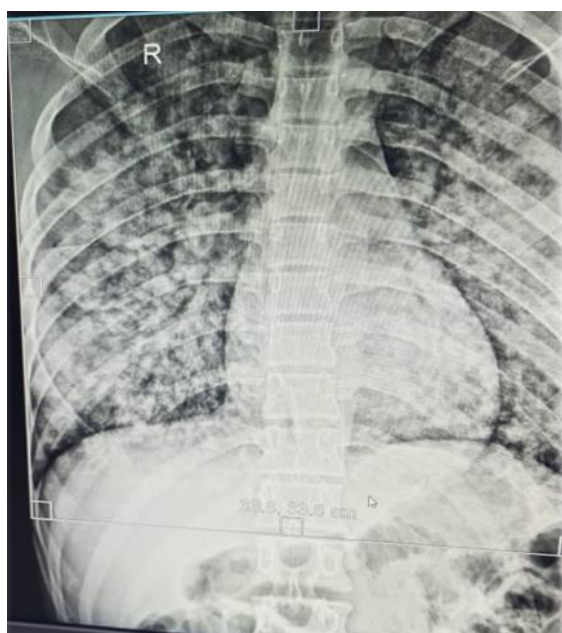


Fig. 1. Bilateral asymmetrical consolidative change with ground glass opacification seen in the mid and lower zone of lung field more prominent at periphery with no pleural effusion and the lung involvement was 60 %

Table 2. Results of biochemical parameters

Parameters	Values	Normal values [20]
RBS mg/dL	131	140-180
ALT unit/L	51	0-35
AST unit/L	157	0-37
Serum creatinine mg/dL	1.6	0.3 -1.3
Blood urea mg/dL	43	8-20
Na+ mmol/L	143	136-145
K+ mmol/L	5	3.5-5
CRP mg/L	43	0-8

3. DISCUSSION

The study focused on epidemiological and clinical features of COVID -19 – dengue fever coinfection in Hodeidah, Yemen (while the COVID-19 pandemic takes the world by storm, dengue-endemic regions risk developing a co-epidemic in COVID-19/dengue coinfection). Several cases were emerged in different countries. In Philippines reported a 38-year-old male patient with high-grade fever, with complaints of nausea, joint, and muscle aches, all characteristic symptoms of COVID-19 and dengue but was not severe, although the tests confirmed the infections to be “moderate to severe” and showed steady and rapid recovery [21]. Previous studies “in Latin America reported that coinfection with SARS-CoV-2 and dengue virus is associated with worse outcomes with significant morbidity and mortality. The similar clinical and laboratory features of each infection are a challenge in accurately diagnosing and treating cases. Establishing an early diagnosis could be the answer to reducing the estimated significant burden of these conditions” [22]. “Two cases were reported in Maldives , Case 1 was a 39-year old Asian male, presented on day 6 of dengue infection with warning signs. Case 2 was a 38-year old Asian male, was admitted on day 5 of illness with symptoms of acute respiratory infection . Evaluation of progressive leukopenia and thrombocytopenia showed positive dengue serology” [23]. Study identified “two pregnancies with dengue and COVID-19 co-infection; one ended with premature rupture of membrane and intrauterine growth restriction fetus, while the other one ended with maternal mortality and intrauterine fetal death. COVID-19 and dengue co-infection had worse outcomes regarding mortality rates, ICU admission, and prolonged hospital stay. Thus, wise-decision management approaches should be adequately offered to these patients to enhance their outcomes. Establishing an early diagnosis might be the answer to reducing the estimated significant burden of these conditions” [24]. “COVID-19 and dengue co-infection was associated with severe disease and fatal outcomes. The correct diagnosis and treatment of co-infection poses a substantial challenge due to the overlapping clinical and laboratory parameters. Therefore, confirmative diagnostic tests are necessary for accurate and timely diagnosis and patient management” [25]. Finally, Old age and co-morbidity with non-communicable diseases may be contributing factors to excess deaths among SARS-CoV-2 patients. Co-infections with other

infections like dengue is of high concern in Hodeidah, Yemen [26,27].

4. CONCLUSION

The co-infections with other infection like dengue is of high concern and this is the first reported case of COVID -19 and dengue coinfection presented as stroke and highlights the complex context of diagnostic and therapeutic management in tropical settings such as Hodeidah, Yemen and may be contributing factor to excess deaths.

FUNDING

This study was funded by Center of Tropical Medicine and Infectious Diseases (CTMID), Al-Thawara Public Hospital Authority, Hodeidah, Yemen in collaboration with Health and Nutrition Program, Save the Children International (SCI), Hodiedah Office, Yemen Country and Hayel Saeed Anam Companies Group (HAS). The publication fee is not supported in this fund.

CONSENT

As per international standards or university standards, Participants' written consent has been collected and preserved in Medical File. The raw data are secured in CTMES – HU and CTMID, Hodeidah, Yemen.

ETHICAL APPROVAL

The studies involving human participants were reviewed and approved by the Ethics Committee of CTMES – HU, Hodeidah, Yemen.

ACKNOWLEDGEMENTS

The authors would like to thank the supervisor and medical staff of the COVID-19 isolation department, Molecular Biology Unit, Center of Tropical Medicine and Infectious Diseases (CTMID), AL Thawara Public Hospital Authority, Hodeidah, Yemen for their fruitful assistance. Also to thank for Dr. Abdultif Magram in Diagnostic Advanced AL Razi Center, Hodeidah, Yemen for supporting the radiological diagnosis.

COMPETING INTERESTS

Authors have declared that no competing interests exist.

REFERENCES

1. Lai CC, Shih TP, Ko WC, Tang HJ, Hsueh PR. Severe acute respiratory syndrome coronavirus 2 (SARS-CoV-2) and coronavirus disease-2019 (COVID-19): The epidemic and the challenges. *Int J Antimicrob Agents*. 2020;55(3): 105924. Epub 2020 Feb 17. PMID: 32081636, PMCID: PMC7127800 DOI: 10.1016/j.ijantimicag.2020.105924
2. Gundlapally J, et al. In search of novel coronavirus 19 therapeutic targets. *Helix*. 2020;10:02 DOI: 10.29042/2020-10-2-01-08
3. Novel Coronavirus COVID-19". Yemen Supreme National Emergency Committee for Covid-19. Retrieved 9 December; 2020.
4. Al-Areeqi A, et al. epidemiological characteristic of malaria coinfecting with dengue fever in Hodeidah, Yemen. *International Journal of Tropical Disease & Health*. 2020;40(3),1–10. Available: <https://doi.org/10.9734/ijtdh/2019/v40i330230>
5. Alahdal M, Al-Shabi J, Ogaili M, Abdullah QY, Alghalibi S, Jumaan AO, AL-Kamarany MA. Detection of dengue fever virus serotype – 4 by using one-step real-time RT-PCR in Hodeidah, Yemen. *Microbiology Research Journal International*. 2016;14(6):1–7. Available: <https://doi.org/10.9734/BMRJ/2016/24380>
6. Abdullah QY, Ogaili M, Alahdal M, AL-Kamarany MA. dengue fever infection in hodeidah, yemen: Risk factors and socioeconomic indicators. *British Biomedical Bulletin*. 2015; 3(1):58-65.
7. Malik MR, Mnzava A, Mohareb E, Zayed A, Al Kohlani A, Thabet AA, El Bushra H. Chikungunya outbreak in Al-Hudaydah, Yemen, 2011: Epidemiological characterization and key lessons learned for early detection and control. *J Epidemiol Glob Health*. 2014;4(3):203-11. DOI: 10.1016/j.jegh.2014.01.004 Epub 2014 Mar 15. PMID: 25107656; PMCID: PMC7333817
8. Yusuf Q, Al-Masrafi I, Al-Mahbashi A, Al-Areeqi A, Al-Kamarany MA, Khan AS. First Evidence of West Nile Virus in Hodeidah, Yemen: Clinical and Epidemiological Characteristics. *International Journal of TROPICAL DISEASE & Health*. 2019; 38(4):1-9.

- Available:<https://doi.org/10.9734/ijtdh/2019/v38i430190>
Available:<https://journalijtdh.com/index.php/IJTDH/article/view/30190>
9. Al Sheebani S, Al-Kamarany MA, Ghouth AB, Kamal A, Alaq M. Acute renal failure induced by cholera: outbreak of Hodeidah, Yemen, 2017. *European Journal of Pharmaceutical and Medical Research*. 2018;5(8):188–192.
10. Bin Ghouth A, et al. Community awareness about diphtheria prevention and control in Hodeidah, Yemen 2018. *International Journal of Tropical Disease & Health*. 2018;30(3):1-7.
Available:<https://doi.org/10.9734/IJTDH/2018/40750>
Available:<https://journalijtdh.com/index.php/IJTDH/article/view/20743>
11. Mohammed Amod AL-Kamarany and Ahmed Majam. Monitoring efficacy of benzyl penicillin in diphtheria treatment based on validated hematological analyzer in Hodeidah Outbreak , Yemen . *European Journal of Pharmaceutical and Medical Research*. 2019;6(4)52 – 57.
12. Abdo MS, AL Kamarany AM, Suhail KA, Majam AS. Vaccinationbased measles outbreak model with fractional dynamics. *Abhath Journal of Basic and Applied Sciences*. 2022;1(2):40-50.
13. Majam A, Mulhee N, Al Kamarany Amod . Measles Virus Infection Among Vaccinated and Unvaccinated Children in Hodeidah, Yemen , Workshop about Quality , Safety and Efficacy of Vaccines . 2023,19 – 20;15.
14. AL-Kamarany MA, Suhail KA, Majam AS, Abdulabari Alabsi E, Hamoud Dowbalah M, Mohammed Zohairy A. Epidemiological and Clinical features of COVID-19 in Hodeidah, Yemen. *International Journal of TROPICAL DISEASE & Health*. 2021;42(21):28–40.
Available:<https://doi.org/10.9734/ijtdh/2021/v42i2130550>
15. Suhail FA, Al Kamarany MA. Radiological features of COVID-19 patients in Hodeidah, Yemen. *Asian Journal of Research in Infectious Diseases*. 2021; 8(4):117-127.
Available:<https://doi.org/10.9734/ajrid/2021/v8i430256>
16. AL Kamarany , M. A., Abdulkarim , T., & Nasser , M. (2023). Biomolecular Features of COVID-19 in Hodeidah, Yemen. *Asian Journal of Biochemistry, Genetics and Molecular Biology*, 14(3), 29–38. Available: <https://doi.org/10.9734/ajbgmb/2023/v14i3317>
17. Al-Kamarany MA, Abdulkarim T. Immunological features of COVID-19 in Hodeidah, Yemen. *Asian Journal of Immunology*. 2023;6(1):76–84.
Available:<https://journalaji.com/index.php/AJI/article/view/97>
18. Al-Sheibani S, et al. Validation hematological analyzer for assay of erythrogram in Hodeidah City, Yemen. *Asian Hematology Research Journal*. 2018;1(1):1-8.
Available:<https://journalahrj.com/index.php/AHRJ/article/view/13188>
19. AL Kamarany Amod M. Validation of neutrophils - lymphocytes ratio for monitoring of therapeutic efficacy of covid - 19 in Hodeidah, Yemen. *The Second Conference for Laboratory Medicine*. 2021, 20 – 23:43-44.
20. American College of Physician (ACP) (2023). *Laboratory Values , U.S. traditional units are followed in parentheses by equivalent values expressed in S.I. units*. © 2011 – 2023 American College of Physicians. All Rights Reserved. 190 North Independence Mall West, Philadelphia, PA 19106-1572 Toll Free: (800) ACP.1915 · Local: (215) 351.2600
21. Prapty CNBS, Ahmed N, Araf Y, Yang Z, Zhai J, Hosen MJ, Zheng C. Coinfection of COVID-19 and dengue: A Case Report. *Front Med (Lausanne)*. 2022;27(9): 872627.
DOI: 10.3389/fmed.2022.872627
PMID: 35991668; PMCID: PMC9386617.
22. León-Figueroa DA, et al. COVID-19 and dengue coinfection in Latin America: A systematic review. *New Microbes New Infect*. 2022;49:101041.
DOI: 10.1016/j.nmni.2022.101041
Epub 2022 Oct 28
PMID: 36320316; PMCID: PMC9613782
23. Hilmy AI, Dey RK, Imad HA, Yoosuf AA, Nazeem A, Latheef AA. Coronavirus disease 2019 and dengue: two case reports. *J Med Case Rep*. 2021;15(1):171.
DOI: 10.1186/s13256-021-02707-7
PMID: 33771221; PMCID: PMC7995386
24. El-Qushayri AE, Kamel AMA, Reda A, Ghozy S. Does dengue and COVID-19 co-infection have worse outcomes? A systematic review of current evidence. *Rev Med Virol*. 2022;32(5):e2339
DOI: 10.1002/rmv.2339

- Epub 2022 Feb 25
PMID: 35213764; PMCID: PMC9111070
25. Tsheten T, Clements ACA, Gray DJ, Adhikary RK, Wangdi K. Clinical features and outcomes of COVID-19 and dengue co-infection: a systematic review. BMC Infect Dis. 2021;21(1):729. DOI: 10.1186/s12879-021-06409-9. PMID: 34340682; PMCID: PMC8327042
26. AL Kamarany MA, Al-Masrafi I, Ghouth AB, Suhail K, Majam A, Zuhairy A, Alabsi E. Outbreak investigation: First ten COVID – 19 Infection Related Deaths in Hodeidah, Yemen. Asian Journal of Research in Infectious Diseases. 2023;13(3): 19–27. Available:<https://doi.org/10.9734/ajrid/2023/v13i3268>
27. Majam Am, AL Kamarany Amood M, COVID -19 and Dengue Coinfection, Predication for Increasing the Mortality Rate: Case Report. The First Scientific Annual Conference of AL Thawara Public General Authority; 2021.

© 2023 AL Kamarany et al.; This is an Open Access article distributed under the terms of the Creative Commons Attribution License (<http://creativecommons.org/licenses/by/4.0>), which permits unrestricted use, distribution, and reproduction in any medium, provided the original work is properly cited.

Peer-review history:
The peer review history for this paper can be accessed here:
<https://www.sdiarticle5.com/review-history/101573>