

Traumatic Cataract

Achyut N. Pandey^{1*}

¹Department of Ophthalmology, VCSG Medical College and Research Institute, Srikot, Srinagar Garhwal, Uttarakhand-246174, India.

Author's contribution

The sole author designed, analyzed and interpreted and prepared the manuscript.

Article Information

DOI: 10.9734/OR/2017/32631

Editor(s):

(1) Stephen G. Schwartz, Department of Clinical Ophthalmology, Bascom Palmer Eye Institute, University of Miami Miller School of Medicine, USA.

Reviewers:

- (1) Gabor Nemeth, Borsod-Abaúj-Zemplén Country Hospital and University Teaching Hospital, Miskolc, Hungary.
(2) Thiago Gonçalves dos Santos Martins, Federal University of São Paulo, Brazil.
(3) Pankaj Sharma, Delhi State Cancer Institutes, Delhi, India.

Complete Peer review History: <http://www.sciencedomain.org/review-history/19627>

Review Article

Received 6th March 2017
Accepted 23rd May 2017
Published 20th June 2017

ABSTRACT

Traumatic cataract is more common in younger individuals. Traumatic cataract is an important cause of uniocular visual loss and is often sudden in onset. Traumatic lens damage may be caused by mechanical or non-mechanical injury. Traumatic cataract is an indication of intraocular lens (IOL) implantation in children. In trauma visual outcome depends on the interval from injury to the surgery. Early intervention provides better visual outcome and less chance of developing amblyopia and strabismus. Intraocular lens implantation for unilateral cataract in children has a definite role in correcting aphakia, resulting in good visual outcome and thus helping to maintain binocularity. This article explains the basic pathology involving traumatic cataract, pathogenesis and management.

Keywords: Amblyopia; rosette cataract; vossius ring; phacoemulsification.

1. INTRODUCTION

The eye is one of the delicate organs in the body. Like any other part of the body eyes are also not exempt from injuries inspite of the fact that they

are well protected by lids, projected margins of the orbit, the nose and a cushion of fat from behind. Ocular injury is an important cause of visual loss in children [1,2].

*Corresponding author: E-mail: achyutpandey@gmail.com;

Ocular trauma often leads to traumatic cataract along with damage to other ocular structures. Traumatic cataract is an important cause of unocular visual loss and is often sudden in onset. Traumatic lens damage may be caused by mechanical or non-mechanical injury. Traumatic cataract is an indication of intraocular lens (IOL) implantation in children. IOL implantation is usually performed for

- a) To preserve vision by optical correction.
- b) To prevent development of amblyopia.
- c) To preserve binocular single vision.
- d) To avoid the inconvenience of contact lens or glasses not only for the child but for the parents.
- e) To avoid aberrations of high power plus lenses used for aphakia.

The visual outcome after IOL implantation varies with extent of damage to the other ocular structures and post operative complications. Hence, in the present study an attempt has been made to evaluate the visual outcome of children with traumatic cataract after IOL implantation.

1.1 Lens Anatomy [3,4,5]

The lens is a transparent biconvex crystalline structure placed between iris and vitreous in a saucer shape depression the patellar fossa and supported by suspensory ligaments.

1.2 Traumatic Cataract [5,6]

A cataract is a clouding of the normally clear and transparent lens of the eye, which may prevent a clear image from forming on the retina. Both penetrating and concussion injuries can cause traumatic cataract.

They are the results of the sudden acceleration imparted by the impact of blunt force. Traumatic cataracts are frequently seen after direct blows on the eyeball. They occur in 60% of cases after minor concussion on the globe. The total effects upon the eyeball may be due to several factors like direct impact of the force upon the globe with its maximum effects at the point where blow is received. Transmitted force appearing as a wave of pressure when the eye is suddenly compressed traveling throughout its fluids contents in all directions sometimes with expulsive force, in which case the maximum damage may be at a point distant from actual place of impact (contre-coup). Indirect forces

whereby the globe is suddenly strikes against the elastic contents of the orbit and its resistant bony walls. The effect of the impact of the wave of pressure traversing the fluid contents of the eye by which, when the cornea was driven in, the aqueous was forced backward, driving in front of it, the lens and hurling the vitreous against the posterior pole.

1.3 Pathogenesis of Traumatic Cataract [7-12]

1.3.1 Proteins

The concentration of insoluble protein (albuminoids) remains stable, while soluble proteins are markedly decreased and their synthesis is decreased. A loss of beta crystalline fraction is always conspicuous and this involves diminution of protein sulphhydryl groups. The active soluble proteins give place to inactive substances thus tending to metabolic inertia. These changes occur after opacification of lens has developed. In later stages of development cataract proteolysis occurs where soluble proteins are broken down by enzymes. The amount of albuminoids is small in young lens fibers, in these practically all proteins are thus broken up. Complete hydrolysis increases the osmotic pressure some 400 times, initial effect is an enormous inhibition of water with a consequent swelling. This may be followed as diffusion proceeded by an almost complete disappearance of lenticular substance. If capsule ruptures, the proteases in aqueous as well as phagocytic cells reach fibers and these help to complete breakdown of proteins.

1.3.2 Peptides

Most important is glutathione. Decrease in all from of cataract.

1.3.3 Nucleotides

ATP, diphosphopyridine (DNPH) and triphosphopyridine nucleotide (TPNH) are decreased in cataract.

1.3.4 Total lipids

They are increased in cataract particularly free lipids (cholesterol). In later stage of opacification, free lipids may appear as visible crystalline deposits.

1.3.5 Inorganic materials

A calcium concentration is increased in cataracts. Molecular disturbance in the protoplasmic structures of cell. In the lens intracytoplasmic changes leading to fragmented and necrosis of cells of the capsular epithelium of the lens.

1.4 Types of Traumatic Cataract

- Total/diffuse
- Anterior capsular
- Posterior sub capsular
- Intumescent
- Ruptured anterior capsule with flocculent lens matter in anterior chamber.
- Partially absorbed.

2. LENTICULAR OPACITIES [13,14,15,16]

It occurs mainly due to imbibitions of aqueous and partly due to direct mechanical effects of the injury on the lens fibers.

A blunt injury may cause lens opacification either as an acute event or as a late sequelae. A concussion cataract may involve only a portion of the lens or the entire lens. Cataract results when the lens capsule ruptures by either a direct or countercoup injury. Rapidity of cataract formation depends on whether the lens capsule was ruptured. In the presence of rupture the lens becomes hydrated and cataractous within hours.

2.1 Vossius's Ring Opacity

A circular ring of brown pigments is seen on anterior lens capsule. It occurs due to striking of contracted pupillary margin against crystalline lens.

Discrete subepithelial opacities-Most common occurrence.

Sub epithelial disseminated traumatic opacities. It is similar to glaucomflecken.

Cobweb sub capsular opacity.

Traumatic rosette shaped opacity.

Rosette cataract is the most typical clinical picture following both concussion and perforating injuries. It occurs either in the presence of absence of a capsular tear.

2.1.1 Early rosette (Punctuate)

Sometimes it occurs in anterior capsule and at time in posterior capsule or in both simultaneously. Initially the first changes are the appearance of a carpet of fine fluid droplets lying between radiating lens fibers immediately under capsular epithelium. It appears as feathering lines of opacities along the star-shaped suture line, usually in posterior cortex.

2.1.2 Late rosette cataract

It occurs some years after the injury and is usually found lying deep in the cortex and in the nucleus. It develops in posterior cortex. Its sutural extensions are shorter and more compact than early rosette cataract.

2.1.3 Traumatic zonular cataract (Lamellar)

It usually follows an injury received in early youth and resembles lamellar cataract. Typical riders may present but peripheries of lens are clear.

2.1.4 Post traumatic atrophy of lens

It is characterized by thinning of lens substances. The shrinkage may be attributable partly to absorption of some of its substances or partly to disturbances of growth of new fibers owing to epithelial damage.

2.1.5 Presenile and senile lens changes

Coronary cataract, water cleft, punctuates cortical opacities and sclerotic nuclear opacities.

2.1.6 Diffuse (total) concussion cataract

It is rare, unless associated with rupture of capsule. In such cases a rapidly milkiness appears owing to imbibitions of aqueous in quantity, producing opacity resembling that following perforating wounds of lens. If tear is extensive swollen fibers may herniate out from opening protruding either into anterior chamber or vitreous.

2.1.7 Traumatic absorption of lens

It may occur sometimes in young children resulting in aphakia.

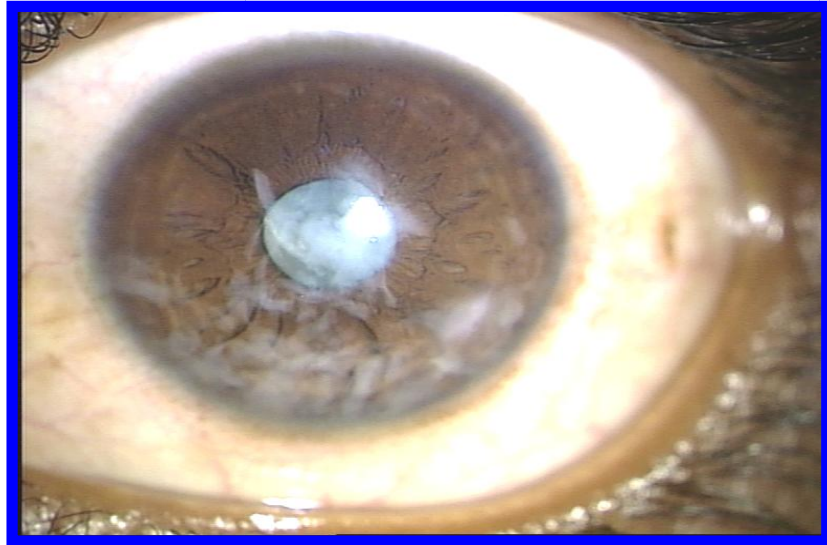

Fig. 1a. Wound of entry in penetrating injury with traumatic cataract – pre -operative

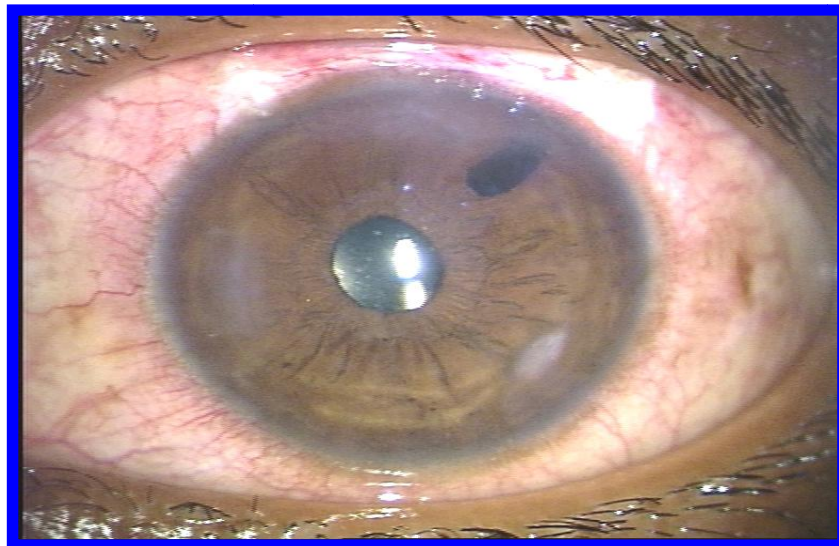


Fig. 1b. Penetrating injury with traumatic cataract – post-operative- PC IOL *in-situ*

2.1.8 Subluxation of lens

It may occur due to partial tear of zonules. The subluxated lens is slightly displaced in the pupillary area. On dilatation of pupil its edge may be seen. It depends upon the sites of zonular tear. Subluxation may be vertical (upward or downward) or lateral (nasal or temporal).

2.1.9 Dislocation of lens

It occurs when rupture of all the zonules is complete. It may be intraocular or extra ocular. Intraocular dislocation may be anterior (anterior

chamber) or posterior (into vitreous). Extraocular dislocation may be in the subconjunctival space (phakocele) or it may fall outside the eye.

2.1.10 Penetrating and perforating wound of eye [16,17]

Penetrating trauma is caused by high-velocity impacts. Penetrating injury is a single full-thickness wound of the eyewall caused by a sharp object. While perforating injury refers to two-full thickness wounds (one entry and one exit) of eye wall caused by sharp object or

missile. Any penetrating or perforating injury to anterior eye may be complicated by damage to ocular lens. They are common particularly among children at play. The cause can be knives, forks, needles, pins, sharp toys, glass piece, pen, pencils, nails, arrows, compasses, screw- drivers any sharp instruments and flying foreign bodies.

Various forms of cataract develop following a perforating injury. Lens damage can vary from a small rent in anterior capsule leading to a small localized cataract to a total cataract disruption with flocculent lens material filling the anterior

chamber. Capsular damage is invariable in such injuries, tear in capsule at first tends to gape and its edges roll outwards, while between them the lens fibers sometimes protrude mushroom like into anterior chamber. If healing proceeds, small cicatrix forms at site of rent with radiating traction folds of capsule. Localized change in the lens substance varying from small dots or linear opacities to cloud like masses.

- Rosette
- Total traumatic cataract
- Intumescent cataract
- Lacerated cataract.

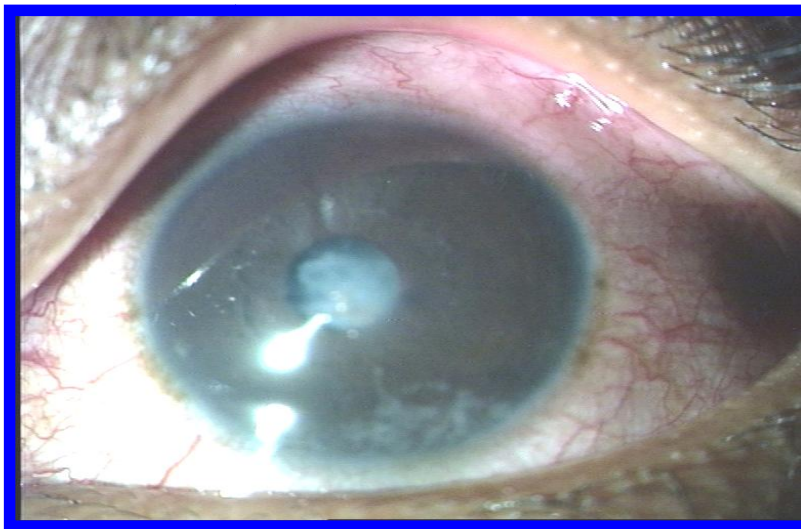


Fig 2a. Blunt injury with traumatic cataract –pre-operative

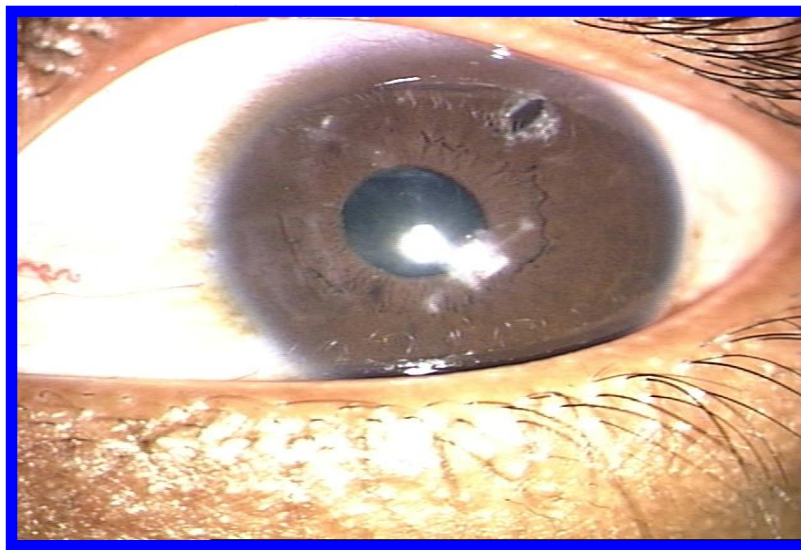


Fig. 2b. Blunt injury with traumatic cataract-post-operative- PC IOL *in-situ*

3. PEDIATRIC INTRAOCULAR IMPLANTATION [15,16]

When aphakic spectacles are provided, the image is enlarged, there are prismatic and aberrational effects, no accommodation, the field is limited with a roving ring scotoma all around, distance judgment is impaired and there is no prospect of binocular vision if the condition is unilateral. In children all these factors lead to a dense amblyopia. The implantation of unilateral intraocular lens in a child's eye was first performed by Choyce in 1958 followed by Binkhorst in 1959. IOL implantation is also indicated for bilateral and unilateral partial cataracts (congenital/ developmental), when it is found that vision is insufficient for school education or recently developed squint. It is the best way of providing better visual acuity and good chance of fusion for squinting eye. There are two major indications for IOL implantation in children. The first and most important is to preserve vision and prevent amblyopia. The second is the preservation of fusion. Extracapsular cataract extraction with IOL implantation provides satisfactory results in children with traumatic cataract. Associated posterior segment complications and development of PCO are the major obstacles to visual rehabilitation.

4. IOL IN TRAUMATIC CATARACT [17,18]

Traumatic cataract is an indication for IOL implantation in children. Intraocular lens implantation in children sometimes is very difficult. The problems are intensified and magnified if there is an additional factor of superimposed trauma. There is no gross change in outlook for satisfactory visual in young children with traumatic cataract. However traumatic cataract not complicated by severe damage to other ocular structure is definite indication for an early surgical intervention with IOL implantation. Also children's eyes have a tendency to exhibit increased inflammatory response to any injury. The presence of blood, lens, uveal elements and vitreous in anterior chamber stimulate severe Iridocyclitis, formation of synechiae, cyclitic and vitreous membranes. Amblyopic therapy in amblyopia prone patients and spectacles correction for all patients' aids in the restoration of visual function. If strabismus develops early surgery is indicated to restore a normal ocular alignment and secure the best possible peripheral if not central vision. The posterior intraocular lens should be implanted in eyes of

children 2 years of age or older. Corneal opacity and amblyopia were the most common causes of poor final visual acuity.

5. MANAGEMENT [16-19]

Stegmann believes that the prognosis for a traumatic cataract can be same as for a routine senile cataract if the traumatic cataract is handled appropriately. This excludes cases in which there is damage to the posterior segment, the vitreous has become cloudy, the retina is damaged from the same trauma or where infection has occurred. Traumatic cataract is an indication of IOL implantation in children. IOL either primary or secondary has proved to be useful after traumatic cataract extraction. With this thought IOL has been placed after extraction of the traumatic lens [19].

5.1 The Management of Traumatic Cataract has done with [15-19]

1. Phaco aspiration.
2. Small incision cataract surgery.
3. Extra capsular cataract extraction.
4. Surgical Management

Surgical management of traumatic cataracts is performed through either an anterior limbal approach or a posterior pars plana approach. The choice is often based on the degree of lens injury and the likelihood of vitreous loss.

The anterior surgical approach is useful in the following circumstances: non-dislocated cataract with intact capsule, capsular rupture with cataract, subluxated lens with or without cataract, and anterior lens dislocation with or without cataract. The posterior surgical approach is useful in posterior capsular rupture with cataract, subluxated lens with or without cataract, and posterior lens dislocation with or without cataract. [18,19]

6. CONCLUSION

In many children cataract accounts for visual morbidity following ocular trauma. The successful management of traumatic cataract depends on age, extent of cataract and damage to other ocular structures, type of injury and surgery undertaken.

Traumatic cataract is more common in younger individuals. Penetrating injuries are more commonly seen. Aphakic glasses and contact

lens are unsatisfactory for rehabilitation of aphakia because of various problems associated with their use. At present lens removal with a posterior chamber lens implantation is the ideal method of rehabilitation of patients with traumatic cataract. Timely operation and implantation of posterior chamber intraocular lens is a permanent method of optical correction which provides stable retinal images, induces minimal aniseikonia and thus help to maintain binocularity. In trauma visual outcome depends on the interval from injury to the surgery. Early intervention provides better visual outcome and less chance of developing amblyopia and strabismus. The whole development of vision as well as the personality of the child depends upon giving the best possible visual acuity to the young patients at the earliest possible. Unilateral cataract in children has a definite role in correcting aphakia, resulting in good visual outcome and thus helping to maintain binocularity.

CONSENT

It is not applicable.

ETHICAL APPROVAL

All authors hereby declare that all experiments have been examined and approved by the appropriate ethics committee and have therefore been performed in accordance with the ethical standards laid down in the 1964 Declaration of Helsinki.

COMPETING INTERESTS

Author has declared that no competing interests exist.

REFERENCES

1. Albert Jakobiec's: Principles and practices of ophthalmology. 3rd Edition. 2008;2: 1375-1377.
2. Albert Jakobiec's: Principles and practices of ophthalmology. 3rd Edition. 2008;2: 1380-1399.
3. Dinakaran S, Kayarkar VV. Traumatic retinal break from a viscoelastic cannula during cataract surgery. Arch Ophthalmol. 2004;122(6):936.
4. Sarikkola AU, Sen HN, Uusitalo RJ, Laatikainen L. Traumatic cataract and other adverse events with the implantable contact lens. J Cataract Refract Surg. 2005;31(3):511-24.
5. Shah MA, Shah SM, Shah SB, Patel CG, Patel UA. Morphology of traumatic cataract: Does it play a role in final visual outcome? BMJ Open. 2011;1(1):e000060.
6. Shah MA, Shah SM, Patel KD, Shah AH, Pandya JS. Maximizing the visual outcome in traumatic cataract cases: The value of a primary posterior capsulotomy and anterior vitrectomy. Indian J Ophthalmol. 2014; 62(11):1077-1081.
7. Trivedi RH, Wilson ME. Posterior capsule opacification in pediatric eyes with and without traumatic cataract. J Cataract Refract Surg. 2015;41(7):1461-4.
8. Chuang LH, Lai CC. Secondary intraocular lens implantation of traumatic cataract in open-globe injury. Can J Ophthalmol. 2005;40(4):454-9.
9. Phillips PM, Shamie N, Chen ES, Terry MA. Transscleral sulcus fixation of a small-diameter iris-diaphragm intraocular lens in combined penetrating keratoplasty and cataract extraction for correction of traumatic cataract, aniridia, and corneal scarring. J Cataract Refract Surg. 2008; 34(12):2170-3.
10. Kumar S, Panda A, Badhu BP, Das H. Safety of primary intraocular lens insertion in unilateral childhood traumatic cataract. JNMA J Nepal Med Assoc. 2008; 47(172):179-85.
11. Khurana AK. Comprehensive ophthalmology. Ocular injuries. 4th Edition, 2007;401-403.
12. Menapace R, Findl O, Georgopoulos M, et al. The capsular tension ring: Designs, applications, and techniques. J Cataract Refract Surg. 2000;26:898-912.
13. Rofagha S, Day S, Winn BJ, Ou JI, Bhisitkul RB, Chiu CS. Spontaneous resolution of a traumatic cataract caused by an intralenticular foreign body. J Cataract Refract Surg. 2008;34(6):1033-5.
14. Tabatabaei A, Hasanlou N, Kheirkhah A, Mansouri M, Faghihi H, Jafari H, et al. Accuracy of 3 imaging modalities for evaluation of the posterior lens capsule in traumatic cataract. J Cataract Refract Surg. 2014;40(7):1092-6.
15. Tabatabaei A, Kiarudi MY, Ghassemi F, Moghimi S, Mansouri M, Mirshahi A, et al. Evaluation of posterior lens capsule by 20-MHz ultrasound probe in traumatic cataract. Am J Ophthalmol. 2012;153(1): 51-4.

16. Ohar SRK, Savalia NK, Vasavada AR, Gupta PD. Epidemiology based etiological study of pediatric cataracts in western India. Indian J Med Sci. 2004;58:115–121.
17. Tassignon MJ, Gobin L, Mathysen D, Van Looveren J, De Groot V. Clinical outcomes of cataract surgery after bag-in-the-lens intraocular lens implantation following ISO standard 11979-7:2006. J Cataract Refract Surg. 2011;37:2120–2129.
18. Ram J, Gupta N, Sukhija JS, Chaudhary M, Verma N, Kumar S, Severia S. Outcome of cataract surgery with primary intraocular lens implantation in children. Br J Ophthalmol. 2011;95:1086–1090.
19. Verma N, Ram J, Sukhija J, Pandav SS, Gupta A. Outcome of in-the-bag implanted square-edge polymethyl methacrylate intraocular lenses with and without primary posterior capsulotomy in pediatric traumatic cataract. Indian J Ophthalmol. 2011;59:347–351.

© 2017 Pandey; This is an Open Access article distributed under the terms of the Creative Commons Attribution License (<http://creativecommons.org/licenses/by/4.0>), which permits unrestricted use, distribution, and reproduction in any medium, provided the original work is properly cited.

Peer-review history:
The peer review history for this paper can be accessed here:
<http://sciedomain.org/review-history/19627>