



# **Modified Groper's Appliance (BI-Functional Groper's) – Innovative Design for Management of Anterior and Posterior Teeth Loss**

**K. Sudheer Kumar<sup>a+++\*</sup>, B. V. Thimma Reddy<sup>a#</sup>,  
B. Uday Kumar Chowdary<sup>a†</sup>, R. Hemanth Kumar<sup>a‡</sup>,  
J. Raghavendr Akumar<sup>a‡</sup> and E. Lilly Grace<sup>a++</sup>**

<sup>a</sup> *Department of Pedodontics & Preventive Dentistry, SVS Institute of Dental Sciences,  
Mahabubnagar, Telangana, India.*

## **Authors' contributions**

*This work was carried out in collaboration among all authors. Authors KSK, BVTR and BUKC designed the study, wrote the protocol and wrote the first draft of the manuscript. Authors RHK and JRA managed the analyses of the study. Author ELG managed the literature searches. All authors read and approved the final manuscript.*

## **Article Information**

### **Open Peer Review History:**

This journal follows the Advanced Open Peer Review policy. Identity of the Reviewers, Editor(s) and additional Reviewers, peer review comments, different versions of the manuscript, comments of the editors, etc are available here:  
<https://www.sdiarticle5.com/review-history/98516>

**Case Report**

**Received: 01/02/2023**

**Accepted: 03/04/2023**

**Published: 04/04/2023**

## **ABSTRACT**

One of the dentist's greatest restorative challenges is the esthetic rehabilitation of a young toddler who has suffered multiple tooth loss subsequent to rampant early childhood caries (ECC) or extensive dental trauma. The condition has been characterized as first affecting the primary

<sup>++</sup> Senior Lecturer;

<sup>#</sup> Professor & Head;

<sup>†</sup> Professor;

<sup>‡</sup> Reader;

\*Corresponding author: Email: [kothasudheerkumar266@gmail.com](mailto:kothasudheerkumar266@gmail.com);

maxillary anterior teeth, followed by involvement of the primary molars. The extent of decay is almost always more severe in the maxillary incisors and frequently by the time the child is brought to the dentist, much of the anterior clinical crowns are lost. ECC is found especially in developing countries, which significantly affect the health and social development of the child. Such conditions require restorability or extraction of involved teeth based on clinical signs and symptoms. When extraction of primary incisors is necessary, many parents will seek an esthetic solution for the problem.

This case report discusses a case of esthetic rehabilitation in a 5-year-old female child over a follow-up period of 18 months.

**Keywords:** Early childhood caries; esthetics; space maintenance; Groper's appliance.

## 1. INTRODUCTION

The premature loss can have a detrimental effect on the psychological well-being of the child. During early childhood years, anterior teeth play a major role in the development of phonetics [1,2]. Thus, the replacement of these teeth is essential to restore all their functions [3]. Groper's appliance serves as an appropriate appliance for anterior teeth replacement. The Groper's appliance was first documented by Jasmin and Groper in 1984 [4]. The main objective of Groper's appliance was to help in space maintenance, esthetics appearance, and speech. It can be fabricated in different designs depending upon the patient's need.

### The factors associated with anterior tooth loss include:

- I. Tipping of adjacent teeth
- II. Over-eruption of antagonist teeth
- III. Midline deviation
- IV. Masticatory impairment
- V. Speech problems
- VI. Lingual dysfunction

### Factors necessary in planning for fixed anterior esthetic appliance:

- (i) Clinical Considerations and Parental Counseling

"When considering the need for an anterior appliance to replace missing primary incisors, the following points should be discussed with the parents. First, the strongest factor for placing an anterior esthetic appliance is parental desire as the child is in the stage of emotional and psychologic development. While space maintenance, masticatory function, speech development, and tongue habits may be of some other consideration" [3].

- (ii) Space Maintenance
- (iii) Masticatory Function

- (iv) Speech
- (v) esthetic appearance

## 2. CASE PRESENTATION

A 5-year-old girl reported to the Department of Paediatric and preventive dentistry with history of pain in upper front teeth and lower right back teeth region since 1 week. On clinical examination, child was diagnosed with multiple carious lesions with grossly decayed upper front teeth. Upon history taking it was confirmed as a case of severe early childhood caries affecting the female child (Fig.1).

Clinical and radiographic findings: (Fig. 2)

- I. Grossly decayed teeth (in relation to) irt 51,52,61,62,54
- II. Chronic irreversible pulpitis irt 84,85,74
- III. Chronic reversible pulpitis irt 64

### Treatment plan:

- I. Pulpectomy followed by post and core build up irt 52,62
- II. Pulpectomy followed by full coverage restorations irt 84,85,74
- III. Pulpotomy irt 64
- IV. Extraction followed by space maintainer irt 51,61,54

Initially the emergency access opening was done for relief of symptoms and was later planned for full mouth rehabilitation under local anesthesia after obtaining parent consent.

Pulpectomies were done irt 84,85,74 and full coverage restorations (stainless steel crowns) were given (Fig. 3). Pulpotomy was done irt 64 and permanent restoration was given (Fig. 4). Similarly pulpectomies were done irt 52,62 and post&core crown buildup was done (Fig. 5). Similarly extractions were done irt 51,61,64 and

planned for fixed anterior esthetic appliance as the parents were more concerned about their child aesthetics. Keeping the age of child in consideration space maintainer was also planned irt 54 and planned to incorporate it into the anterior space maintainer appliance (Fig. 6).

**Fabrication of Appliance:** For the fabrication of fixed appliance, banding was done on primary 2<sup>nd</sup> molars irt 55,65 using preformed bands (3M - ESPE). Once the banding was done, band transfer followed by impression making and cast pouring has been done. Casts were retrieved and design for wire component was marked involving edentulous area irt 51,61 and a canine hook was fabricated which engages buccally irt 53 maintaining the space irt 54. Fabrication of wire component followed by soldering and polishing of appliance was done. Once the polishing was done acrylic teeth were taken and shaped according to the patient morphological characteristics and bonded to the wire component using cold cure acrylic resin. The appliance was polished and checked intra orally for fit. Once the trial fit is done it was cemented using luting cement (Fig. 6). Patient was kept under constant supervision and every 3<sup>rd</sup> month regular visits for checking the integrity of appliance. After 18 months it was verified that the permanent teeth erupted into the oral cavity and the appliance was debonded followed by performing preventive therapy (Fig. 7).

### 3. DISCUSSION

“Children who are under five years of age, with anterior dental caries of teeth, are seldom

affected socially, because of limited exposure to peers unlike school aged children” [5]. “As they enter school, they may be comfortable, fitting into groups of children who actively exfoliate primary incisors. Speech problems are uncommon in children who are over four years of age and if they occur, they are usually compensated and reversible. Maintenance of space; prevention of over-eruption of antagonist teeth, restoration of function; allowance for maxillary growth; maintenance of hygiene; durability and low costs are the requirements of anterior esthetic fixed space maintainer” [1].

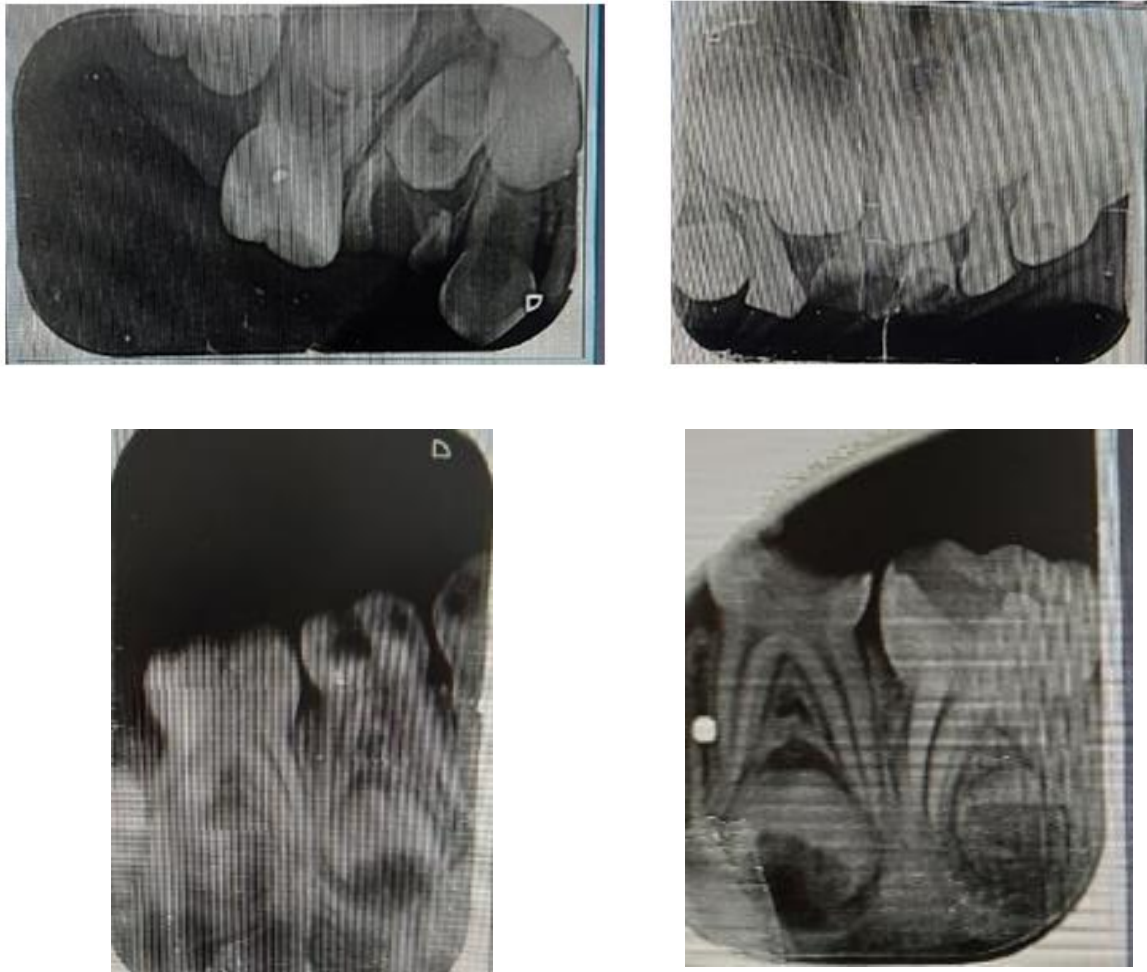
“A similar appliance was documented by Jasmine and Groper, in which, plastic teeth were attached to metal cleats that were soldered to the palatal wire bar instead of being attached to acrylic” [4].

“Unlike the posterior segment, the anterior segment from canine to canine appears to be stable, with no net loss of space between the canines. Moreover, intercanine growth between ages of two and four years is minimal (less than 0.5mm) and it is clinically insignificant. Changes in arch length with tooth migration generally occur after the eruption of the first permanent molar. At this time, the appliance can be removed, as it coincides with the eruption of the central incisors” [6].

Similarly, Shanmugaavel et al. created GRASCE appliance using the palatal wire to attach the teeth directly and they replaced molar bands by stainless steel crown [7].

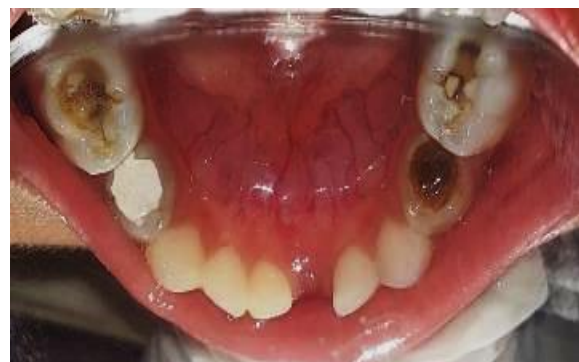
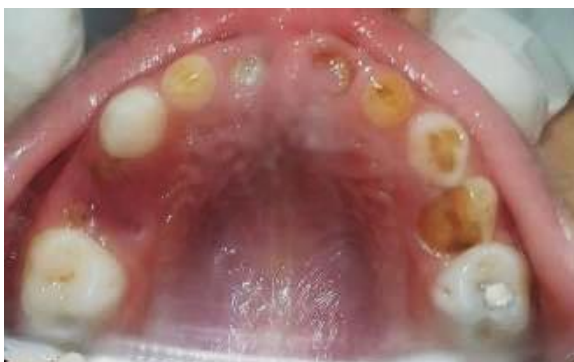
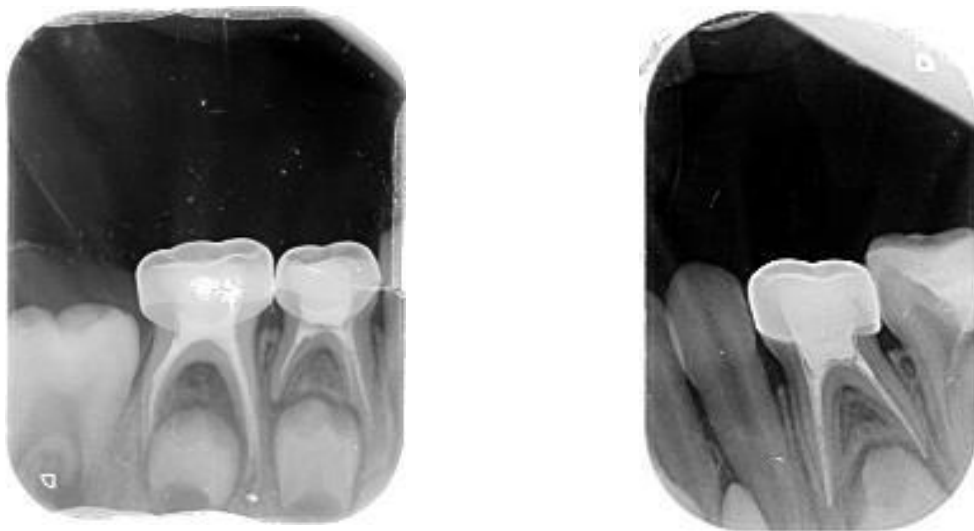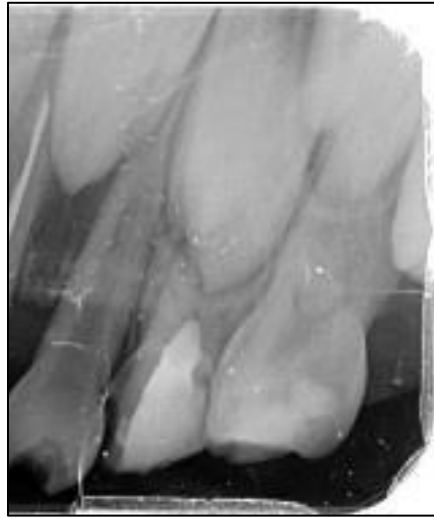
Fig. 1. Pre-operative clinical images



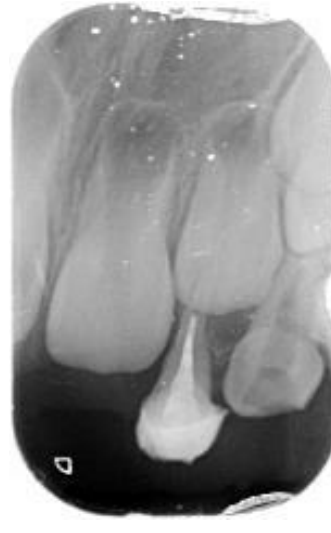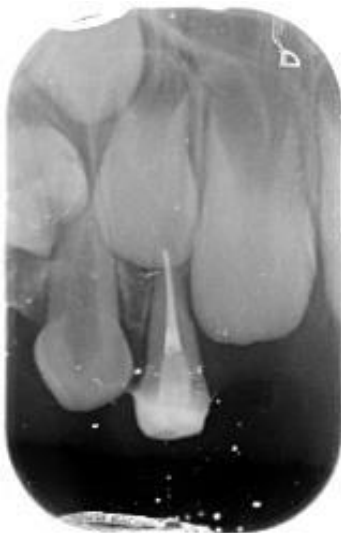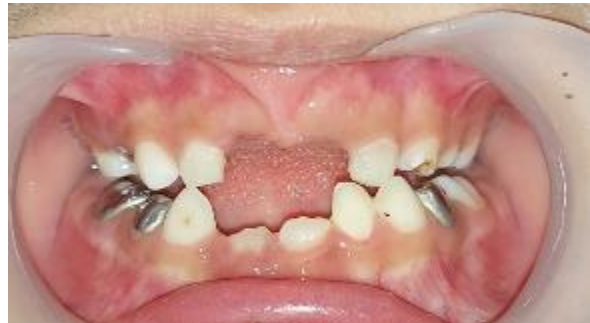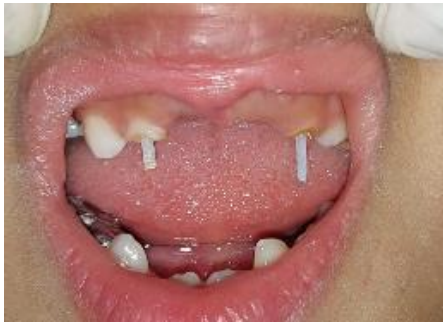**Fig. 2. Pre-operative radiographs**



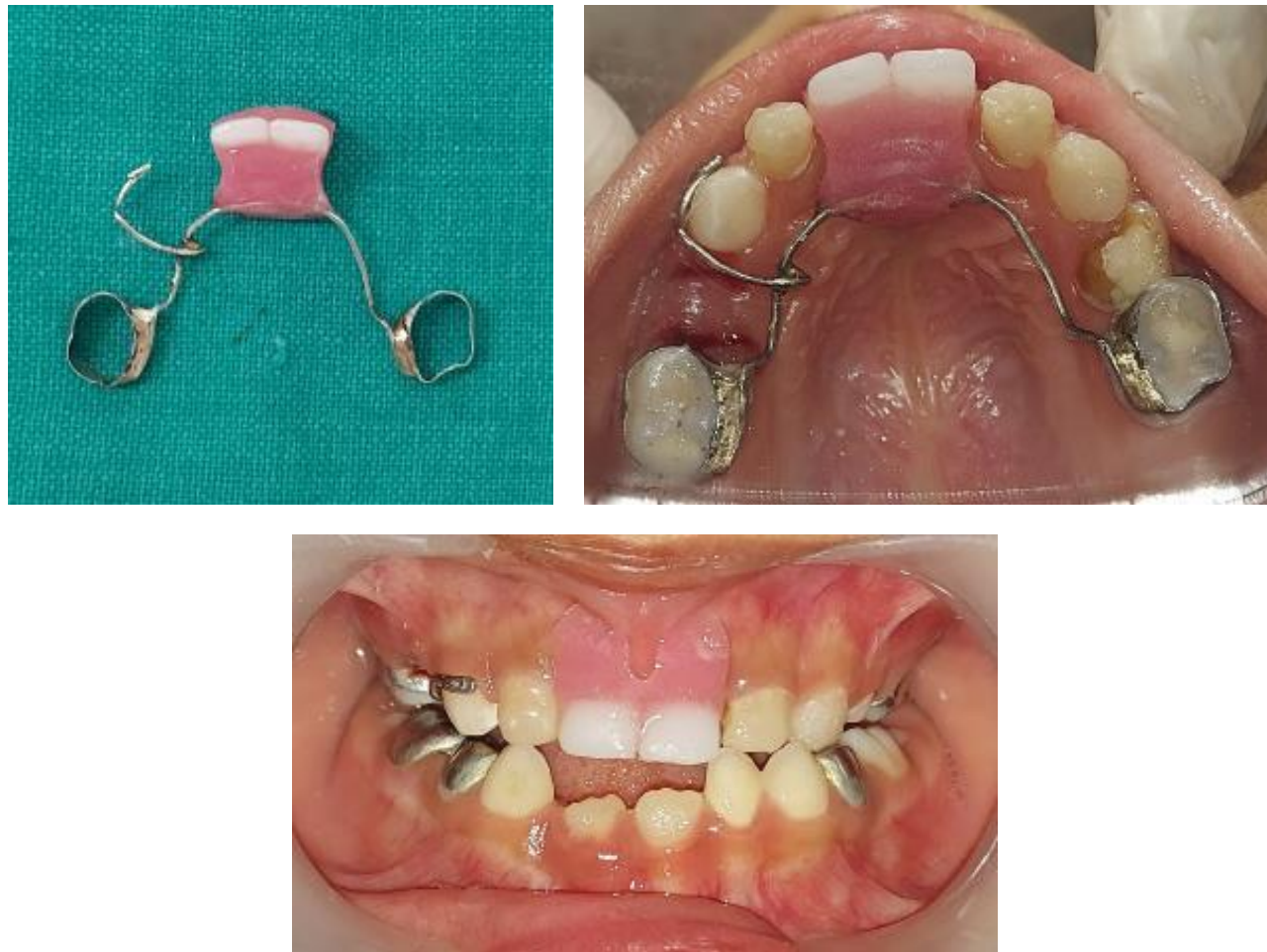**Fig. 3. Pulpectomy followed b y full coverage restorations IRT 74, 84, 85**



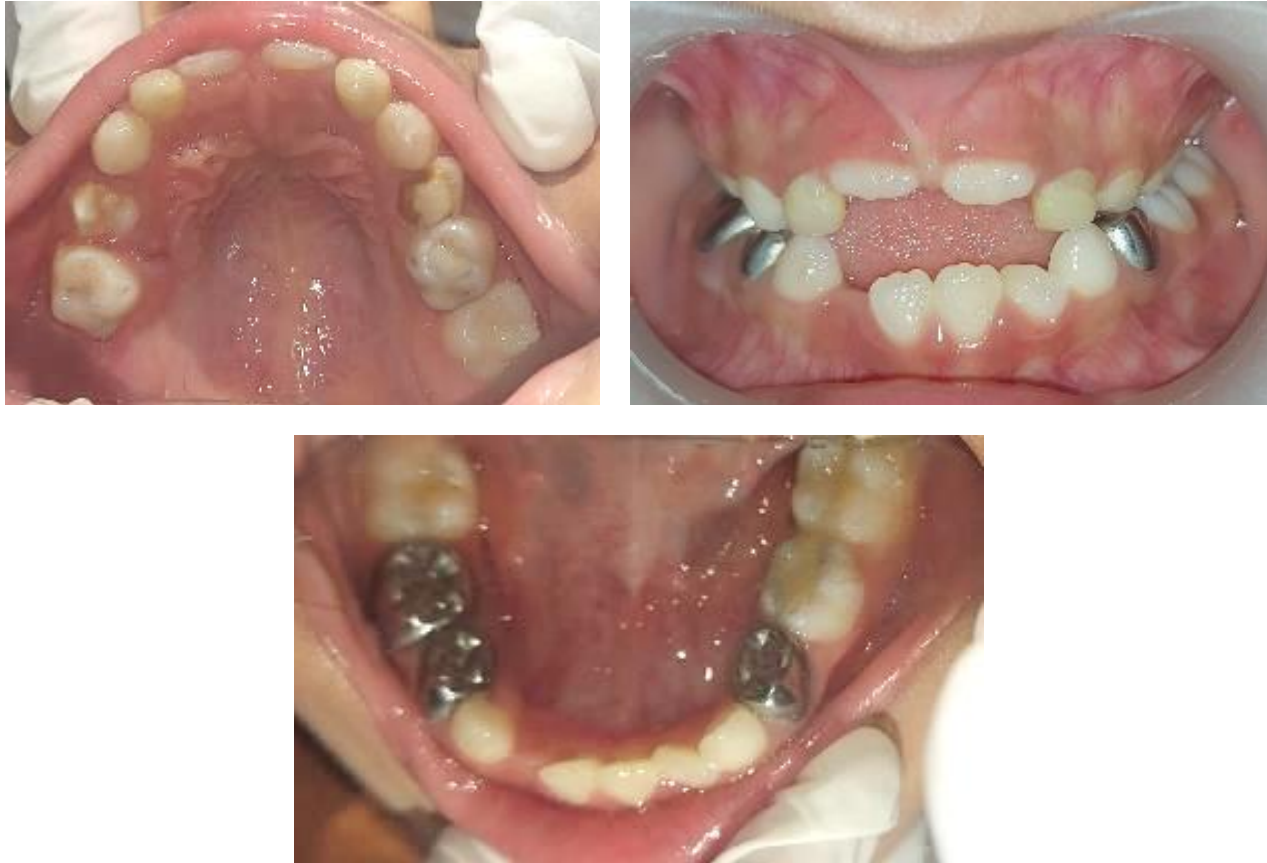**Fig. 4. Pulpotomy done IRT 64**



**Fig. 5. Pulpotomy followed by post & core build up IRT 52, 62**



**Fig. 6. Fabrication and insertion of modified groper's appliance with canine hook IRT 53**



**Fig. 7. Post operative after 18 months follow up**

The decision to replace anterior tooth comprises of several aspects such as child's age and parental desire. Parents should be informed about the importance of teeth and the impact of their absence. Jabin et al. concluded in their case report that "the restoration of anterior esthetics with this appliance gave an essential psychological boost to the child and his parents" [8]. Seth et al. [9] and Aniyo et al. [10] also concluded the same in their case reports. "After the eruption of primary canines, loss of primary incisors is not a prime consideration for space loss but other factors indicates their replacement" [11].

Riekman and Badraway reported in their study that the loss of deciduous anterior teeth before the age of 3 years results in speech problem [12]. "On the contrary Gable et al. did not report any long-term effect on speech due to early loss of maxillary incisors" [13].

The appliance which has been discussed here is of the fixed type and it bears none of the disadvantages of the removable type, such as need of the patient's cooperation and chances of breakage.

#### 4. CONCLUSION

The modified Groper's appliance is easy, simple, and considered as an elective appliance for restoring the anterior esthetics and maintaining the space serving the dual purpose in children. This appliance not only enhances the esthetics but also acts as functional space maintainer, develops proper speech and thereby boosting confidence in the child during their growing period of life.

#### CONSENT

All authors declare that 'written informed consent was obtained from the patient (or other approved parties) for publication of this case report and accompanying images.

#### ETHICAL APPROVAL

All authors hereby declare that all experiments have been examined and approved by the appropriate ethics committee and have therefore been performed in accordance with the ethical standards laid down in the 1964 Declaration of Helsinki.

#### ACKNOWLEDGEMENTS

Study was conducted at department of pedodontics and preventive dentistry, SVS

Institute of Dental Sciences, Mahbubnagar, Telangana, India.

#### COMPETING INTERESTS

Authors have declared that no competing interests exist.

#### REFERENCES

1. Borum MK, Andreasen JO. Sequelae of trauma to primary maxillary incisors. Complications in the primary dentition. *Endod Dent Traumatol.* 1998;14: 31-44.
2. Laing E, Ashley P, Naini FB, Gill DS. Space maintenance. *International Journal of Paediatric Dentistry.* 2009;19(3):155-62.
3. Wilson, CFG. Management of trauma to primary and developing teeth. *Dental Clinics of North America.* 1995;39: 133-167.
4. Jasmin JR, Groper JN. Fabrication of a more durable fixed anterior esthetic appliance. *J Dent Child.* 1984;51:124-7.
5. Kirzioglu Z, Erturk MS. Success of Reinforced Fiber Material Space Maintainers. *J Dent Child.* 2004;71: 158- 62.
6. Koroluk LD, Riekman GA. Parental perceptions of the effects of maxillary incisor extractions in children with nursing caries. *J Dent Child.* 1991;58: 233-36.
7. Shanmugaavel AK, Gurunathan D, Sundararajan L. Smile reconstruction for the preschoolers using GRASCE appliance – Two case reports. *J Clin Diagn Res.* 2016;10:ZD19-22.
8. Jabin Z, Dudeja P, Dudeja K. Management of bilateral dental agenesis with aesthetic rehabilitation by Groper's appliance – A six-year follow-up. *J Clin Diagn Res.* 2021;14:01-3.
9. Seth MP, Rani ST, Merum K, Raju S. Fix smile for a while: An esthetic rehabilitation with Groper's appliance – Two case reports. *Indian J Dent Adv.* 2018;10:119-21.
10. Aniyo R, Kaur G, Neha. Groper's appliance: Fixed appliance for an anteriorteeth. *Int Res J Med Sci.* 2019;1: 52-4.
11. Ngan P, Wei SH. Management of space in the primary and mixed dentitions. In: *Pediatric Dentistry: Total Patient Care.*



- Philadelphia, PA: Lea and Febiger. 1988; 462-70.
12. Riekman GA, el Badrawy HE. Effect of premature loss of primary maxillary incisors on speech. *Pediatr Dent.* 1985;7: 119-22.
13. Gable TO, Kummer AW, Lee L, Creaghead NA, Moore LJ. Premature loss of the maxillary primary incisors: Effect on speech production. *ASDC J Dent Child.* 1995;62:173-9.

---

© 2023 Kumar et al.; This is an Open Access article distributed under the terms of the Creative Commons Attribution License (<http://creativecommons.org/licenses/by/4.0>), which permits unrestricted use, distribution, and reproduction in any medium, provided the original work is properly cited.

*Peer-review history:*  
*The peer review history for this paper can be accessed here:*  
<https://www.sdiarticle5.com/review-history/98516>