

Spontaneous Rupture and Calcification of a Neglected Double J Ureteral Stent Revealed by Stenturia: A Case Report and Review of the Literature

Dibingue Tsikambu ^a, H. Hagguir ^{a*}, Alafifi Mahmoud ^a, A. Moataz ^a, M. Dakir ^a,
A. Debbagh ^a and R. Aboutaieb ^a

^a Department of Urology, Ibn Rochd Teaching Hospital, University of Hassan 2, Casablanca, Morocco.

Authors' contributions

This work was carried out in collaboration among all authors. All authors read and approved the final manuscript.

Article Information

Open Peer Review History:

This journal follows the Advanced Open Peer Review policy. Identity of the Reviewers, Editor(s) and additional Reviewers, peer review comments, different versions of the manuscript, comments of the editors, etc are available here: <https://www.sdiarticle5.com/review-history/71939>

Case Study

Received 17 February 2022

Accepted 23 April 2022

Published 18 June 2022

ABSTRACT

Double J or JJ ureteral catheters are used for various indications. If forgotten or neglected, they can undergo physical changes leading to degradation, calcification or encrustation. We are reporting a case of spontaneous rupture and calcification of a neglected double J ureteral stent revealed by stenturia and managed endoscopically.

Keywords: Double J stent; complication; rupture; endo-urology.

1. INTRODUCTION

Ureteral stents are widely used in endo-urological procedures. They can be overlooked or neglected leading to serious complications, including fragmentation or rupture, migration and urosepsis [1]. Few studies reported spontaneous fragmentation or rupture of double J catheters,

and stenturia is an unusual or unknown manifestation. Our objective is to present this rare case with an endo-urological management.

2. CLINICAL CASE

Its about a 31 year- old female with a history of endoscopic fragmentation of a right pyelic stone

*Corresponding author: Email: hagguirb002@gmail.com;

with placement of a protective double-J stent for which she neglected her appointment for removal of the. Seven months later, she began to present irritative lower urinary tract symptoms followed by the expulsion of whitish fragments in the urine before the consultation.

The clinical examination showed a conscious and stable patient with a slight right loin pain. The rest of the examination was normal. The complete blood count (CBC) and renal function test were normal. The cyto- bacteriological examination of urines showed leucocyturia without bacteriuria.

The plain x-ray without preparation of the urinary tree showed three fragments of double J catheter (upper loop, body and lower loop of the JJ) with calcification of one fragment at the vesical level (Fig 1).

The management of this condition was endoscopic. This consisted of laser fragmentation of the calcification at the bladder level and removal of the fragments under cystoureteroscopy (Fig 2).

3. DISCUSSION

Double J (JJ) ureteral catheters are widely used in the practice of modern urology. Ideal characteristics include biological inertness, chemical stability in urine, resistance to infection and encrustation, long-term urine flow, stability,

lack of discomfort and cost [2]. Double j stents are not free of complications. The incidence of forgotten stent and it's complications are related to the poor patient compliance, lack of proper counseling and the duration of the stent [3,4]. Stent-related complications are mainly mechanical: stent migration, encrustation, stone formation and fragmentation or rupture [5]. We are reporting a case of spontaneous rupture and calcification of a neglected double J ureteral stent revealed by stenturia.

Fragmentation or rupture is a serious complication of forgotten or neglected double J stents. It is caused by loss of tensile strength due to degeneration of the stent polymers and hardening of the stent [6]. In the series by El-Faqih et al, the fragmentation rate was 0.3% for a duration longer than 3 months [7]. The duration of the double J stent was 7 months in our patient.

Kumar et al defined stenturia as ureteral stent fragmented into several pieces that pass into the urine [8]. This symptomatology was observed late and was the main reason for consultation.

Stone formation in a remaining stent or fragment is a common complication. It is mainly seen in patients with an increased risk of stone formation and long-term indwelling catheters. Dehydration, urinary tract infection, stent obstruction, chemotherapy, pregnancy, metabolic and congenital abnormalities, chronic renal failure may also contribute to stone formation [5,9].

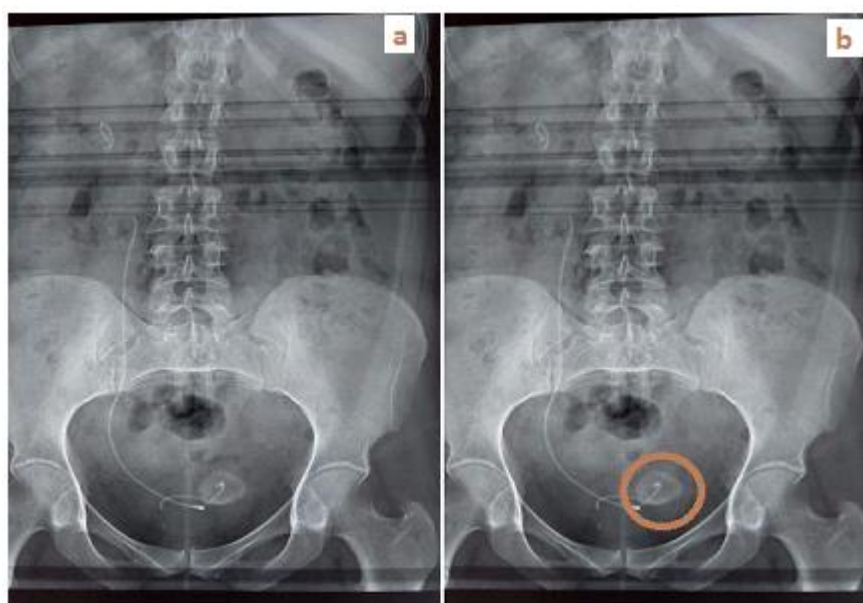


Fig. 1. Double J ureteral stent ruptured into several fragments with calcified distal loop




Fig. 2. Fragments of the double J stent after removal

In case of forgotten or neglected stents, management depends on the type of complication. Removal may be endoscopic or surgical. In some conditions, management may be multi-modal, combining endoscopy and surgery [10]. Nephrectomy may be indicated in case of a silent kidney [11]. Our approach was completely endoscopic, combining laser cystoureteroscopy with fragmentation and removal of the fragments.

4. CONCLUSION

The omission or negligence of ureteral catheters can lead to serious complications. Although the majority of these complications can be managed by endo-urolological procedures, prevention should be the only objective. In addition to patient compliance and the investment of the urologist, a reminder system can play an important role.

ETHICAL APPROVAL

As per international standard or university standard written ethical approval has been collected and preserved by the author(s).

CONSENT

As per international standard or university standard, patients' written consent has been collected and preserved by the author(s).

COMPETING INTERESTS

Authors have declared that no competing interests exist.

REFERENCES

- 1 Sen Volkan, Bozkurt Halil Ibrahim, Yonguc Tarik, Aydogdu Ozgu, Yarimoglu Serkan, Degirmenci Tansu et al. Forgotten and fragmented ureteral j stent with stone formation: combined endoscopic management. *Int. braz j urol.* 2015; 41(3):602-603.
- 2 Beiko DT, Knudsen BE, Watterson JD, Cadieux PA, Reid G, Denstedt JD. Urinary tract biomaterials. *J Urol.* 2004;171:2438-44.
- 3 Kawahara T, Ito H, Terao H, Yamagishi T, Ogawa T, Uemura H et al. Ureteral stent retrieval using the crochet hook technique in females. *PLoS ONE.* 2012 ;7:e29292.
- 4 Devraj R, Anantu N, Shaik JA, Vidyasagar S, Ramreddy Ch. Retained DJ stent: In terms of morbidity and management. *International Journal of Contemporary Medical Research.* 2016;3:2963-4.
- 5 Ray RP, Mahapatra RS, Mondal PP, Pal DK. Long-term complications of JJ stent and its management: A 5 years review. *Urol Ann.* 2015;7(1):41-5.
- 6 Zisman A, Siegel YI, Siegmann A, et al. Spontaneous ureteral stent fragmentation. *J Urol.* 1995;153:718-721.
- 7 El-Faqih SR, Shamsuddin AB, Chakrabarti A, Atassi R, Kardar AH, Osman MK, Hussain I: Polyurethane internal ureteral stents in the treatment of stone patients: Morbidity related in indwelling times. *J Urol.* 1991;146:1487.
- 8 Kumar M, Aron M, Agarwal AK, Gupta NP. Stenturia: An unusual manifestation of

- spontaneous ureteral stent fragmentation. Urol Int. 1999;62(2):114-6.
- 9 Mahmood SN, Toffeq HM, Hussen M, Karim A, Jamal C, Said AA, Aziz BO. Endourologic management of a 15-year-old neglected, fragmented, and encrusted ureteral stent, Journal of Endourology Case Reports. 2018;4(1): 201–204.
- 10 Murthy Kusuma VR, Reddy S. Jayaram, and al. Endourological Management of Forgotten Encrusted Ureteral Stents. Int. braz j urol. 2010;36(4):420-429.
- 11 Ahallal Y, Khallouk A, El Fassi MJ, Farih MH. Risk factor analysis and management of ureteral double-j stent complications. RevUrol. 2010;12:e147–51.

© 2022 Tsikambu et al.; This is an Open Access article distributed under the terms of the Creative Commons Attribution License (<http://creativecommons.org/licenses/by/4.0>), which permits unrestricted use, distribution, and reproduction in any medium, provided the original work is properly cited.

Peer-review history:

The peer review history for this paper can be accessed here:
<https://www.sdiarticle5.com/review-history/71939>