

## Scimitar Syndrome or Halasz Syndrome

Hanane El-Mouden <sup>a\*</sup>, Loubna Nashi <sup>a</sup>, Siham Salam <sup>a</sup>, Kamilia Chbani <sup>a</sup>,  
Dalal Laoudiyi <sup>a</sup> and Lahcen Ouzidane <sup>a</sup>

<sup>a</sup> Department of Radiology, Hôpital d'Enfants Abderrahim Harouchi, Casablanca, Morocco.

### Authors' contributions

This work was carried out in collaboration among all authors. All authors read and approved the final manuscript.

### Article Information

#### Open Peer Review History:

This journal follows the Advanced Open Peer Review policy. Identity of the Reviewers, Editor(s) and additional Reviewers, peer review comments, different versions of the manuscript, comments of the editors, etc are available here: <https://www.sdiarticle5.com/review-history/88205>

### Case Study

Received 08 April 2022

Accepted 16 June 2022

Published 23 June 2022

## ABSTRACT

Scimitar syndrome or Felson's vein-lobar syndrome is a very rare condition characterized by a combination of cardiopulmonary abnormalities including abnormal right pulmonary venous return, most often located in the inferior vena cava.

We *here report* an original observation of a nine-month-old female infant who presented with acute dyspnea in an endemic period. Symptomatic treatment for bronchiolitis was initiated, without success, with persistent respiratory distress. The diagnosis was suspected on chest X-ray and confirmed on CT scan which showed a single large right pulmonary vein draining into the right atrium associated with dextrocardia and pulmonary sequestration.

**Keywords:** Pulmonary arterial hypertension; scimitar syndrome; cardiopulmonary anomalies.

## 1. INTRODUCTION

“Scimitar syndrome or Halasz syndrome consists of a partial anomalous pulmonary venous drainage of right lung, right lung hypoplasia, dextraposition of heart, and anomalous systemic arterial supply from aorta or one of its branches to the right lung. This syndrome has varied

presentations, from an asymptomatic state” [1] “to severe pulmonary hypertension and/or heart failure” [2]. “Those who present early in life usually have associated congenital heart disease also” [3] Hemoptysis [4] and “pulmonary arterial hypertension (PAH) [5,6] both are uncommon presenting complaints of this rare syndrome beyond infancy”.

\*Corresponding author: E-mail: hanane8nrs@gmail.com;

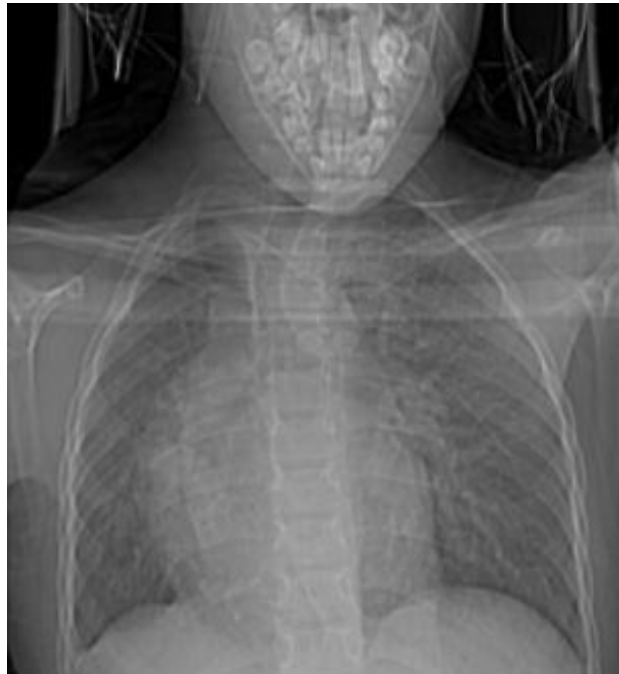## 2. CASE REPORT

A nine-month-old female child was hospitalized with acute wheezing dyspnea. Symptomatic treatment for bronchiolitis was initiated, but the evolution was marked by persistent respiratory distress. Chest radiography was performed and showed parenchymal distension and right postero-basal pulmonary opacity and cardiomegaly (Fig. 1).

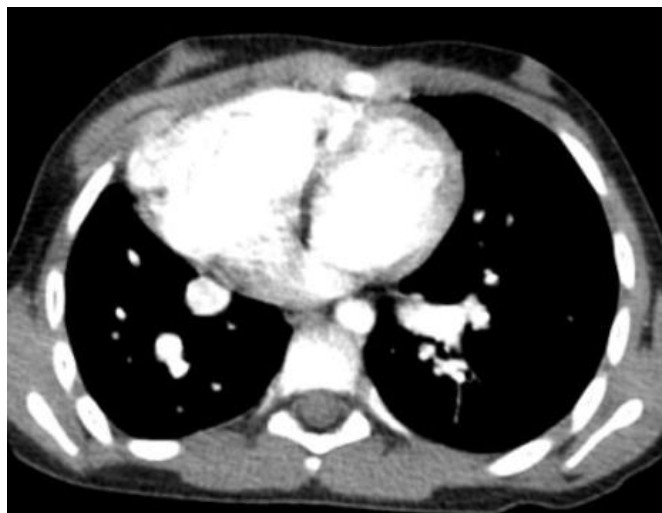The complementary thoracic angioscanner showed a single large right pulmonary vein draining into the right atrium (Fig. 5), associated with dextrocardia and cardiomegaly (Fig. 4).

Axial section, after injection of contrast medium showing a single right pulmonary vein that drains into the right atrium (Fig. 2).

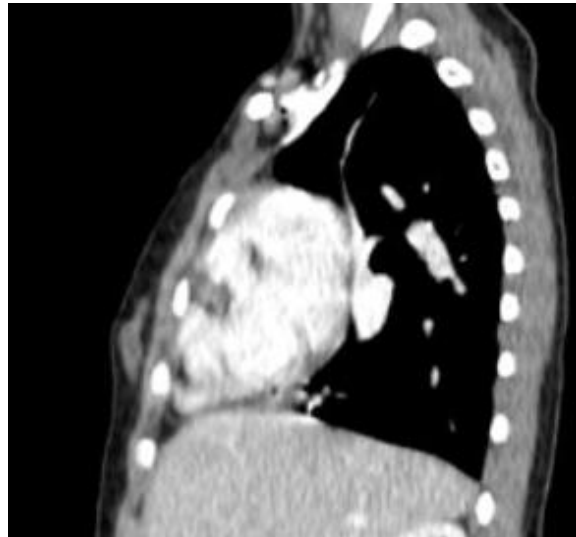
Sagittal reconstruction of the CT study (Fig. 3) showed typical scimitar-shaped structure.



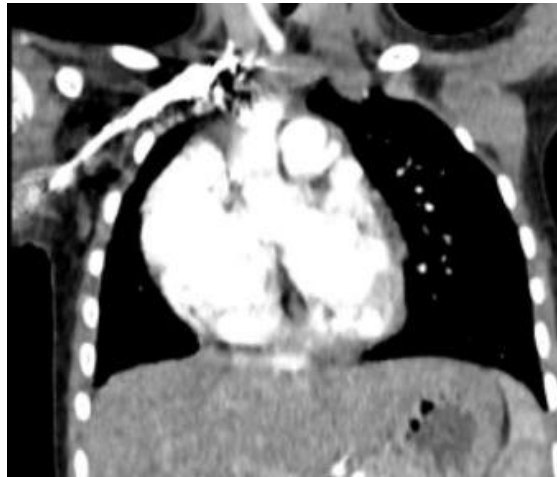**Fig. 1. Chest radiograph showing right postero-basal pulmonary opacity and cardiomegaly**



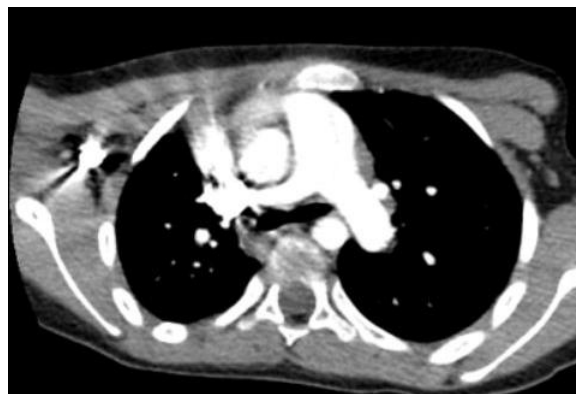**Fig. 2. Axial computed tomography section, after injection of contrast medium showing a single right pulmonary vein that drains into the right atrium**



**Fig. 3. Sagittal reconstruction CT section after injection of contrast medium, showing a single right pulmonary vein that drains into the right atrium. Note the saber or "scimitar" aspect of the right pulmonary vein**



**Fig. 4. Coronal CT reconstruction showing dextrocardia**



**Fig. 5. CT thorax showing dilated main pulmonary (asterisk) with normal looking left pulmonary artery, and hypoplastic right pulmonary artery**

### 3. DISCUSSION

Scimitar syndrome is a complex group of venopulmonary anomalies also known as Felson's venolobar syndrome or Halasz syndrome, which has been known for more than a century [7]. This syndrome corresponds above all to an abnormal right pulmonary venous return (RVPA) which is classically associated with other malformations such as: a cardiac dextro-position by rotation, a small right lung which is usually bilobar, a bronchopulmonary sequestration and/or cardiac malformations, notably an atrial septal defect (ASD) [8]. The name of this syndrome comes from the Turkish saber or "scimitar" appearance of the right RVPA on the frontal chest radiograph. This RVPA drains all or part of the venous return from the right lung into the suprahepatic inferior vena cava, into the right atrium just above the inferior vena cava junction, and sometimes into a suprahepatic vein.

The prevalence is estimated to be between 1/100,000 and 1/33,000 live births. The disease seems to affect mostly girls [9].

"The etiology is not completely understood. In several patients with totally abnormal pulmonary venous return, the gene locus has been located on chromosome 4q12" [9].

"In the majority of cases, it occurs during the first months of life. During the neonatal period, it presents with congestive heart failure usually due to pulmonary hypertension and respiratory failure; many of them need surgical intervention having a high mortality" [10,11].

"Disease in older children and adults commonly presents with recurrent pulmonary infections and/or exertional dyspnea. This group of the patients usually has a benign course" [6].

"Diagnosis of this syndrome is straightforward in presence of characteristic radiological sign (scimitar sign) on conventional chest radiography. However, when scimitar vein is masked by cardiac shadow, diagnosis can be documented by one or more traditional modalities", for example, angiography, [12] CT scan, [13] and echocardiography [14].

The reference examination for the morphological analysis of the lung parenchyma, the bronchial tree, the pulmonary and systemic vascular anatomy is nowadays the volumetric angio-CT; Currently available MR technology also provides

excellent visualization of vascular anatomy of this complex congenital defect non-invasively [15].

"The right lung is more frequently affected than the left, with hypoplasia and malformations of the pulmonary arteries of varying degree, and the presence of a supra- or subdiaphragmatic irrigation from the aorta. The heart is usually on the right side. In rare cases, the disease may present with a mild shunt, a heart murmur, and recurrent respiratory infections continuing into adulthood" [9]. "Approximately one quarter of affected patients have an associated congenital heart defect (coarctation of the aorta, tetralogy of Fallot, patent ductus arteriosus, or ventricular septal defect; see these terms). Other reported abnormalities include bronchogenic cysts, horseshoe lung, accessory diaphragm, and hernias" [9].

The association of a scimitar-type RVPA with sequestration is described in 50% of patients with this syndrome [16]. Most often, the pulmonary sequestration is Pryce's type I. The aberrant systemic artery most often arises from the lower part of the descending thoracic aorta or from the initial part of the abdominal aorta [17]. The search for sequestration is routine before undertaking any surgical treatment of RVPA.

Scimitar syndrome must be differentiated from pseudo-scimitar syndrome (presence of an abnormal vein descending to the left atrium) and Kartagene syndrome.

Treatment depends on the hemodynamic status. If the flow in the inferior vena cava is low, no treatment is necessary. If there is a significant left-to-right shunt and pulmonary hypertension, treatment is surgical: re-implantation of the pulmonary vein into the left atrium and surgery for other possible associated cardiovascular malformations, including surgery for pulmonary sequestration [16].

**Prognosis:** Mortality is high when the syndrome is diagnosed in childhood, due to severe respiratory failure, cardiac arrest and pulmonary infections.

### 4. CONCLUSION

The scimitar syndrome is an exceptional and unrecognized disease, whose clinical expression is insidious and non-specific. Chest X-ray often evokes the diagnosis which is confirmed by thoracic angioscan, pulmonary angiography or

MRI. No treatment is necessary in asymptomatic patients; however, surgical treatment may be proposed in cases of severe left-right shunt, sequestration or recurrent pulmonary infections.

## CONSENT

As per international standard or university standard, patients' written consent has been collected and preserved by the author(s).

## ETHICAL APPROVAL

It is not applicable.

## COMPETING INTERESTS

Authors have declared that they have no known competing financial interests or non-financial interests or personal relationships that could have appeared to influence the work reported in this paper.

## REFERENCES

1. Khan A, Ring NJ, Hughes PD. Scimitar syndrome (congenital pulmonary venolobar syndrome). *Postgrad Med J*. 2005;8:216.
2. Mordue BC. A case series of five infants with scimitar syndrome. *Adv Neonatal Care*. 2003;3:121–32.
3. Gikonyo DK, Tandon R, Lucas RV, Jr, Edwards JE. Scimitar syndrome in neonates: Report of four cases and review of the literature. *Pediatr Cardiol*. 1986;6:193–7.
4. Reddy R, Shah R, Thorpe JA, John G. Scimitar syndrome: A rare cause of hemoptysis. *Eur J Cardiothorac Surg*. 2002;22:821.
5. Najm HK, William WG, Coles JG, Rebeyka IM, Freedom RM. Scimitar syndrome: Twenty years' experience and results of repair. *J Thorac Cardiovasc Surg*. 1996;112:1161–8.
6. Canter CE, Martin TC, Spray TL, Weldon CS, Strauss AW. Scimitar syndrome in childhood. *Am J Cardiol*. 1986;58:652–54.
7. Nedelcu C, Khalil A, Gounant V, Korzeck J, Marsault C, Carette MF. Un syndrome du cimenterre de découverte fortuite. *J Radiol*. 2009;90(2):239–4.
8. Holt PD, Berdon WE, Marans Z, Griffiths S, Hsu D. Scimitar vein draining to the left atrium and a historical review of the scimitar syndrome. *Pediatr Radiol*. 2004;34(5):40913.
9. Ibtihale Benjouad, Ikram Taam, Khaoula El Ataouna, Mohamed Mahi, Touriya Amil, Rachida Saouab. Syndrome de cimenterre: à propos d'un cas et revue de la littérature. *Pan Afr Med J*. 2016;25:37.
10. Huddleston CB, Exil V, Canter CE, Mendeloff EN. Scimitar syndrome presenting in infancy. *Ann Thorac Surg*. 1999;67:154–9.
11. Saha K, Iyer KS. Intracardiac repair of obstructed right sided Scimitar syndrome. *Indian Heart J*. 1995;47:378–9.
12. Schramel FM, Westermann CJ, Knaepen PJ, van den Bosch JM. The scimitar syndrome: Clinical spectrum and surgical treatment. *Eur Respir J*. 1995;8:196–201.
13. Wang CC, Wu ET, Chen SJ, Lu F, Huang SC, Wang JK, et al. Scimitar syndrome: Incidence, treatment and prognosis. *Eur J Pediatr*. 2008;167:155–60.
14. Mordue BC. A case series of five infants with scimitar syndrome. *Adv Neonatal Care*. 2003;3:12132.
15. Manohar Lal Gupta, Rajeev Bagarhatta and Jyotsna Sinha Scimitar syndrome: A rare disease with unusual presentation 2009;26(1):26–29.
16. Dupuis C, Charaf LA, Breviere GM, Abou P, Remy-Jardin M, Helmius G. The 'adult' form of the scimitar syndrome. *Am J Cardiol*. 1992;70(4):502–7.
17. Ellis K. Fleischner lecture. Developmental abnormalities in the systemic blood supply to the lungs. *AJR Am J Roentgenol*. 1991;156(4):669–79.

© 2022 El-Mouden et al.; This is an Open Access article distributed under the terms of the Creative Commons Attribution License (<http://creativecommons.org/licenses/by/4.0>), which permits unrestricted use, distribution, and reproduction in any medium, provided the original work is properly cited.

Peer-review history:

The peer review history for this paper can be accessed here:  
<https://www.sdiarticle5.com/review-history/88205>